Z.A.Aliyeva, N.B.Shulpina, L.K.Moshetova

CURRENT ISSUES IN OPHTHALMOLOGY

The book has been prepared for publication and edited by

Academician Irada Huseynova, Vice-President of the Azerbaijan National Academy of Sciences (ANAS) and

Corresponding Member of ANAS Elmar Gasimov, Director of the National Ophthalmology Center named after Academician Zarifa Aliyeva, Ministry of Health of the Republic of Azerbaijan

Baku – "Elm" – 2025

The foreword is authored by
Academician Isa Habibbayli, President of ANAS

Aliyeva Z.A., Shulpina N.B., Moshetova L.K. Current Issues in Ophthalmology. Baku: Elm, 2025, 400 p.

ISBN 978-9952-570-30-4

DOI 10.59849/978-9952-570-30-4.2025.396

The book presents five sections related to current issues in ophthalmology: moral education of a doctor, issues of deontology, medical ethics and morality, modern aspects of eye biomicroscopy, fundamentals of ocular virology, damage to the organ of vision, propaedeutics of eye microsurgery. The authors, from the position of teachers of the higher medical school, in accordance with the guidelines of the unified program of postgraduate improvement and qualification requirements for ophthalmologists, highlight modern achievements in the theory and practice of the specialty, reflecting their personal scientific contribution. The publication is intended for practicing ophthalmologists and teachers of institutes and faculties of advanced medical training.

© ANAS, 2025



The Order of the President of the Republic of Azerbaijan
On marking the 100th anniversary
of the birth of Academician Zarifa Aliyeva

April 2023 will mark the 100th anniversary of the birth of Zarifa Aziz gizi Aliyeva, an outstanding Azerbaijani scientist, Honored Scientist, Doctor of Medical Sciences, Professor, Full Member of the Azerbaijan Academy of Sciences, will be celebrated.

Academician Zarifa Aliyeva led a meaningful life as a true intellectual with a rich spirituality and made significant contributions to the development of the medical field in our country with her comprehensive scientific activity. The authoritative works resulting from the scientist's long-term successful research on the topical issues of ophthalmology have always been duly appreciated and recognized. New and effective treatment methods and complex preventive measures proposed in these studies have been successfully and widely applied in a short period of time. The first research center of the school of ophthalmology in Azerbaijan, a specialized scientific research laboratory was established precisely on the initiative of Academician Zarifa Aliyeva. Zarifa Aliyeva, who always focused on medical ethics throughout her scientific and pedagogical activities, worked hard to train highly qualified personnel in the country and contributed to the emergence of a large generation of young scientists and ophthalmologists.

Guided by Item 32 of Article 109 of the Constitution of the Republic of Azerbaijan in order to ensure the celebration of the 100th anniversary of the birth of Zarifa Aliyeva, an outstanding ophthalmologist and scientist who made significant contributions to the development of medical science in our country, **I hereby order**:

1. The Ministry of Health of the Republic of Azerbaijan together with the Azerbaijan National Academy of Sciences shall prepare and implement a plan of events to celebrate the 100th anniversary of the birth of Academician Zarifa Aliyeva.

2. The Cabinet of Ministers of the Republic of Azerbaijan shall resolve issues arising from this Order.

Ilham Aliyev
President of the Republic of Azerbaijan
Baku, 3 November 2022

OPHTHALMOLOGY ON THE SCIENTIFIC MERIDIANS OF THE WORLD

FOREWORD

The monograph "Current Issues in Ophthalmology", translated into English for the first time, has been published in accordance with the Decision No. 21/2 of the Presidium of the Azerbaijan National Academy of Sciences dated November 22, 2022, regarding the implementation of the Order of the President of the Republic of Azerbaijan, Ilham Aliyev, dated November 3, 2022, "On marking the 100th anniversary of the birth of Academician Zarifa Aliyeva".

The presented book is a fundamental work on eye diseases, their diagnosis, and treatment. It covers a wide range of topics including the moral education of physicians, deontology, medical ethics and morality, the basics of ocular microscopy, modern aspects of ophthalmic virology, injuries of the visual organ of various origins, occupational ophthalmology, and issues of ocular microsurgery.

Still relevant today and widely used by specialists, especially young ophthalmologists, this book was first published in Russian in 1983, co-authored by prominent ophthalmologist scientists — Academician Zarifa Aziz Aliyeva, Professor Nina Borisovna Shulpina, and Academician Larisa Konstantinovna Moshetova. The idea behind the preparation of the monograph was to collect, summarize, analyze, and interpret the major achievements of ophthalmic science of that period, thereby meeting the need to enhance physicians' knowledge.

I find it appropriate to provide brief information about the authors of the monograph.

The scientific legacy of Academician Zarifa Aliyeva (1923-1985) — a prominent scientist and public figure, and the founder of the Azerbaijani school of ophthalmological science — is rich in significant contributions to the development of medical science in Azerbaijan. It was precisely due to Academician Zarifa Aliyeva's effective scientific and practical activities that Azerbaijan evolved from a republic providing only primary medical care in the field of eye diseases into one of the advanced scientific and medical centers.

The generalized theoretical principles and reflections on modern treatment methods in Zarifa Aliyeva's research were not based on pre-existing scientific models, but rather on conclusions drawn from practical experience and real-life observations. Her doctoral dissertation, successfully defended on the topic "The condition of the visual organ of

employees of a number of chemical enterprises of Azerbaijan", is highly regarded as the first comprehensive and systematic scientific work dedicated to this issue in the former Soviet Union.

Academician Zarifa Aliyeva's valuable scientific works dedicated to occupational diseases represent a theoretical and practical doctrine in ophthalmology, exemplifying true professionalism in the field. Her monographs, including "Occupational Pathology of the Eye in Tire Production", "Ophthalmology in Chronic Iodine Intoxication", and "Prevention of Occupational Eye Diseases in the Iodine Industry" are not only significant in Azerbaijan but also distinguished across the former USSR as scientifically novel and important works developed on the basis of the relationship between medicine and industrial production.

The world's first scientific book and monographic studies on iridodiagnostics were written by Academician Zarifa Aliyeva, under her leadership and with her direct involvement. Her works dedicated to hereditary factors in eye diseases, tear-related disorders, the physiology of the visual organ, and ocular complications of diabetes mellitus vividly demonstrate that Zarifa Aliyeva was not only a highly qualified physician in various fields of ophthalmology but also an outstanding scientist.

In recognition of her significant achievements in scientific and organizational activities, as well as in the training of specialists, and the social relevance of her research, Zarifa Aliyeva was elected a full member (academician) of the Azerbaijan Academy of Sciences in 1983 — an outcome that was a natural and well-deserved result of her 35 years of scientific work.

Zarifa Aliyeva was not only the devoted life partner, worthy comrade-in-arms, and closest friend of the world-renowned statesman and National Leader Heydar Aliyev, but she also gave our nation a powerful and visionary son — the President of the Republic of Azerbaijan, Ilham Aliyev. Her contemporaries especially highlight her simplicity, politeness, respect, and sincerity in her interactions with people as among her most noble human qualities, alongside her distinction as a prominent scientist and academician.

Academician Zarifa Aliyeva also went down in history as the only ophthalmologist from Azerbaijan to be awarded the Averbakh Prize of the USSR Academy of Medical Sciences for her significant scientific achievements in the field of occupational ophthalmology.

Zarifa Aliyeva left an indelible mark on global medical science as the author of nearly 200 scientific works in various fields of ophthalmology, including 14 monographs and 12 rationalization proposals.

The prominent Russian ophthalmologist and medical scientist,

Doctor of Medical Sciences, Professor Nina Borisovna Shulpina (1922-2020), was recognized as one of the first specialists in eye microsurgery in the USSR thanks to her extensive scientific knowledge and unique surgical techniques. Nina Shulpina authored more than 170 scientific works, including 6 monographs, and supervised 14 PhD dissertations.

The prominent Russian ophthalmologist, Honored Doctor, and Full Member of the Russian Academy of Sciences, Larisa Konstantinovna Moshetova (born 1938), earned recognition for her substantial research in ocular traumatology, pediatric ophthalmology, the organization of emergency ophthalmic care, vascular pathologies of the eye, and forensic ophthalmology.

From 1994 to 2019, Larisa Moshetova served as the Rector of the Russian Medical Academy of Continuous Professional Education and currently holds the position of President of the Academy. She is the author of over 330 scientific works, including 4 monographs and 2 tutorials. Under her supervision and scientific guidance, more than 50 PhD and 10 doctoral dissertations have been successfully defended.

One of the most valuable aspects is that the authors of the book "Current Issues in Ophthalmology", Professor Nina Shulpina and Academician Larisa Moshetova — who knew each other closely and collaborated scientifically — have always held Zarifa Aliyeva in great esteem as a distinguished scientist. Academician Larisa Moshetova continues to highly appreciate Zarifa Aliyeva's contributions to science as an innovative researcher and her human qualities to this day.

The preparation and scientific editing of the monograph for publication in English were carried out by the Vice-President of the Azerbaijan National Academy of Sciences, Academician Irada Huseynova, and the Director of the National Ophthalmology Center of Azerbaijan, Corresponding Member of ANAS Elmar Gasimov.

I believe that the first English edition of the monograph will be an important step toward promoting the rich scientific legacy of its renowned authors — who have already become leading figures in the field of ophthalmology — and will be met with great interest worldwide.

At the same time, the publication of "Current Issues in Ophthalmology" in English will serve as a valuable resource for students studying ophthalmology in this language, as well as for English-speaking young specialists and physician-researchers.

Isa Habibbayli
President of the Azerbaijan
National Academy of Sciences,
Academician

FROM THE AUTHOR

This book comprises five sections, which address issues in ophthalmology that remain relevant to this day: the moral education of physicians based on deontology, medical ethics and morality; recommendations for eye biomicroscopy; key aspects of the diagnosis and treatment of viral pathologies; ocular trauma; and the fundamentals of ophthalmic microsurgery propaedeutics.

Issues of deontology and moral education have always been fundamental in shaping the personality of a physician. The relevance of this matter has become even more pronounced in today's era of rapidly advancing scientific achievements and technologies. A physician's professionalism is measured not only by the speed and accuracy of diagnosis and the appropriate prescription of treatment but also by the ability to listen to the patient and a sincere desire to help. This core message is the focus of the first chapter of the book, reminding today's physician that only with such an approach to life and work can the desired and optimal results in patient care be achieved.

The second section provides a detailed description of the skills required for working with a slit lamp, the types and methods of illumination, with a particular emphasis on the clinical significance of biomicroscopy in cataracts. From the very beginning of their medical career, every ophthalmologist must master the skills of biomicroscopy, as it serves as the starting point for diagnosing almost any eye disease. Proficient use of these techniques enables the ophthalmologist to accurately determine the stage and nature of lesions in all parts of the visual organ, monitor the dynamics of the pathological process, and make informed predictions about the course of the disease.

The third section is devoted to aspects of differential diagnosis and treatment in ophthalmic virology. The challenge of identifying and properly treating viral pathologies remains highly relevant in modern medicine and represents a serious public health concern due to high incidence rates, which exceed those of other infectious diseases. To this day, epidemic outbreaks of adenoviral conjunctivitis, herpetic infections of the visual organ, and the continual emergence of new viral mutations with diverse forms of clinical damage to ocular tissues cause significant economic and social harm due to the high frequency of temporary disability among the population.

The fourth section presents extensive material in detail, describing the clinical features, diagnostic approaches, medical documentation procedures, and various aspects of organizing emergency care and con-

servative treatment for ocular trauma. Despite the high-tech nature of modern ophthalmic diagnostic and surgical equipment, the social importance of providing urgent care for various eye injuries, assessing the risk of potential post-traumatic complications, and implementing preventive measures remains highly relevant. It calls for the continuous improvement of practical skills among ophthalmologists working in both outpatient and inpatient settings.

An important section on occupational industrial ophthalmopathology, which represents the legacy of Academician Z.A.Aliyeva, presents the results of the author's many years of targeted scientific research. Experimental studies on the effects of various factors in chemical production on eye structures and visual functions formed the basis for describing the pathogenesis of occupational ophthalmopathology and for developing a system of preventive measures. This section was incorporated into the postgraduate education system as an instructional material and became a valuable resource not only for ophthalmologists but also for the sanitary and hygienic services of several chemical industry enterprises.

The final section is devoted to aspects of the propaedeutics of eye microsurgery. It includes a description of the morphological basis for microsurgical interventions on the hydrodynamic structures of the eye, an assessment of the role of biomicrogonioscopy in the selection, execution, and evaluation of pathogenetically targeted microsurgical methods for primary glaucoma, and an overview of the basics of microsurgical treatment of ocular trauma. These topics highlight the particular importance of this section even in the context of the current advanced level of ophthalmic surgery development.

This publication, which brings together the results of fundamental scientific research as well as the authors' practical and long-standing teaching experience, is intended to support the work of every practicing ophthalmologist. The issues addressed in this edition remain socially significant and relevant to this day. It is my hope that this work will contribute to the advancement of ophthalmologists' knowledge and the overall improvement of ophthalmic care services.

Larisa Konstantinovna Moshetova
President of the Russian Medical Academy of Continuous Professional Education, Doctor of Medical Sciences, Academician of the Russian Academy of Sciences

SECTION I

MORAL EDUCATION OF THE DOCTOR, ISSUES OF DEONTOLOGY, MEDICAL ETHICS AND MORALITY

They say that a doctor does not create wealth. This is true, but only partly. It creates the highest material and spiritual value of our society – the health of its worker, creator, fighter.

This, obviously, is the fundamental difference between a doctor and an activist of "bourgeois medicine". Of course, there are also enthusiastic ascetics and genuine humanists among them. However, they do not determine the moral character of a doctor in a society struck by acute class contradictions. Under those conditions, a man in a white coat looks at a man chained to a bed as a source of profit. There is nothing more shameful or more dishonorable than speculating on human pain—on physical and spiritual suffering.

Doctors categorically reject this shameful false morality. The duty and calling of workers of domestic medicine is "always serve people selflessly".

If you ask what moral foundation the doctor's active life position is based on, the answer is very simple: it is the attitude toward the patient!

Only that true doctor for whom the suffering of the patient is his own suffering; the smile of a man returning to work, towards life is the highest reward. Therefore, for such a doctor, every appointment, every conversation with a person affected by an illness is a moral responsibility both to the patient and to society. And most importantly, to own conscience.

Conscience is the main judge. In difficult times and in times of joy, when the doctor is face-to-face with him/her, he/she will ask: "Do you have the moral right to wear a white coat, so that after years and decades your hands convey to the sufferer not only knowledge, but a restless thought, a warm heart?" And this is happiness – to withstand the strict judgment of your own conscience.

"There is no more noble profession than that of a doctor: after all, the patient entrusts his health, and often his life to you, wrote the founder of healthcare N.A.Semashko. — All professions in our country are good. But the

profession of a doctor is closest to the people."

Ethical categories of duty, honor, conscience, dignity of a doctor filled with social, truly humanistic content. All the ideological and moral work of the public organizations, the health care system itself is aimed at the formation of its truly Human ethics.

According to the wise and figurative definition of I.A.Kassirsky, "a young doctor has to pass two main exams in life – a test of success and a test of failure. The first threatens self-delusion, the second – capitulation of the spirit. Conditions for perseverance in the face of these tests are the scale of the human personality of the doctor, the scope of moral ethical education." To what has been said, I would like to add that not only young doctors pass these exams. Life continuously tests the moral fortitude of those who are wise due to experience. It tests every day, every hour, and you must have high mental fortitude, deep and versatile knowledge, strong-willed character, you have to really love a person in order to pass these exams with honor.

The leading and decisive aspect of medical ethics is the relationship between a doctor and a patient. The patient's faith in the power of the doctor and in the effectiveness of treatment has been known for a long time. But we always remember that meeting with a sick person is a two-way process. While the doctor is examining the patient, his interlocutor in his own way, of course, studies the doctor. In a short period of communication with the patient, the doctor gets an idea about his disease. But the patient also develops an opinion about the doctor himself, sometimes unfavorable, based on the doctor's behavior, his conversation, and sometimes on individual little things that the doctor does not even notice. Then the invisible spiritual threads between the doctor and the patient weaken, and trust in the doctor fades away. It must be earned both for the effectiveness of treatment and for the moral balance of the person affected by the disease.

The correct, rational, skillful, tactful administration of drugs is also important, one might even say morally important. It is no secret that the arsenal of medicines is growing every year. Before you have time to fully understand the practical significance of one drug, you can read about another. There are currently more than a hundred antianginal drugs alone. Sometimes a patient asks to prescribe a drug

that the doctor has never even heard of. This is where a formula can appear, sometimes fair, but more often protective: "Be careful with new medications," the doctor advises paternally, covering up his ignorance of the new drug with words. Is it just ignorance? Maybe, if judging mental laziness by the laws of morality. In any case, it is unlikely that this streamlined formula will increase confidence in the man in the white coat. It is not only the professional but also the highest moral duty of a doctor to study, and to study throughout his life, to improve his qualifications, to follow the literature, and to skillfully use the acquired knowledge in practical activities.

There is another important medicine, the importance of which is difficult to overestimate. This is "soul medicine": an encouraging word addressed to the patient. I.P.Pavlov emphasized that the word is for a person the same real irritant as everything else, but at the same time it is as comprehensive as no other... The word, thanks to the entire previous life of an adult, is connected with all external and internal stimuli coming to the cerebral hemispheres. The word, claimed I.P.Pavlov, can cause all the body reactions that are caused by ordinary stimuli.

We all know from our own experience how greedily a patient seizes on the doctor's word. We also know that medical terms spoken to a patient or in front of a patient can give him a gloomy idea about the state of his health. A careless word spoken by a doctor can lead to illness. A medical worker's morality is obviously to examine the patient, determine the nature of the disease, and prescribe the necessary regimen and treatment. But all this should be done respectfully, tactfully, gently, cordially, so as not to injure the patient, think over and weigh every word. "It is not deception that helps an incurable patient but the art of finding how to tell the truth today, how to convincingly and encouragingly direct his thoughts and feelings for tomorrow".

In "Notes of a Doctor," which was sensational and very popular in its time, Veresayev wrote: "At first, I was so naive and youthfully straightforward that when insistently demanded, I told the patient the truth. Only gradually did I understand what it really means when a patient wants the truth, insisting that he is not afraid of death. This means: "If there is no hope, then lie to me so that I believe"".

Undoubtedly, the work of a doctor is complex, contradictory, and extremely responsible. The profession of a doctor is such that high-quality treatment is unthinkable without a responsible attitude towards one's always honest, always good deed. The main thing is not only the ability to quickly and accurately make a diagnosis, which in itself is necessary, but equally important is to listen to the patient, understand him with his heart, and help in every possible way. Only from this active medical position begins a tireless battle, sometimes taking away physical and spiritual strength, for the return of a person to life in the broadest sense of the word.

Isn't this the lofty humane meaning of the Hippocratic Oath, which doctors have taken from generation to generation? The more complex the physical disease, the thinner the walls of the patient's spiritual world. To support them, to strengthen this world like a fortress, one must spare no effort, no time, no movement of the soul, no fire of the heart.

The moral structure of the medical profession helps to objectively evaluate not so much the doctor's efforts as the results of his efforts. Fostering modesty and respect for a person is one of the criteria for medical ethics.

Another indicator is the doctor's appearance. The sad and unfriendly face of the doctor depresses the patient. He expects empathy but is met with boredom; expects friendliness, but feels rushed; waits for participation but is met with yawning. As a result, a blow is dealt to the psychological state of the patient.

An equally important part of moral education is the establishment of good-hearted relationships in the medical team. It's interesting how many beautiful words originate in the simple Russian word "good": conscientiousness, integrity, goodwill, good nature. For a doctor, these concepts are the norm of friendly relations in a team. But if they are not there, if they are shaken, then the patient suffers. Conceit, arrogance, disrespect for comrades, which, unfortunately, are still found in the behavior of some doctors, require increased moral education in medical teams.

In light of the above, the issue of so-called medical errors and the attitude of doctors towards them deserves special attention. "Life is short, the path of art is long, opportunities are fleeting, experience is deceptive, judgment is difficult, wrote Hippocrates, human needs

force us to decide and act. But if we are demanding of ourselves, then not only success but also error will become a source of knowledge".

It cannot, of course, be said that medical errors can be excluded fully. In each specific case, apparently, it is possible with known subjective and objective conditions to avoid them. But it is unlikely that we will find a doctor who could, with a clear conscience, say that during his medical life, he did not make a single medical error. The doctor, of course, must avoid mistakes. But, having admitted it, he should not hide from them. Only the weak in spirit and the ambitious are afraid to openly admit a mistake. To admit it means to find the strength to correct it quickly, decisively, not to the detriment but to the benefit of the suffering person.

The most terrible evil that a person wearing a doctor's coat can possess is indifference, which Leo Tolstoy called spiritual meanness. For us, doctors, the fight against indifference has a double meaning. We are talking about an intolerant, aggravated attitude towards the indifference of a doctor, to whom a person trusts the highest value – life. This is the first thing. And secondly, the eradication of the indifference of the citizen doctor to negative, immoral phenomena. The fight against social indifference is ultimately a fight for the physical and moral health of people.

The labor collective of doctors is the main educator of the high ideological and moral-volitional qualities of a doctor. The team teaches him to work with full strength, teaches him to tirelessly replenish his baggage of ideological and professional knowledge, teaches him not to spare his own health in the name of the health of a person who has lost it. In a word, it teaches high moral aspiration, socialist collectivism. That is why it predetermines the moral potential of the healthcare team, its moral and psychological atmosphere.

With pride in the army of thousands of healthcare workers, we talk about thousands and thousands of medical teams educating true exponents of morality. And with heartache, we have to say that there are still doctors who, with their immoral actions, disgrace an honorable and authoritative profession.

The tasks of moral education require strengthening the fight against the slightest manifestations of negative phenomena and completely eliminating them from the lives of healthcare workers. We, teachers of higher medical schools,

must consider this struggle as an important part of all ideological work and moral education of medical workers.

The moral character of a doctor is a highly professional and spiritual culture, it is moral aspiration, selflessness and honesty, it is the selfless work of an ascetic. Successor and follower of the highly humane traditions of remarkable Russian doctors and scientists who left an indelible mark on the history of world and national medicine, the doctor wholeheartedly believes in his oath of Hippocrates. And, naturally, it became the supreme law of work and life of every doctor. The government approved the new text of the medical promise. Always with spiritual trepidation you mentally repeat the words of the oath, which is the creed of modest labor of doctors, including ophthalmologists.

"Receiving the high title of doctor and starting medical practice, I solemnly swear:

— to devote all knowledge and effort to the protection and improvement of human health, treatment and prevention of diseases, to work conscientiously where the interests of society require it;

— be always ready to provide medical assistance, treat the patient kindly and with care, maintain medical confidentiality;

— constantly improve your medical knowledge and medical skills, contribute through your work to the development of medical science and practice;

— seek advice from professional colleagues if the patient's interests require it, and never refuse them advice and help.

I swear to uphold this oath faithfully throughout my entire life".

Upon this noble foundation of moral upbringing for medical workers grows and gains strength the radiant edifice of healthcare.

SECTION II

MODERN ASPECTS OF BIOMICROSCOPY OF THE EYE

In recent years, a large number of new research methods have appeared in ophthalmology, which was the result of scientific and technological progress and the creation of special diagnostic equipment. Now, even under the conditions of practical ophthalmological institutions, in particular, in the Moscow Ophthalmological Clinical Hospital, where the Department of Ophthalmology of the Central Order of Lenin Institute for Advanced Medical Studies carries out the pedagogical process, techniques such as ultrasound echography, electroretinography, fluorescence are used in everyday practice. Vascular angiography, the study of the critical frequency of flicker fusion, quantitative perimetry, radioisotope diagnostics provide the necessary information for a number of diseases. The attending physician does not directly carry out the research himself; he receives ready-made opinions from those ophthalmologists who work in the above profiles, in specially designated diagnostic rooms.

As for the method of biomicroscopic examination, it is currently available to every ophthalmologist, regardless of where he works (clinic, hospital) and what position he occupies (resident, head of department, consultant). This is due to the fact that biomicroscopy of the eye, in contrast to new subtle special techniques, with the help of which some narrow diagnostic issues can be solved at the highest level, is a method "for everything", for all occasions of life, i.e., it is a method of wide diagnostic capabilities. It provides (naturally, taking into account additional information) early diagnosis, differential diagnosis of most diseases, and helps in choosing the right treatment, in particular surgical treatment.

Based on some biomicroscopic symptoms, a prognosis of the disease is made. Now almost all clinical ophthalmology is being transferred to the diagnostic biomicroscopic level. This is facilitated by the fact that the domestic industry produces the necessary equipment (slit lamps), which is supplied not only to clinical institutions but also to the eye treatment rooms of ordi-

nary clinics and medical units of the enterprise.

In this monograph, we decided, first of all, to dwell on issues related to the equipment and methodological techniques for biomicroscopic examination of the eye. This will help the novice ophthalmologist master the method of biomicroscopy, also using as a guide the technical description and operating instructions for slit lamps produced by the Zagorsk Order of the Red Banner of Labor Optical-Mechanical Plant, which contains drawings and diagrams of the devices.

At the request of doctors, we included a biomicroscopic description of cataracts in the monograph, since in practical work we very often encounter this disease. Bearing in mind the preventive direction of medicine and the importance of identifying premorbid conditions, it was decided to concentrate attention on the description of the symptoms preceding senile cataracts. A complicated course of the cataract process is described, with characteristics of phacomorphic and phacolytic glaucoma. These issues are not covered at all in the educational literature on ophthalmology, despite the fact that these urgent conditions occur quite often and, if emergency measures are not taken, end in irreversible blindness up to the loss of the eye as an organ.

Taking into account the needs of practical healthcare, it became necessary to publish materials on diabetic cataracts and cataracts in diabetes mellitus for the reason that in the practice of an ophthalmologist, this form of lens pathology in recent years, due to the increase in diabetes mellitus, has become much more common, depriving patients of their ability to work.

The monograph includes a description of biomicroscopy of the posterior segment of the eye, since many ophthalmologists are poorly familiar with this issue, and yet knowledge at the biomicroscopic level of the main pathology of the vitreous body, retina, optic nerve and choriondea is just as necessary as knowledge of diseases of the anterior segment of the eye and its adnexa apparatus.

Chapter 1

EQUIPMENT. WORKING SKILLS. TYPES OF LIGHTING

The biomicroscopic research method is a further development and improvement of the lateral focal illumination technique, which is

widely used in ophthalmology at present.

In 1899, the binocular microscope was introduced into ophthalmic practice, making it possible to examine the anterior part of the eye. However, the lateral focal light obtained using a magnifying glass did not provide the desired brightness and contrast of illumination, as a result of which the membranes of the eye were not clearly visible even with magnification under a microscope.

The culmination of the development of the lateral focal illumination method was the creation of a device designed to illuminate the eyeball, in 1911. The main part of the device was a diaphragm in the form of a narrow slit, as a result of which it received the name slit lamp.

To illuminate the eye, it was not the light source itself that was used, but its actual inverse image, projected in the region of the slit-like diaphragm. In this way, a narrow, sharply delimited and homogeneous beam of light was obtained. This made it possible to create a pronounced contrast between the illuminated (studied) and unlit (adjacent) areas of the eye.

The phenomenon of light contrast (Tyndall phenomenon) was obtained, which contributed to the further development of the biomicroscopy method. A similar phenomenon can be observed when a ray of sunlight penetrates through a narrow slit in a shutter into a dark room. In this case, dust particles moving in the air usually become visible, which is not observed under diffuse daylight or artificial lighting. With biomicroscopy, the pronounced contrast of illumination allows one to see many details of the structure of the eyeball, which are almost imperceptible when using conventional lateral focal illumination.

The strong illumination and small size of the light beam made it possible to place its focus on different parts of the eye, located at different depths. Thanks to this, it became possible to conduct a detailed examination of not only the external but also the deeper tissue structures of the eye. Due to the use of a slit lamp, patients got rid of the glare of light, since a very narrow and short light beam was cut out using a slit diaphragm.

Following the first device, many models of slit lamps were proposed, but most of them suffered from a number of significant disadvantages and remained in ophthalmic practice for a relatively short time.

Modern models of domestic slit lamps are a combination of a very strong light source, producing a light beam of a certain shape, and a binocular stereoscopic microscope of significant magnification. The presence of a binocular microscope expands the capabilities of the biomicroscopic research method since the image of eye tissue becomes enlarged and voluminous.

The most popular among ophthalmologists are domestic slit lamps SL-56 and SLT.

Slit lamp SL-56

The slit lamp SL-56 is convenient and not difficult to use. The device consists of an illuminator, or the slit lamp itself, a binocular microscope, a face unit, coordinate and instrumental tables.

The slit lamp SL-56 is a vertical-type lamp since the illuminator in it is located vertically. The illuminator and microscope are mounted together on a common coordinate stage, which ensures their joint movement in different directions during operation.

The most important and basic part of the device is the illuminator. The light source is an STs-69 electric light bulb (6 V, 25 W), powered from a 127 or 220 V electrical network through a step-down transformer.

The lamp base is soldered into a special centering clip, located in the socket and positioned in such a way that the lamp filament is located along the vertical lighting slit. This ensures the greatest illumination of the vertical image of the slit.

The cartridge in the illuminator body is secured with a special clamping bolt. Somewhat above the lamp, there is a condenser in a frame, consisting of two magnifying glasses that ensure the concentration of the light beam produced by the lamp. Above the condenser is a slot mechanism.

The SL-56 model makes it possible to obtain not only a vertical but also a horizontal slit, which is of great importance when conducting some special studies, in particular microgonioscopy of the lateral sections of the anterior chamber angle. The design of the diaphragm giving the slit makes it possible to obtain a variety of lengths and widths of the slit – from 0.04 to 8 mm. The size of the gap is adjusted by handles, one of them changes the width of the gap in the vertical direction, and the other in the horizontal direction. Above each of the handles, there is a scale on which the width of the slit image can be measured.

In the illuminator body, above the slot mechanism, there is a disk

with four holes. One of them is left free, light filters (neutral and blue-green) are mounted in two holes, and frosted glass is placed in the fourth. Thus, on the path of the rays coming from the illuminator, different light filters can be installed in turn, which give the image of the slit, depending on the need, different illumination intensity and color.

Only a small part of this disk is visible on the outer surface of the illuminator. All its other sections are hidden in the illuminator housing, which protects the filter from mechanical damage and dust. The disc, which can be turned by hand, can be locked in four positions with a special lock. The light rays, after passing through the slit mechanism and the disk, are directed towards the lens and head prism located in the upper part of the illuminator body. The prism reflects the incident rays and imparts a horizontal direction in nm.

The head prism has the ability to deviate by 10° to each side, which provides an additional opportunity to change the angle of biomicroscopy. A horizontal beam of light bursts from the illuminator and moves toward the eye.

A special cylindrical lens in a frame can be placed on the body of the head prism of the illuminator. It helps increase the length of the vertical slit up to 16 mm, which expands the possibilities of biomicroscopic examination.

A removable gonioscopic attachment can also be placed on the body of the head prism, which on the eyeball produces an illuminated circle with a diameter of up to 20 mm, which can be used during gonioscopy in diffuse light.

The binocular microscope of the SL-56 device consists of a lens and a pair of sliding eyepieces. The distances between the eyepieces vary from 52 to 74 mm. In the microscope body, there is a special optical device, the so-called drum, the main part of which is two pairs of telescopic tubes. Changing the image magnification is carried out by rotating the flywheels located on the sides of the illuminator body. This causes the drum to rotate and the telescopic tubes to change.

Each pair of telescopic tubes provides two magnifications depending on which part of it faces the lens. The drum has a pair of free holes, which can also be put into a working position.

This design of a binocular microscope allows us to obtain 5 magnification options (5X, 9X, 18X, 35X, 60X) without taking the observer's eyes away from the eye-

pieces. The degree of image magnification at each moment of the study is recognized by the number on the handwheel, which is set when it rotates against the fixation point marked on the microscope body on the right side. A great convenience for a researcher when working with an SL-56 microscope is the ability to correct, if necessary, one's own anisometry. This is achieved by extending the eyepieces from the microscope tubes to a certain distance.

Below the handwheel, the rotation of which changes the magnification of the microscope, there is a screw that ensures a clear image of the biomicroscopic picture. The ability to move this screw horizontally is estimated at 35 mm.

A diverging ophthalmoscopic lens with a power of about 60.0 diopters is mounted on the body of the binocular microscope. It neutralizes the effect of the optical system of the eye, which is necessary for studying the posterior parts of the vitreous body and fundus.

The mutual rotation of the illuminator and the binocular microscope (biomicroscopy angle), calculated at ± 60°, is measured on a circular scale. The scale rotates with the illuminator. There are also two screws, the rotation of which secures the biomicroscopy angle.

At zero angle of biomicroscopy, the illuminator is fixed in front of the microscope in the middle position with a special fixing device, after which both the illuminator and the binocular microscope rotate together around the tripod column. The researcher performs this movement by hand.

The illuminator and microscope are mounted on a coordinate stage, consisting of a fixed base and an upper movable part, called the upper plateau. This plateau is moved in all directions by a special handle. The movement of the plateau, and with it the illuminator and microscope, in the anterior-posterior direction is 40 mm, and in the lateral directions - 105 mm.

The facial support is designed to fix the patient's head and is a combination of a chin rest and forehead rest, which are equipped with hygienic tear-off paper napkins. The chin part of the unit is movable in the vertical direction over a wide range (90 mm), which provides good head support for both adults and children.

The unit has a special device on each side to fix the patient's gaze in the desired direction. It is a cap with a pinhole illuminated from the inside by an electric light bulb (6.3 V, 0.28 A), powered by alternating current through a step-

down transformer. A red-light filter is inserted in the path of the light, which ensures bright red coloring of the luminous fixation points.

The tool table included in the SL-56 kit is very convenient to use since it is small in size and has a screw device that allows it to move vertically. A step-down transformer is attached to the instrument table on the bottom side; some electrical installation elements of the device and a switch are also located there.

Adjusting the SL-56 lamp illuminator is easy, since the filament, due to the presence of a special centering holder in which the light bulb is mounted, is already centered relative to the image of the slit.

Adjusting the illuminator of the SL-56 lamp, if it is being done for the first time, must begin by setting the transformer to the desired voltage. The transformer, mounted under the board of the tool table, is designed for connection to an alternating current network with a voltage of 127 or 220 V. The transformer terminals are installed for connection to a 220 V electrical network. With a network voltage of 127 V, it is necessary to unscrew the contact screw from the 220 V socket and screw it into the 127 V socket. This work can be entrusted to an electrician.

Having connected the device to the lighting network, they begin to adjust the illuminator itself, which is absolutely necessary not only in the process of installing a newly received slit lamp but also when changing a burnt-out light bulb, if the lighting slit is unsatisfactory. A socket with a burning electric light bulb is inserted into a round hole in the illuminator housing. To ensure free insertion and movement of the lamp socket, it is necessary to loosen the clamping nut by turning it to the left. Then the diaphragm of the vertical and horizontal slits is completely opened, for which the corresponding handles are brought to their extreme positions, placing them opposite the number 8 indicated on the scale. A free hole of the diaphragm is placed in the path of the rays.

The socket with the lamp is carefully moved upward until an image of a spiral appears on the outer surface of the head prism. It should be clear, vertical and central. The spiral is better visible if it is viewed against the background of a screen (ordinary white or better tissue paper) placed close to the prism. If the spiral is located obliquely, it must be aligned and

given a vertical position. This is done by rotating the light bulb socket around its vertical axis.

In practical work, sometimes one has to deal with the fact that it is not possible to obtain an image of a spiral in the middle of an illuminated slit. The spiral is stubbornly placed on the side, and only half or a third of it is visible in the gap. This is due to a defect in the factory alignment of the lamp filament in the centering holder. In such cases, you should center the lamp yourself, and along with it the spiral, by tightening or loosening the screws on the outer surface of the holder. After obtaining a high-quality and centrally located spiral, the lamp socket should be secured in the illuminator body with a clamping nut. The white screen must be moved to the place of the expected position of the patient's eye, after which, by moving the lever that determines the width of the slit, the narrowest slit can be obtained on the screen.

Skills for working with an SL-56 slit lamp.

Working with the SL-56 lamp begins with the patient's head being comfortably fixed in the facial position, the chin part should be in the middle position.

The base of the coordinate table must be moved close to the face unit. Even a small gap between them makes research difficult. It is also necessary to ensure that the coordinate table is located in the middle of the tool table.

After this, the movable part of the coordinate table is placed in the middle position by moving the handle, which is installed vertically. The illuminator is placed on the outside of the eye being examined at one or another biomicroscopy angle. The angle is selected by the doctor depending on which part of the eye is to be examined and what type of lighting is intended to be used.

It is necessary to ensure that the head of the illuminator (head prism), through which the light rays leave the illuminator, is in the middle position and located opposite the patient's eye.

By moving the upper plateau of the coordinate table, a clear image of the illumination slit is established in the area of the eye that is to be examined. After this, an image of the illuminated area is found under a microscope. By rotating the focal screw of the microscope, it is necessary to achieve maximum clarity of the biomicroscopic picture.

Sometimes, the image of the slit does not coincide with the field of view of the microscope, while the examiner sees through the microscope the unilluminated part of the eye. In this case, it is necessary to slightly rotate the head prism of the illuminator to the right or left, the light beam will fall into the field of view of the microscope, i.e. it will align with it.

By moving the upper part of the coordinate table (and with it the lighting slit) horizontally, you can examine all the tissues of the eye located in a given plane at a given depth. By moving the plateau in the anteroposterior direction, you can examine areas of the eye at different depths.

The exceptions are the posterior parts of the vitreous body and the fundus. To examine these parts of the eyeball, it is necessary to lower the ophthalmoscopic lens down by turning the lens handle clockwise. The illuminator must be placed in front of the lens of the binocular microscope (the biomicroscopy angle approaches 0). If these conditions are met, the image of the illuminated slit appears on the fundus.

Examination of the anterior segment of the eyeball with an SL-56 lamp and biomicroscopy of deeper tissues and the fundus of the eye are performed at different microscope magnifications. In everyday practical work, small and medium magnification levels are preferred, on the order of 9X, 18X, 35X. The examination should begin at a less significant magnification, moving to a more significant one as needed.

Slit lamp with tonometer — SLT

A slit lamp with a tonometer – SLT – is an improved version of the SL-56 slit lamp. In particular, the SLT has an additional table for biomicroscopy of children from 3 years of age, attached to the instrument table on hinges. During the operation, the table is tilted to a horizontal position, and a face unit with a children's forehead and a headband for fixing the child's head is attached to it. The dimensions of the rim can be increased or decreased.

The illuminator body has a disk with four holes into which light filters (neutral, blue-green, blue) are inserted. The fourth hole is left free. The blue filter included in the design is used when conducting tonometric studies.

The design of the microscope is complemented by a drum for measuring the depth of the anterior chamber and determining the degree of survival of pathological

formations in the range from 0 to 20 mm. The counting is carried out on a scale marked on the drum. A grid in a frame is inserted into the eyepiece of the microscope tube, with which you can make relative measurements of the formation in question. The eyepieces have a diopter adjustment in the range of +5.0 D to -5.0 D. An ophthalmoscopic attachment with an optical "plus" sign is attached to the microscope, with a diameter of the ophthalmoscopic area of 5-6 mm. To eliminate glare, the frame of the ophthalmoscopic lens can be rotated around a vertical axis to the right and left.

Since ophthalmoscopic examinations using a plus magnifying glass are carried out in reverse, during the examination, a wooden block is placed along its length between the coordinate table and the facial unit, which allows maintaining the necessary distance between the eye of the subject and the microscope lens.

In addition to the listed design improvements and additions, the SLT kit includes a cylindrical lens, with the help of which the vertical image size of the lighting slit can be increased to 15 mm. In the process of biomicroscopic examination, an applanation tonometer allows measuring true and tonometric intraocular pressure, determining the coefficient of rigidity of the membranes of the eyeball, which is important for the early diagnosis of glaucoma, assessment of its medical and surgical treatment.

The tonometer is an attachment to the slit lamp and is fixed with its base on the body of the binocular microscope, in the socket for attaching the ophthalmoscopic lens after its removal. The tonometer contains a roller weight connected by a system of levers to a tonometric platform (a replaceable optical wedge in contact with the cornea) and round scales with an arrow located on the right side of the attachment. Each optical wedge is made in the form of a prism device, which allows, during tonometry, observing the area of flattening (applanation) of the cornea through a microscope or slit lamp. The prism device consists of two glued prisms that deflect the image in different directions. Therefore, during tonometry through a microscope, not a whole circle of corneal flattening is visible, but two semicircles, offset relative to each other.

To determine the true intraocular pressure, wedge No. 1 is used, giving a corneal flattening diameter of 3.06 mm. With this diameter, the external pressure on the cornea (1 g) corresponds to an intraocular

pressure of 10 mm Hg. The value of true intraocular pressure is indicated on the black scale of the topometric attachment. To determine tonometric pressure, an optical wedge No. 2 is used, which produces a flattening circle with a diameter of 4.33 mm. To obtain such a circle, a certain amount of pressure of the wedge on the cornea is needed, which depends on the value of intraocular pressure. The topometric pressure number is indicated on the red scale of the attachment. The springless design of the device provides greater accuracy of tonometry. During operation, a load of 0-12 g can be used, which allows you to measure intraocular pressure from 0 to 120 mm Hg. This range makes tonometry possible both with severe hypotension and with severe hypertension.

Skills for working with the slit lamp SLT. After attaching the tonometric attachment to the body of the binocular microscope, the device must be aligned with the level located at the top of the tonometer. The surfaces of optical wedges No. 1 and No. 2 are wiped with a cotton swab soaked in alcohol, and then dried with a sterile gauze pad. During applanation tonometry, the patient should be in a sitting position. Good instillation anesthesia of both eyeballs is required.

The patient's head, as with conventional biomicroscopy, is fixed on a facial mount. The coordinate table of the device must be moved close to the face unit, the illuminator is located on the side of the eye under study at a small biomicroscopy angle when installing the binocular microscope against the eye under study at the zero-scale division. The slit aperture should be opened as much as possible, and a blue filter should be placed in the path of the light. A small amount of a 2% fluorescent solution is applied to the area of the upper limbus with a glass rod, after which the patient is asked to make several blinking movements to evenly distribute the dye across the cornea. You should be aware that excess fluorescence makes tonometry difficult. Under 5x or 9x microscope magnification, an image of the optical wedge is found. It is recommended to look with each eye separately into the opposite eyepiece and achieve a clear image of the horizontal line dividing the optical wedge into the upper and lower semicircles. To do this, each eyepiece is alternately extended to the optimal distance. The researcher rotates the focus screw of the microscope and brings the optical

wedge into contact with the center of the cornea. The area of corneal flattening is visible through a microscope only when the wedge applies a certain pressure to the eye. Therefore, it is necessary to create a preliminary measuring force of 0.5 g, for which the arrow is placed on the fifth division of the black scale. In this case, two semicircles of dark blue color (flattening area), separated by an interval, become visible (Fig. 1a). This indicates the correct initial position of the tonometer relative to the eye.

Next comes the most crucial moment of the study. The microscope must be precisely focused to clearly see the inner edge of the fluorescent-stained ring formed by the tear fluid. The researcher, under the control of a microscope, smoothly turns the knob of the tonometer scale with his right hand. At the same time, the pressure force of the wedge on the cornea increases as well as the dark blue flattening area. In the field of view of the microscope, not only an increase is visible but also a convergence of dark blue semicircles. The force of pressure on the eye increases until these semicircles, which determine the area of flattening of the cornea, touch one another, a figure resembling a sinusoid is obtained (Fig. 1b).

According to the arrow on the black scale, the researcher sees the true intraocular pressure. Normally it ranges from 12 to 20 mm Hg, often being in the range of 17-18 mm Hg.

In corneal astigmatism, the applanation surface has the shape of an ellipse (the semicircles are elongated or flattened). The optical wedge should be rotated around its axis so that the line dividing it into two parts is in the field of view of the microscope at an angle of 45° relative to the main axis of the ellipse. The tonometry technique for astigmatism remains the same.

During the examination, care must be taken to ensure that the eyelids do not touch the optical wedge and that eyelashes do not fall between the wedge and the cornea. To do this, the patient must keep his eyes wide open. After tonometry, to remove traces of fluorescein, rinse the conjunctival cavity and instill one of the disinfecting solutions.

SL-56 and SLT lamps can be used in pediatric ophthalmology for examining young children (even infants) in a supine position during narcotic or deep physiological sleep. To do this, it is easy to convert existing models by giving them a vertical working position.

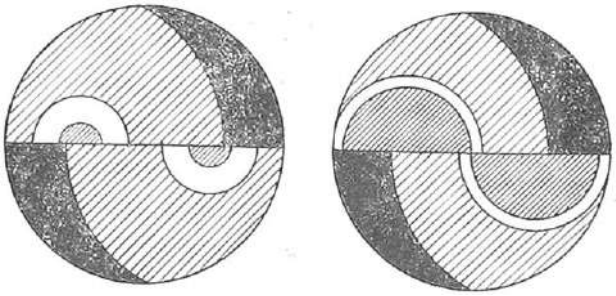

a b

Fig. 1. **Semicircles of the optical wedge: a — misalignment; b — alignment**

Types of illumination

During the microscopy of a living eye, several lighting options are used, which are associated with different types of light projection onto the eye and different properties of its optical media and shells. However, it must be emphasized that all illumination methods currently used in biomicroscopy arose and developed from conventional lateral focal illumination.

Knowledge of the types of lighting when working with a slit lamp is necessary for every doctor who has set himself the task of studying the method of microscopy of the living eye. Only the ophthalmologist who is sufficiently proficient in the basic types of lighting used in biomicroscopy-SKOG1PN can be sure that in his practical work, he uses all the possibilities provided by the slit lamp.

Diffuse illumination is the simplest lighting method for biomicroscopy, easily accessible even to a novice doctor. This is actually the same side focal light that is used in a normal examination of the patient, but only more intense and homogeneous, devoid of spherical and chromatic aberration.

Diffuse illumination is created by pointing an image of a luminous slit at the eyeball. In this case, the slit should be wide enough, which is achieved by maximizing the opening of its diaphragm. Thanks to the presence of a binocular microscope, the possibilities of studying in diffuse light are expanded.

This type of illumination, especially when using a low microscope magnification, has certain advantages. It makes it possible to immediately examine almost the entire surface of the cornea, iris, and lens. This may be necessary if the researcher wants to explore the full extent of the folds of Descemet's membrane or the corneal scar.

Examination in diffuse light gives an idea of the state of the entire lens capsule, lens star, and the surface of the adult lens core.

Using this type of lighting, the researcher can navigate the location of the pathological focus in the membranes of the eye in order to begin an in-depth study of it using other types of lighting that are more suitable for this purpose.

The biomicroscopy angle when using diffuse lighting can be taken arbitrarily.

Direct focal illumination is the main one, leading in biomicroscopic examination of almost all parts of the eyeball. The essence of direct focal illumination is that the image of the luminous slit is focused on a certain area of the eyeball, which, as a result, stands out clearly and precisely and is separated from the surrounding darkened tissues. The axis of the microscope is also directed into this focally illuminated zone.

Thus, with direct focal illumination, the foci of the illuminator and the microscope coincide, they are directed at one point and meet at this point (Fig. 2).

Examination in direct focal light begins with a more or less wide slit (2-3 mm) in order to get a general idea of the tissue to be examined biomicroscopically. After an indicative examination, the slit narrows (in some cases to 1 mm). This provides even brighter illumination and more prominently highlights the area of the eye of interest to the researcher for detailed study.

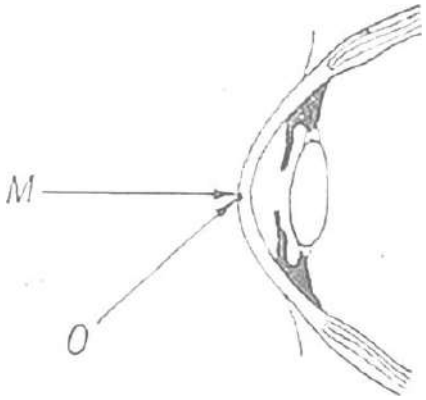

***Fig.* 2. Direct focal illumination**

During normal examination, the optical media of the eye are visible only when they lose transparency. However, with biomicroscopy, when a narrow-focused beam of light passes through transparent optical media, in particular through the cornea or lens, the observer has the opportunity to see the path of the light beam, and the optical medium itself that transmits the light becomes visible. This is due to the fact that a focused beam of light, encountering colloidal structures and tissue cellular elements of the optical media of the eye on its path, undergoes partial reflection, refrac-

tion and polarization upon contact with them. This circumstance determines the visibility of the transparent optical media of the eye.

A peculiar optical phenomenon occurs, known as the Tyndall phenomenon. If a beam of light from a slit lamp is passed through distilled water or a solution of table salt, it will become invisible because it will not encounter particles in its path that can reflect the light. For the same reason, the researcher will not see the slit lamp beam directed into the humor of the anterior chamber. The chamber space appears completely black, optically empty.

If any colloidal substance (protein, gelatin) is added to distilled water, then in this case, the directed beam of the slit lamp is perceived by the researcher, it becomes visible in the same way as colloidal particles suspended in distilled water become visible, since they reflect and refract the light incident on them.

Something similar is observed in the eye during the passage of a light beam through optical media. At the boundary of various optical media of the eye (the anterior surface of the cornea and air, the posterior surface of the cornea and chamber humor, the posterior surface of the lens and the liquid filling the retrolenticular space), the density of the tissue changes quite sharply, and therefore the refractive index of light also changes. This leads to the fact that the focused beam of a slit lamp, directed to the interface between any two optical media, also changes its direction quite sharply.

This circumstance allows the observer to clearly distinguish the dividing surfaces—the boundary zones or the interface zones between different optical media of the eye. When a thin slit-like beam of light passes through these media, the observer gets the impression that the eyeball is, as it were, cut into pieces. Such a thin, focused light beam can be called a "light knife" since it provides an optical section of the transparent tissues of the living eye. The thickness of the optical cut when creating the most narrowed illuminator slit is about 50 μm.

Thus, a section of living tissue of the eye is close in thickness to a histological section; just as histologists prepare serial sections of eye tissue, during biomicroscopy, by moving the illumination slit or the eye of the subject, one can obtain an innumerable number (series) of optical sections. At the same time, the thinner the optical section, the

better the quality of the biomicroscopic examination.

However, the concepts of optical and histological sections should not be identified. The optical section reveals mainly the optical structure of the refractive medium: denser elements and clusters of cells appear as gray areas; optically inactive or inactive zones have a less saturated gray or dark color. In an optical section, in contrast to a colored histological section, the entire complex architectonic of cellular structures is less visible.

When examining in direct focal light, the beam produced by a slit lamp can be concentrated in isolation in a specific optical medium (cornea, lens). This makes it possible to obtain an isolated optical section of a given medium and achieve more accurate focusing within it. This opportunity is used to determine the localization (depth) of a pathological focus or foreign body in the tissues of the eye.

This circumstance greatly facilitates the diagnosis of a number of diseases, making it possible to answer the question of what type of keratitis (superficial, medium, or deep) or cataract (cortical or nuclear) is present in each specific case. Deep localization of a pathological focus under a microscope requires good binocular vision of the doctor.

The angle of biomicroscopy when using direct focal illumination can vary quite widely depending on the need; the most commonly used angle is in the range of 10-30°.

Indirect illumination (research in a tempo field) also plays an important role in eye biomicroscopy. If you concentrate the focus of light on some area of the eyeball, then this brightly lit area itself becomes a source of illumination, albeit weaker.

Reflected by the focal zone, scattered rays of light fall on the tissue lying nearby and illuminate it to some extent. This tissue is located in the zone of parafocal illumination or a dark field, and the axis of the microscope is directed there (Fig. 3).

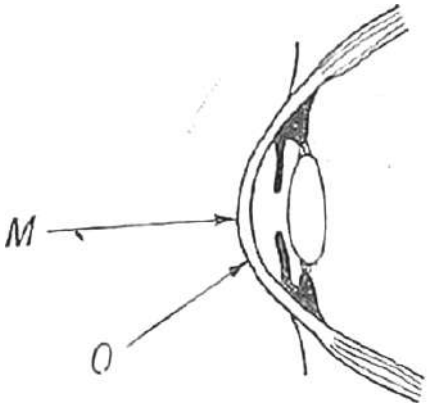

Fig. 3. **Indirect (perifocal) illumination**

With indirect illumination, the focuses of the illuminator and the

microscope do not coincide. The focus of the illuminator is directed to one point (focal illumination zone), and the focus of the microscope to another, i.e., to where the tissue is illuminated due to reflected scattered light. Since light rays from a focally illuminated area propagate not only over the surface of the tissue but also into depth, the indirect illumination method is sometimes called diaphanoscopic.

Indirect illumination has a number of advantages: changes in the deep parts of the opaque media of the eye can be seen, as well as some normal tissue formations can be revealed. Thus, in a dark field on light irises, the sphincter of the pupil is clearly visible, the researcher has the opportunity to observe the contractions and constant intensive work of this important muscle of the iris. In a dark field, normal vessels of the iris and accumulations of chromatophores in its tissue are clearly visible.

An important role belongs to indirect, diaphanoscopic illumination when carrying out differential diagnosis between true tumors of the iris and cystic formations. The tumor, which retains and reflects light, usually stands out in the form of a dark, opaque mass, in contrast to the translucent, lantern-like cystic cavity.

When examining patients with eye injuries, examination in a dark field helps to identify a tear (or rupture) of the sphincter of the pupil, as well as the presence of hemorrhages in the iris tissue, which, when examined in direct focal light, are almost invisible, and when indirect lighting is used, they are revealed in the form of limited areas, colored in dark red.

Indirect illumination is indispensable for detecting atrophic areas in iris tissue. Places devoid of posterior pigment epithelium are visible in a dark field in the form of translucent slits and holes. With pronounced atrophy, the iris in a dark field resembles a sieve or net in appearance.

Oscillatory lighting is a combination of direct focal and indirect lighting. The tissue being examined is either brightly illuminated or darkened. Changing lighting should be fairly quick. Oscillatory illuminated tissue is observed through a binocular microscope.

Oscillatory light is created by moving the entire illuminator or moving only its head prism. Variable, fluctuating brightness of illumination can also be obtained with both lamps by changing the degree of opening of the slit aperture. During the examination, the micro-

scope is at the zero-scale division and does not change its position.

Alternating light during biomicroscopy is used to determine the light reaction of the pupil, which is of undoubted importance in the case of rigid pupils or the presence of hemianopic pupil immobility in a patient. The narrow beam of light allows isolated illumination of one of the halves of the retina, which cannot be achieved with a conventional magnifying glass. To make the study more accurate, it is necessary to create a very narrow slit, sometimes turning it into a pinhole. It is advisable to observe the light reaction of the pupil at low microscope magnifications.

Oscillatory illumination is used to detect small foreign bodies located in the tissues of the eye and not diagnosed by radiographic examination. With rapid changes in lighting, metallic foreign bodies reveal their presence with a peculiar shine. This applies even more to glass fragments located in optical media and the membranes of the eye.

Oscillatory lighting can be used to detect detachment or rupture of Descemet's membrane, which is observed after cyclodialysis surgery or perforated injury. The vitreous Descemet's membrane, which sometimes forms bizarre curls during spontaneous and surgical trauma, gives a peculiar changing shine when examined in oscillatory light.

Transmitted light. This type of lighting is used mainly for examining tissues that transmit light rays well, i.e., the transparent media of the eye. Most often it is used when examining the cornea and lens.

To create transmitted light, it is necessary to obtain the brightest possible illumination behind the tissue being examined. This lighting must be created on some kind of screen capable of reflecting as many rays of light incident on it as possible. The denser the screen, i.e., the more pronounced its reflective ability, the better the quality of the study in transmitted light.

The reflected rays illuminate the tissue being examined from behind. Thus, a study in transmitted light is an examination of fabric for its translucency and transparency. If there are very subtle opacities in the fabric, they delay the light falling from behind, change its direction and, as a result, become visible and are easily caught by the observer.

When examining transmitted light, the foci of the illuminator and the microscope do not coincide and do not merge at one point. If there is a sufficiently wide slit, the focus

of the illuminator is set to the opaque screen, and the focus of the microscope is set to the transparent tissue located in front of the illuminated screen (Fig. 4).

For the cornea, such a screen is the iris, for atrophic areas of the iris - the lens, especially a cataract, for the posterior parts of the vitreous - the fundus.

Transmitted light testing has two options. Transparent fabric can be viewed in the foyer of a brightly lit screen, where the focus of the light beam is directed – this is a study in direct transmitted light. The tissue under study can be examined against the background of a slightly darkened area of the screen - an area located in the parafocal zone of illumination or in a dark field. In this case, the transparent tissue being examined is illuminated less intensely - this is a study in indirectly transmitted light.

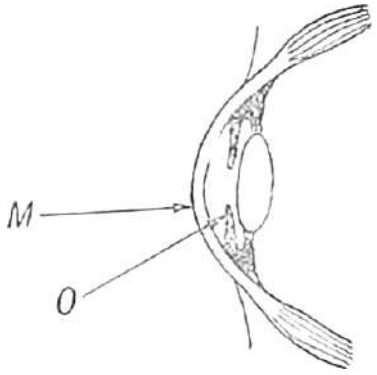

Fig. 4. **Transmitted light**

Beginning ophthalmologists are not always able to perform an examination in transmitted light immediately; the following technique can be recommended for them. After mastering the direct focal illumination technique, the focal light is installed on the iris, and the axis of the microscope should be directed here, as required by the focal illumination technique. The examiner must find the focally illuminated area under the microscope. Next, by rotating the focal screw of the microscope back, i.e. towards you, you need to install it on the image of the cornea, which will be visible in this case in directly transmitted light.

When examining the cornea in indirect transmitted light, the focus of the microscope must first be placed on the dark field zone of the iris, and then successively transferred to the image of the cornea. A normal cornea in transmitted light has the appearance of a barely noticeable, completely transparent, glassy, structureless shell.

Transmitted light examination reveals changes not detectable under other types of illumination. Usually, swelling of the epithelium and endothelium of the cornea, subtle cicatricial changes in the stroma, newly formed, in particular already deserted, vessels of the

cornea, atrophy of the posterior pigment layer of the iris, and vacuoles are clearly visible. anterior and posterior capsules of the lens. When examined in transmitted light, the bullous degenerated corneal epithelium and lens vacuoles appear framed by a dark line, as if inserted into a frame.

When conducting a study in transmitted light, it must be taken into account that the color of the examined tissues is not the same as when studied in direct focal illumination. Opacities in optical media appear darker, as is the case when examined in transmitted light using an ophthalmoscope.

In addition, unusual color shades often appear in the tissue being examined, which can confuse a novice ophthalmologist. The last circumstance is due to the fact that the rays reflected from the screen at the same time receive the corresponding color of this screen, layering it on the fabric through which they then pass. This is why corneal opacities, which have a whitish tint when examined in focal light, appear yellowish against the background of a brown iris, and graybluish when viewed with transmitted light. The clouding of the lens, which has a gray color under focal illumination, acquires a dark shade in transmitted light.

Having detected certain changes during examination in transmitted light, it is advisable to conduct an examination under direct focal illumination, which will give an idea of the true color of the changes and reveal their deep localization in the tissues of the eye.

Sliding beam. This type of lighting was introduced into ophthalmology by Z.A.Kaminskaya-Pavlova in 1939. It consists of the fact that the light from the slit lamp is directed at the eye being examined perpendicular to its visual line (Fig. 5). The technique of obtaining a sliding beam is not difficult; this method of illumination is accessible even to a beginning ophthalmologist.

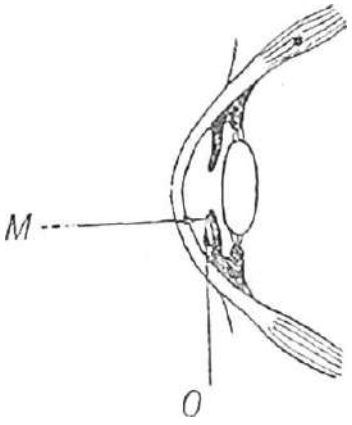

Fig. 5. **Sliding beam**

To obtain a sliding beam, the illuminator must be moved as far as possible to the side, towards the

temple of the subject; it is advisable to open the illumination slit diaphragm wider. The patient's gaze should be directed straight ahead. This creates the possibility of almost parallel sliding of light rays along the surface of the membranes of the eyeball. If there is no such parallelism in the direction of the light rays, then the patient's head should be slightly turned in the direction opposite to the incident rays. With this type of illumination, the axis of the microscope can be directed to any area of interest to the researcher. A sliding beam is used to examine the surface relief of the eye membranes.

By giving different directions to the beam, you can make it slide along the surface of the cornea, iris and that part of the lens that is located in the lumen of the pupil. Since the most prominent layer of the eye is the iris, c. In practical work, a sliding beam should most often be used specifically for its inspection. A ray of light sliding across the front surface of the iris illuminates all its protruding parts and leaves the recesses darkened. That is why this type of lighting is good at revealing the smallest changes in the relief of the iris, for example, smoothing it out during tissue atrophy. It is advisable to use a sliding beam in difficult cases of diagnosing neoplasms of the iris, especially when differential diagnosis is carried out between a neoplasm and a pigment spot.

A dense tumor formation usually delays the grazing beam. That part of the tumor that faces the incident beam is brightly illuminated, while the opposite part is darkened. The tumor, which delays the sliding beam, casts a shadow from itself. This usually sharply emphasizes that the neoplasm protrudes above the surrounding, unchanged iris tissue. In the presence of a pigment spot (nevus), no contrast is observed in the illumination of the tissue under study, which indicates the absence of its persistence.

The sliding beam method also allows us to identify small irregularities on the surface of the anterior lens capsule. This is important when diagnosing detachment of the zonular lens plate. A sliding beam can be used to examine the surface relief of the adult lens nucleus, on which protruding warty seals appear in old age. When a beam of light slides along the surface of the nucleus, these changes are usually easily detected.

Research in reflective zones. The technique of research in reflective zones is quite difficult; it is accessible only to ophthalmologists who already know the basic types

of lighting used in biomicroscopy. This type of lighting opens up great diagnostic possibilities for the researcher. It is used to inspect and study the interface zones of the optical media of the eye.

When a focused beam of light passes through zones of optical media, more or less reflection of the beam occurs, each reflecting zone turns into a kind of mirror and gives a light reflex. Such reflective mirrors are the surfaces of the cornea and lens.

According to the law of optics, if a ray of light falls on a spherical mirror, then the angle of its incidence is equal to the angle of reflection, and both of them lie in the same plane - these are correctly reflected rays. The zone where the correct reflection of light occurs is quite difficult to see since it shines brightly and blinds the researcher. The smoother the surface, the more pronounced its light reflex.

When depressions and protrusions appear on the mirror surface (reflective zone), the reflected rays receive the wrong direction and become diffuse - this is an incorrect reflection of light. Such incorrectly reflected rays are perceived more easily by the researcher than rays reflected correctly: the reflecting surface itself is better visible, the recesses and protrusions on it are revealed in the form of dark areas.

To see the rays reflected from the mirror surface and perceive all its smallest irregularities, the observer must place his eyes in the path of the reflected rays. Therefore, when examining in a mirror field, the axis of the microscope is directed not to the focus of the light coming from the slit lamp illuminator, as is done in the case of direct focal illumination, but to the reflected beam (Fig. 6).

This is not an entirely easy task, since during research it is necessary to capture in the microscope not a wide beam of diverging rays, as was the case with other types of lighting, but a very narrow beam of light having a certain direction.

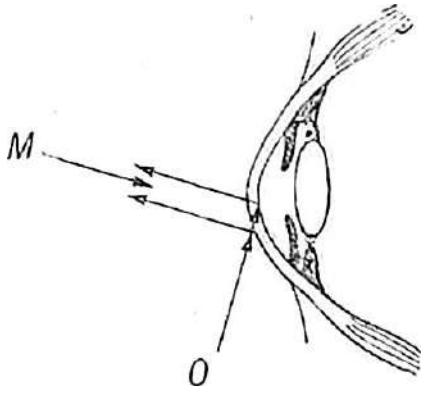

Fig. 6. **Mirror field**

To make it easier to see reflected rays, you can position the illuminator and microscope at a right

angle. The visual axis of the eye should divide this right angle in half. With a wider slit, focused light is directed onto the cornea. It should fall towards the visual axis of the eye at an angle of approximately 45°. This incident focused beam is clearly visible to the observer.

To make it easier to perceive both the opposite, reflected beam (it will also be reflected at an angle of 45°), it is recommended to first receive it on the screen. To do this, a white screen (paper) is placed along the reflected beam. Having received the reflected beam, the screen is removed, after which the axis of the microscope is set in the same direction.

When these conditions are met, the mirror fields of the cornea become visible under the microscope. They look like bright, shiny, small areas. To facilitate the examination and reduce the brightness of the reflective zones, it is recommended to use a narrower slit. The technical difficulty of research in reflective zones is compensated by the advantages that this type of lighting provides to the ophthalmologist.

When examining the anterior surface of the cornea in a mirror field, a very blinding reflection area is visible. Such a strong reflection of the rays is due to the fact that the difference in the refractive index between the cornea and the air is large. In the reflective zone, the smallest irregularities of the epithelium and its swelling in a number of pathological conditions are revealed. Dust particles and mucus in the tear are also visible.

The reflex from the posterior surface of the cornea is smaller, which is due to the fact that this surface has a smaller radius of curvature compared to the anterior one. This reflex has a golden-yellowish tint and is less shiny. This circumstance can be explained by the fact that part of the rays reflected by the posterior surface of the cornea, when returning to the external environment, is absorbed by the cornea's own tissue and reflected back by its anterior surface.

The mirror field method reveals a mosaic structure of a layer of endothelial cells on the posterior surface of the cornea. In pathological conditions, in the reflex zone, one can see folds of Descemet's membrane, its warty thickenings, swelling of endothelial cells, and various kinds of deposits on the endothelium.

In cases where the examiner has difficulty distinguishing the anterior surface of the cornea from the posterior one in the reflex zone,

it can be recommended to use a larger biomicroscopy angle. In this case, the mirror surfaces will separate and move away from one another. Mirror zones from the surface of the lens are much easier to obtain. The anterior surface is larger in size than the posterior one. The back surface in a specular field is visible much better since it reflects less.

When examining the reflective zones of the lens, the unevenness of its capsule, the so-called shagreen, is clearly visible, due to the peculiar arrangement of the lens fibers and the presence of a layer of epithelial cells under the anterior capsule. When examining the lens interface zones in a mirror field, they are not clearly visible, which is due to the insufficiently sharp delineation of each zone and the relatively small difference in their refractive index.

Chapter 2

METHODOLOGY OF BIOMICROSCOPY OF THE MEMBRANES AND OPTICAL MEDIA OF THE EYE

Mastering the technique of biomicroscopic examination is not an easy task for a beginning ophthalmologist. For physicians who have experience with a microscope and are familiar with the basic principles of optics, this task is greatly simplified.

The living eye microscopy method is a complement, expansion and deepening of other well-known methods for examining the diseased eye, therefore, a biomicroscopic examination, as a rule, should be preceded by a routine examination of the patient.

After collecting anamnesis, the doctor examines the patient in daylight, using lateral focal light, conducts a study in transmitted light, and ophthalmoscopy. Functional studies of the eye (determination of visual acuity, perimetry) should also precede biomicroscopy.

Practical experience shows that if the study of eye functions is carried out after biomicroscopy, this leads to erroneous data, since a patient who was exposed to strong light from a slit lamp even for a short time has reduced visual functions, which is apparently due to temporary depletion of the visual analyzer.

An exception to this is the study of intraocular pressure. This manipulation should, as a rule, be carried out after biomicroscopy; otherwise, the traces of paint remaining on the cornea after tonom-

etry will greatly interfere with a detailed examination of the eye tissues with a slit lamp. Thoroughly washing the eye or instilling disinfectant drops after tonometry does not completely remove the paint, and it is revealed under a microscope on the anterior surface of the cornea in the form of a brown coating.

A preliminary examination of the eyeball usually raises a number of questions for the doctor regarding the depth of localization of the pathological focus in the tissues of the eye, the duration of the disease process, etc. These questions are resolved through further biomicroscopic examination.

The doctor should strive to ensure that the microscopy of the living eye is to a certain extent targeted so that the researcher poses certain questions and resolves them by using a slit lamp. This approach to the biomicroscopy method makes it more meaningful and significantly shortens the patient's examination time, which is especially necessary in cases where the patient suffers from pain, photophobia and lacrimation.

In this condition of the patient, in the process of biomicroscopy, it is necessary to resort to the help of another person, whose role is to hold the patient's head, since he, suffering from photophobia, sometimes involuntarily strives to move away from the source of bright light. The role of the assistant is also to open and hold the eyelids.

In acute inflammatory processes, the patient's discomfort during the examination can be significantly reduced by the preliminary instillation of a 1% solution of dicaine into the conjunctival sac two or three times. A calmer patient behavior will reduce the time of the slit lamp examination.

Microscopy of the living eye must be carried out in a darkened room, but there should not be complete darkness. Therefore, it is advisable to place a regular table lamp behind the observer, at some distance from him. To prevent the lighting from being too bright, it is recommended to turn the lamp towards the wall or, if you have a bendable tripod, lower it downwards. Moderate light falling from behind does not interfere with the doctor's work.

The doctor can observe the patient and guide him during the examination process. However, when performing biomicroscopy, there are times when complete darkness is required. This applies to the study of very thin structures that reflect little light, such as the vitreous body.

Biomicroscopy of the eye requires a certain amount of effort from both the patient and the doctor since both of them must be very attentive, concentrated and completely motionless for some time. Taking this into account, it is necessary to create certain conveniences for the patient and the doctor before conducting the study.

The patient is seated on a swivel chair in front of an instrument table on which a slit lamp is installed. The table should be raised up or down according to the height of the patient. The patient should not be allowed to sharply stretch his neck upward when placing his head in the facial position. In this case, the contact of the forehead with the head support will be incomplete, which will affect the quality of the study. When the support is placed low, the patient is forced to bend, which causes, especially in older people, difficulty breathing and rapid fatigue.

After fixing the head in support, the patient is asked to calmly place his arms bent at the elbows on the instrument table and lean lightly on it. The doctor is placed on the other side of the table with a slit lamp installed on it. The seat on the doctor's chair must be movable (swivel chair) and correspond to the height of the device.

During the examination, in order to avoid excessive fatigue of the patient and overheating of the lamp, it is necessary to take breaks. Overheating of the lamp, accompanied by significant overheating of the surrounding parts of the illuminator, can lead to the appearance of cracks in the condenser. This affects the quality of the lighting slit, in which, according to the location of the cracks in the condenser, a darkened area (defect) appears. Therefore, during the biomicroscopy process, after a 3-4-minute examination, the patient is asked to hold his head up with his face upright and sit up straight in a chair. The slit lamp illuminator is switched off from the electrical network. After a short rest, research can continue. Such breaks in the study relieve the patient from overwork and extend the life of the lamp.

For physicians less familiar with biomicroscopy techniques, we recommend using a specific, preferably low, microscope magnification. Only as you acquire working skills you can vary the degree of magnification of the microscope more widely. Beginning ophthalmologists may be advised to first train on each other. This shortens the learning curve for biomicroscopy and, in addition,

gives the doctor an idea of the sensations that the patient experiences during the biomicroscopy process.

Conjunctiva

Biomicroscopy of the conjunctiva does not present any difficulties since its main sections are easily accessible to examination with a slit lamp. However, when examining the conjunctiva of the eyelids, the assistance of another person is necessary, whose role is to evert and hold the eyelids.

In the process of biomicroscopy of the conjunctiva of the eyelids, it is often necessary to pay special attention to the examination of transitional folds. When the upper eyelid is everted, its transitional fold does not protrude forward enough and therefore cannot be examined with due care, and this is sometimes absolutely necessary.

In order to facilitate the study of transitional folds, it is proposed to inject 1 ml of 0.5% novocaine solution under the conjunctiva. This leads to the fact that the transitional fold protrudes forward well. Novocain straightens the folds of the conjunctiva, follicles, papillae, and scars are better visible on the stretched conjunctiva.

Almost all types of lighting can be used for conjunctival biomicroscopy. In diffuse light at low microscope magnifications, a general overview of the conjunctiva is usually performed. Examination in an optical section with a narrow slit is useful when examining edematous conjunctiva, follicular formations, and when examining conjunctival cysts. Examination of the conjunctiva using indirect lighting reveals the silhouettes of the meibomian glands and the presence of scar changes. The use of diaphanoscopic illumination helps in making a differential diagnosis between translucent follicles and opaque papillary formations.

The conjunctiva of the eyeball is known to be a transparent, translucent tissue, so it can be examined in transmitted light. Rays of light penetrating freely through the conjunctiva fall on the underlying sclera and form a strongly illuminated screen. Against the background of this screen, numerous conjunctival vessels and cystic formations are clearly visible. To study the state of the conjunctival vascular network, you can use red-free light (blue-green filter). In this case, the vessels appear more clearly in the form of dark branches on a bluish-green background.

A grazing beam examination reveals various types of irregularities on the surface of the conjunctival tissue. When using the mirror

field method, the formations of the conjunctiva protruding forward give a kind of intense brilliant reflex, which sharply catches the eye of the examiner.

Cornea

Biomicroscopy of the cornea is of great importance in the clinic of eye diseases. In addition to identifying the smallest changes in the transparent tissue of the cornea, examination with a slit lamp allows you to localize the detected changes in depth, i.e., determine in which layers of the cornea they are located.

Examination of the cornea can be done using almost all types of lighting, but the main ones should be considered direct focal light, examination in transmitted light and in reflective zones.

After an indicative examination of the cornea using diffuse illumination, it is advisable to proceed to examination in direct focal light. To create this type of illumination, a beam of light from a slit lamp is directed at an angle of 10-40° onto the surface of the cornea and concentrated on it.

The concentration of the focus of light on the tissue being examined is achieved by moving the handle of the coordinate table in the anterior-posterior direction. In this case, the rays of light are concentrated on the cornea, as a result of which it is, as it were, separated from the surrounding environment (from air and chamber moisture), standing out against a dark background in the form of a clearly visible, sharply demarcated strip of gray color.

If there is a wide illumination slit, the light beam, passing through the cornea, cuts out a brightly illuminated parallelepiped or tetrahedral prism in its tissue.

When examined under a microscope, it is clear that the optical prism has a convex-concave shape. The place where light enters the cornea is distinguished as the anterior epithelial surface of the prism, and the place where light exits the cornea is distinguished as its posterior endothelial surface. It is usually visible less clearly than the front surface.

Due to the diffuse internal reflection of the slit lamp light by the corneal tissue, the inner part of the prism, corresponding to the corneal tissue itself, is also visible. The width of the front and rear surfaces of the prism depends on the width of the lighting slit. With a sharply narrowed gap, these surfaces turn into very narrow areas, and the parallelepiped itself (its side) takes the form of a narrow optical section of the cornea.

When biomicroscopy of the cornea, one often has to use the term “optical section”. An optical section is a very narrow parallelepiped cut by light rays into the corneal tissue. The term "optical section" of the cornea refers to the side of the optical section facing the observer.

By moving the illumination slit in the horizontal direction, it is possible to examine the entire cornea under a microscope in an optical section.

The examination in direct focal light can be of high quality only if a clear optical section of the cornea is obtained. The criterion for the quality of the cut is a clear image of all four edges of the corneal parallelepiped. With a very narrow illumination slit, only three cut edges are clearly visible. The two ribs lying on the anterior convex surface of the cornea refer to the anterior cut surface. One rib, located on the posterior, concave surface of the cornea, refers to the posterior surface of the cut.

A novice researcher should not be confused by the fact that he sometimes has to observe in the same patient, with the same width of the illumination slit, a change in the degree of curvature and thickness of the optical section of the cornea. This circumstance is due to the different angle of incidence of the light beam.

At a large angle of incidence of the beam (with a more peripheral position of the illuminator), the slice appears more curved and thicker. The almost vertical incidence of the beam changes the appearance of the optical section of the cornea, which becomes less curved and less thick.

Using a very thin, well-focused optical section, it is possible to determine the localization of a pathological focus or foreign body in the corneal tissue, i.e., the depth of its occurrence. This is done by moving the optical section of the cornea to the pathological area.

If the altered corneal tissue is visible (fits into the section) at its anterior surface, it means that it is localized in the anterior parts of the cornea. The appearance of a pathologically altered area of tissue near the posterior edge of the optical section will indicate its localization in the posterior parts of the cornea. If the area of interest to the researcher turns out to be located in the corneal section between the anterior and posterior ribs of the optical section, its localization can be attributed to the central, parenchymal areas of the corneal tissue.

Examination in direct focal light allows you to identify de-

fects in your own corneal tissue. They are detected by a characteristic depression on the front surface of the optical section. More delicate, epithelial defects (erosions), which do not give a noticeable change in the curvature of the corneal surface, are detected by intravital staining of the corneal tissue with fluorescein.

Usually, after instilling two drops of a 2% soda solution of fluorescence into the conjunctival sac and then washing it off with a stream of physiological solution, you can see that the intact corneal epithelium is not stained with fluorescence, and the eroded areas have acquired a bright yellow-green color.

When examining the cornea in transmitted light, the focus of the illuminator is directed to the iris. The light reflected from the iris passes through the transparent tissue of the cornea completely freely, but gives it a slightly bluish or yellowish tint (depending on the color of the iris). Normal corneal tissue is almost invisible to the researcher due to its transparency.

Slight clouding of the cornea, swelling of the epithelium and endothelium, and newly formed vessels can be seen in transmitted light much better than in direct focal illumination. In retrospective diagnosis of a number of keratitis cases, a detailed study of corneal vascularization may be necessary.

In order to more actively identify old empty vessels of the cornea during biomicroscopy, before examination in transmitted light it is advisable to expand these vessels, restoring blood flow in them for a short time. To do this, you can use massage of the cornea through the eyelids, instillation of dionin.

Research in the reflective zones is carried out at a high angle of biomicroscopy. Under this condition, it is easier to catch the light rays reflected from the mirror surface.

The peripheral incidence of light promotes the separation of the anterior and posterior mirror zones of the cornea. In this case, the mirror surfaces do not overlap or cover one another, which make it possible to study each of them in detail.

The anterior surface of the cornea in the mirror field appears as a bright, shiny rectangle with unclear boundaries. It shows elements of dust, tears, fat (secret of the meibomian glands). The tear usually obscures the smallest irregularities of the epithelial surface of the cornea. Sometimes during biomicroscopy, the color iridescence of the anterior reflection zone is visible, which is associated with the phenomenon of interference of light

beams as they pass through the tear fluid.

The posterior surface of the cornea is revealed in the mirror field better than the anterior one. However, the examiner can examine it in detail only when he is able to "suppress" the brilliant image of the anterior surface of the cornea.

The mirror area of the posterior surface of the cornea seems to repeat the shape of the anterior mirror area, but it is somewhat smaller in size and less bright. Its boundaries are also unclear.

Front camera

Examination of the anterior chamber is not very difficult. Various biomicroscopy angle options can be used. The lighting slit should be as narrow as possible and as bright as possible. Among lighting methods, preference should be given to direct focal light.

To judge the depth of the anterior chamber, it is necessary to use a small angle of biomicroscopy. In this case, the microscope should be positioned strictly along the midline, and its focus should be set to the image of the cornea. By moving the microscope's focal screw forward, a clear image of the iris is obtained in the field of view.

By assessing the degree of distance of the cornea from the iris (by the degree of displacement of the microscope focal screw), one can to a certain extent judge the depth of the anterior chamber. A more accurate determination of the depth of the anterior chamber is made using special additional settings (micrometric drum in the slit lamp of the slit lamp).

To study the state of chamber moisture, a wider (larger) biomicroscopy angle should be used, for which the illuminator must be moved to the side. The microscope remains in the middle, zero position. The larger the biomicroscopy angle taken, the larger the apparent distance between the cornea and the iris appears.

When the illuminator is positioned on the front side, the possibility of examining the internal parts of the chamber increases, and, conversely, when the illuminator is moved to the nasal side, it becomes possible to examine the external parts of the chamber.

Iris

The iris, which is the anterior part of the vascular tract, is clearly visible during biomicroscopic examination. The technique for examining it is simple. When studying the iris, many types of lighting

used in biomicroscopy can be used. The examination should begin with diffuse lighting, which is used for a general overview of the tissue, judgment about its color, relief, width, and shape of the pupil. Research in diffuse light is carried out with a wide illumination slit and low microscope magnifications.

The main type of lighting for detailed biomicroscopy of the iris is direct focal light. The angle between the illuminator and the microscope should be quite wide - within 40-50°. It is not recommended to make the lighting slot narrow.

Direct focal light reveals the rich structure of the iris well. It is indispensable for detecting a number of pathological changes associated with inflammatory, dystrophic and tumor processes.

A study in direct focal light makes it possible to judge the degree of protrusion above the surface of the iris, i.e., the prominence of the inflammatory granuloma or neoplasm into the anterior chamber.

When examining a low-pigmented iris using direct focal light and a narrow illumination slit, an optical section of its tissue can be obtained. In this case, a beam of light penetrating deep into the loose stroma of the iris reveals individual trabeculae containing centrally located vessels.

Inspection of the iris using indirect illumination or a dark field is performed almost simultaneously with inspection in direct focal light. To do this, the axis of the microscope, directed under direct illumination to the zone of the brightest focal light, moves to the area located next to it. The angle of incidence of light, when viewed in a dark field, should be slightly larger than with direct focal illumination.

In a dark field, the sphincter of the pupil, cystic cavities in the iris tissue, and areas of atrophy are easily identified. This type of lighting facilitates the study of changes in the iris of traumatic origin, identifying tears and complete ruptures of the sphincter of the pupil, areas of perforation of the iris, and hemorrhages in its tissue. A type of indirect lighting, as mentioned above, is diaphanoscopic light.

To examine the iris under diaphanoscopic lighting, it is necessary to maximize the light intensity, widen the illumination slit and direct its focused image to the limbus area; the microscope is aimed at the area of the iris being examined. This lighting option should be used in the differential diagnosis between a tumor and an iris cyst.

The presence of a compact opaque mass, the absence of tissue transillumination in the first case, and the obvious rarefaction of the structure of the iris, its active translucency in the second, contribute to the correct and timely differential diagnosis of these formations.

Variable or oscillatory illumination, created by a combination and alternating change of direct focal and indirect illumination, provides an invaluable service in studying the light reaction of the pupil, especially if the patient has hemianopsia.

Directing the light beam onto the sighted half of the retina usually causes a constriction of the pupil. When illuminating the non-functioning (blind) half of the retina, the light reaction of the pupil is absent. This reveals hemianopic immobility of the pupils.

Oscillation light can be used to detect a foreign body, especially when it is partially covered by the iris tissue and other types of lighting are ineffective. The peculiar shine that appears on the translucent surface of a foreign body when the lighting changes helps the doctor make the correct diagnosis.

Transmitted light may be used to examine the iris. Examination of the normal iris in transmitted light is almost impossible since the posterior pigment layer actively blocks the rays of light reflected by the lens. Therefore, this type of illumination is applicable only for the study of a pathologically altered iris, when its tissue is sparse and there are defects in it. Examination of the iris in transmitted light works well in albinos.

To create this type of illumination, a secondary light source behind the iris is required. For this purpose, the light beam from the illuminator must be directed at the greatest possible angle into the pupillary area: the wider the pupil, the greater the angle of incidence of the light beam can be applied. The light must be focused on the lens. This is possible in cases where the lens is cloudy and reflects a lot of light.

However, the transparent lens, especially in older people, quite intensively reflects the rays falling on it and serves as a screen when examining the iris in transmitted light.

To examine the inner half of the iris, the light on the lens must be directed from the outer (temporal) side. The microscope focuses on the inner part of the iris being examined. When examining the outer half of the iris, light is directed onto the lens from the inner (nasal) side, and the microscope is

installed according to the outer half of the iris. This type of lighting cannot be used in aphakia, since the vitreous body is a medium that very weakly reflects light rays passing through it.

The transmitted light examination is indicated mainly for identifying pathology of the posterior pigment layer of the iris. Using this type of lighting, you can easily see the atrophy of the pigment border of the pupil and the posterior pigment layer of the iris along its entire length.

Places of atrophy in transmitted light have the appearance of grayish or slightly yellowish translucent spots and stripes, sharply contrasting with the surrounding unlit iris tissue. Their color depends on the color of the light beam reflected by the lens.

Examination in transmitted light also easily reveals the smallest tears and ruptures of the sphincter of the pupil, accompanied by a violation of the integrity of the posterior pigment layer of the iris, and cysts arising from the posterior pigment epithelium and usually localized in the area of the pupillary edge.

For a detailed study of the rich relief of the iris, a special lighting method called a sliding beam is required. If direct focal light penetrating the spongy tissue of the iris makes it possible to evaluate its structure at depth, then a sliding beam helps to identify the surface relief of the iris.

A sliding beam directed at the iris perpendicular to the visual axis reveals the smallest irregularities on the surface of the tissue. With the help of this lighting, the presence of inflammatory foci in the iris tissue can be detected very early, as well as the erased pattern and smoothing of the tissue relief during degenerative processes.

It is advisable to use a sliding beam in the differential diagnosis of iris melanoblastoma and pigment spots. At the same time, the tumor mass that protrudes forward and delays the gliding beam clearly differs from a flat nevus, over which the light beam glides completely unhindered.

Lens

Examination of the lens with a slit lamp presents certain technical difficulties and requires the examiner to have certain skills in the field of microscopy of the living eye. Biomicroscopy of the lens is performed in a darkened room. The slit lamp light should be as intense as possible.

For a complete examination of the lens, it is recommended to first

direct the light beam from the temporal and then from the nasal side. According to the incidence of light, in the first case, predominantly the inner half of the lens will be visible, and in the second case, the outer half of the lens. The examination of the lens is hampered by the iris lying in front of it; when examining with a narrow pupil, it is possible to see only the central zone of the lens.

Examination of the paracentral regions is not possible due to significant miosis caused by the bright light of the slit lamp. Meanwhile, it is known that the largest percentage of acquired changes in the lens begin in its peripheral parts, hidden from the researcher by the iris. Therefore, a necessary condition for a high-quality biomicroscopic examination of the lens is the creation of stable drug-induced mydriasis. However, even in the presence of maximum mydriasis, it is not possible to examine the equatorial parts of the lens and the zone of attachment of the fibers of the ligament of Zinn. This becomes possible only in cases of complete or peripheral coloboma of the iris, and pyridine, traumatic displacement of the lens.

During lens biomicroscopy, the patient must move the eye being examined alternately to one side, which will make it possible to examine the peripheral parts of the lens.

When examining the lens with a slit lamp, almost all types of lighting can be used, but the main ones are diffuse light, direct focal light, transmitted light, and examination in reflective zones is also advisable.

The examination should begin with diffuse lighting, with a wide lighting slit and an arbitrary (preferably wide) biomicroscopic angle. The lens is illuminated by a scattered beam of light, and the focus of the microscope is set on the front surface of the lens. The magnification of the microscope should be relatively small (no more than 18X). Such illumination will give a general idea of the state of the lens capsule and changes of inflammatory or embryonic origin.

In diffuse lighting, the shagreen of the anterior capsule of the lens, the lens star, the surface of the senile nucleus, and some opacities of the lens substance usually appear. Despite a number of advantages of this type of lighting, it does not make it possible to determine the depth of the pathological focus in the lens, which is of great importance in the clinical practice of an ophthalmologist. This is compensated by examining in direct focal light.

Inspection of the lens using direct focal light should begin with an average biomicroscopy angle and a fairly wide illumination slit, and then gradually move to a narrower biomicroscopy angle (10-20°) and the narrowest illumination slit. Just as when examining the cornea in direct focal light, one can cut out (isolate) its tissue in the form of a parallelepiped or an optical section, a section of tissue of varying thickness is also distinguished in the lens. The thickness of the cut depends on the width of the lighting slit.

The lens section has the appearance of a silver-gray semitransparent barrel, enclosed between dark, optically empty spaces. In front, the cut of the lens borders on the moisture of the anterior chamber, and on the back - on the moisture of the retrolenticular capillary space. In the presence of aniridia or wide coloboma of the iris, the cut of the lens takes on the shape of a lentil, since its equatorial sections, closed under normal conditions by the tissue of the iris, open.

The optical section of the lens is heterogeneous; it has several division zones, or dividing stripes. This circumstance is associated with different degrees of density of the lens tissue, which in turn determines different degrees of refraction of the incident light. The division zones of the lens have the appearance of grayish stripes interspersed with dark areas that are less refractive to light.

The size of the lens in the sagittal direction is 3.6 mm, which is more than 3 times the thickness of the cornea. Since the anterior, middle and posterior sections of the optical section of the lens are at different depths, they (unlike the cut surface of the cornea) cannot be seen clearly with the same focal setting. Only by moving the focus of the illuminator and the microscope in the anterior-posterior direction along the axis of the lens can one achieve a clear image of each of the indicated sections of the lens in turn. In this case, it is necessary to ensure that the basic principle of direct focal illumination is preserved—the coincidence of the focus of the illuminator and the microscope on the tissue being examined.

By slowly moving the illuminator and microscope in a horizontal direction, a series of sagittal sections of the lens substance can be obtained.

Examination in direct focal light with a narrow slit provides precise localization of pathological changes in the lens. In the presence

of cataracts, it becomes possible not only to localize the opacification based on the depth of its location but also to determine when it developed.

The transmitted light examination is used to examine changes localized in the anterior and middle parts of the lens. In this case, the focus of the illuminator is directed to the back surface of the lens, which acts as a screen, and the focus of the microscope is directed to the area of interest to the researcher, located in front of the screen. Rays of light reflected by the back surface of the lens and returning back are delayed by opaque elements located in the lens material. This makes it possible to detect the smallest structural changes in the lens tissue. In this way, the system of lens sutures, subcapsular vacuoles, water gaps, various opacities of the lens, and deposits on its capsule are revealed.

It should be taken into account that when examined in transmitted light, many formations change their appearance and color. The latter circumstance is associated with different colors of the light beam reflected by the back surface of the lens. With sclerosis of the lens nucleus, the reflected rays acquire a yellowish tint; with cataractous changes in the shielding surface, they become gray-white.

Subcapsular vacuoles, difficult to distinguish under other types of illumination, are revealed in transmitted light as round formations with a light center and a dark rim along the periphery. Lens opacities appear as dark spots and streaks, and when examined in direct focal light they have a gray-white color.

Newly formed vessels on the lens capsule, when examined in transmitted light, are revealed as thin strands of a dark red color, often with the presence of blood flow in them, while in direct focal light, the same vessels look like whitish stripes without noticeable movement of blood in them.

Research in the reflective zones (mirror field) occupies a prominent place when examining the lens, allowing one to judge the condition of the lens surfaces, the anterior and posterior surfaces of the senile nucleus.

When obtaining a mirror field, the basic condition of equality of the angles of incidence and reflection of light must be met. The specular field of the anterior surface of the lens is a rather wide, shiny silvery zone. Its width depends on the width of the illumination slit, and its length depends on

the radius of curvature of the lens surface. This zone is not uniform; it is dotted with small irregularities that form a shagreen pattern on the anterior surface of the lens.

The mirror field of the posterior surface of the lens is smaller than the mirror field of the anterior surface, which is associated with a smaller radius of curvature. In older people, it acquires a yellowish color due to the shade of the senile nucleus lying in front. Shagreen is also visible here, but it is less pronounced than on the anterior surface of the lens, which is due to the absence of a layer of epithelial cells under the posterior capsule of the lens. The appearance of dark zones in shagreen indicates a violation of the integrity of the lens capsule.

The mirror fields on the surface of the adult nucleus are smaller and less bright compared to the zones of the anterior and posterior surfaces of the lens.

Vitreous body

Examination of the vitreous body with a slit lamp is of great importance in the clinical practice of an ophthalmologist. This value is all the greater because the histological examination of the vitreous body is limited since, when cutting even an eyeball well fixed in formaldehyde and alcohols, a large part of the vitreous body flows out. In this regard, histological examination is limited to examining only a small portion of the remaining vitreous stroma, which undergoes significant changes during histological processing.

Examination of the vitreous with a slit lamp, especially for novice ophthalmologists, is not an easy task. This is due to the fact that the vitreous body, in comparison with other parts of the eye, is located quite deep. In addition, it has a jelly-like consistency and weakly reflects the incident rays of light. Biomicroscopy of the vitreous body is hampered by a narrow pupil, which contracts sharply under the influence of intense light from a slit lamp.

A prerequisite for high-quality biomicroscopy of the vitreous body is the creation of maximum contrast in lighting. This is achieved by good darkening of the room where the study is being carried out and strong illumination of the area being examined. Since the vitreous body is a weakly refractive optical medium with insignificant internal reflection of light, it is necessary to use not only the brightest but also a fairly wide illumination slit. Severe narrowing of the gap makes it impossible to clearly see the details of the vitreous body.

A prerequisite for high-quality biomicroscopy of the vitreous body is also the presence of severe drug-induced mydriasis in the patient. The biomicroscopic angle should be small and vary between 10-20°. To examine the anterior layers of the vitreous, you can take a larger angle, but as you penetrate into deeper parts, this angle should be progressively reduced. Since the vitreous body has a semi-liquid consistency, it is examined mainly in direct focal light. The low reflectivity of the vitreous body limits the use of other types of lighting. However, when examining the posterior vitreous, transmitted light examination can be used. In this case, the fundus of the eye serves as a reflective screen. This type of lighting can also be used in certain pathological conditions, for example, intraocular tumor, retinal detachment and clouding. In these cases, the formation protruding into the vitreous plays the role of a light-reflecting screen.

In order to more fully examine the vitreous body, light rays should be directed not only from the temporal side but also from the nasal side. In the first case, the nasal half of the vitreous is examined, and in the second, the temporal half is examined. The patient's gaze should be directed straight ahead during the examination.

When biomicroscopy of the vitreous body, you should not use a high microscope magnification: a magnification of 9-18 times is sufficient.

The technique for examining the anterior and posterior parts of the vitreous is somewhat different. The examination should begin without a microscope. This type of examination in direct focal light with the naked eye is called phentoscopy. In contrast to biomicroscopy itself, it has a number of advantages: almost the entire skeleton of the vitreous body is visible, and when examining through a microscope one has to be content with examining it in parts; hemorrhages into the vitreous body, inclusions of exudate and detachment of the vitreous body are clearly visible, if they are sufficiently pronounced.

The study begins by directing a narrow beam of light through the dilated pupil to the back surface of the lens and focusing it there. This helps differentiate the posterior surface of the lens from the vitreous. Next, you need to make the illumination slit wider, then in the focal beam of light behind the lens, the fibrillar skeleton of the vitreous body is revealed, interspersed with

dark layers of the vitreous substance.

After the phentoscopic examination, one should begin examining the vitreous body using microscope magnifications. First, you need to place the back surface of the lens in the field of view of the microscope, after which you should go deeper as necessary. Depth focusing is carried out by moving the handle of the coordinate table. Since the vitreous body does not have regular division zones and fixed points, the details of its structure are better revealed by slight movements of the eye, which can be caused by blinking movements of the eyelids.

In cases where the skeleton of the vitreous body is very thin and delicate, during the inspection the illumination slit should be opened wider.

Examination of the posterior half of the vitreous body can be carried out using the domestic lamp ShchL-56. For this purpose, a diverging lens attachment (Gruby lens) located on the microscope body is used. This lens neutralizes the optical system of the eye, which makes it possible to view the posterior parts of the vitreous. Before examination, the lens should be moved to the lower (working) position and placed in front of the eye being examined. This is achieved by pulling the locking rod towards you and turning it 180° clockwise.

Focus adjustment is made immediately through the microscope by moving the handle of the coordinate stage. First, the focus of the microscope is set to the image of the fundus. In this case, not only the reflex from the fundus of the eye should be visible, but also the retinal vessels or the optic nerve head.

After this, the focus of the microscope moves back (towards oneself). In this case, the image of the retina becomes veiled, and at the same time, the posterior parts of the vitreous body appear in the field of view of the microscope. Further, by focusing the microscope to different depths, one can examine different parts of the vitreous body. An inexperienced ophthalmologist should be recommended to master the technique of vitreous biomicroscopy in an aphakic eye.

Retina, optic disc, choroidea

Biomicroscopy of the retina, optic nerve head and choroid, as clinical observation experience shows, is an extremely valuable additional method for examining an eye patient. This method significantly expands the capabilities of

ophthalmoscopic diagnostics. It allows you to identify and study in detail a number of changes, sometimes completely elusive during ophthalmoscopy using a mirror, electric and large non-reflex ophthalmoscopes.

Fundus biomicroscopy enriches our understanding of some of the most common and serious diseases of the inner membranes of the eye, allows us to more accurately substantiate the diagnosis, and, therefore, ensures the choice of the correct rational therapy. Even in the recent past, just a few years ago, fundus biomicroscopy presented great difficulties. This was due to the lack of necessary domestic equipment.

As experience with the ShchL-56 lamp shows, the process of biomicroscopy of the retina, optic nerve head and choroid must be carried out in a certain sequence, observing a number of technical requirements.

Examination of the fundus should be started only after sufficient practical mastery of the elements of microscopy of the living eye. In each case, a biomicroscopic examination must be preceded by a thorough ophthalmoscopy, during which the location of the pathological focus on the fundus should be clearly recorded, which ensures its quickest location under the slit lamp microscope. To create greater lighting contrast, especially necessary for fundus biomicroscopy, the room should be well darkened; however, there should not be absolute darkness, as this makes it difficult to control the slit lamp and observe the patient.

A necessary condition for high-quality biomicroscopy of the fundus is also the maximum medicinal dilation of the pupil and the presence of transparent optical media of the eye being examined. During the examination, the patient's eye should remain motionless. For this purpose, you can use luminous red dot markings located on the sides of the facial unit of the slit lamp. The patient's gaze is directed in a certain direction to one of the luminous fixation points, which, depending on the need, during the examination of the fundus, can be moved in different directions. The illuminator and slit lamp microscope must be set at zero biomicroscopy angle.

Ophthalmoscopic diverging lens - lower the attachment down. It is necessary to ensure that the lens is positioned exactly opposite the pupil of the eye being examined, otherwise, it will not perform the function of neutralizing the diopter apparatus of the eye. A di-

verging lens provides a direct stereoscopic image of the fundus of the eye in the field of view of a binocular microscope. The focus of the illuminator and microscope is aimed at the fundus of the eye by moving the handle of the coordinate stage. It is recommended to carry out more careful focusing at low (about 5X) magnification of the microscope. Image clarity should be achieved not only by the translational movement of the coordinate stage handle but also by rotating the microscope's focus screw. However, as many years of practice have shown, this method of biomicroophthalmoscopy cannot satisfy the requirements of ophthalmologists. The Hruby lens significantly limits the size of the microscope's field of view and in order to examine even the most central parts of the fundus, it is necessary to move the examinee's gaze. In patients with high-degree myopia, fundus examination is often challenging due to the difficulty in neutralizing the eye's optical system.

While working with the ophthalmoscopic attachment to the slit lamp, we also encountered other design shortcomings. In particular, the magnifying glass, which is moved together with the upper part of the coordinate table, sometimes rests on the facial device or the eye of the subject, not giving a clear image of the fundus.

In this case, you have to pull the handle of the magnifying glass towards you. The indicated disadvantages of the ophthalmoscopic lens and the associated difficulties in the technique of biomicroscopy of the fundus prompted the improvement and introduction into the ophthalmological practice of another method of biomicroophthalmoscopy (in reverse form). This method was introduced into domestic ophthalmology by Doctor of Medical Sciences, Professor M.M.Krasnov. The author based his proposal on the fundamentally excellent possibilities of microscopic examination of the fundus using the refractive ability of the ocular media. To do this, a positive lens with a power of 50.0 D was placed between the eye being examined and the slit lamp microscope. In this case, a reverse image of the fundus was obtained as with conventional ophthalmoscopy using a mirror ophthalmoscope. The same principle underlies the creation of a positive ophthalmoscopic attachment for the SLT lamp.

We have significantly simplified the examination procedure by using two +20 OD magnifying glasses, folded and secured in a

common holder, during reverse biomicrophthalmoscopy.

These magnifying glasses are available in every unit of a regular mirror ophthalmoscope and are usually not used by ophthalmologists for their intended purpose. The commercially available moon of Gartiak with a power of + 40.OD (10 times magnification) has proven itself in use as a positive lens.

The image of the fundus obtained using positive magnifying glasses turned out to be of higher quality than when using the method of neutralizing the optical system of the eye with a minus lens, and the field of view was wider.

The examination is carried out in the following sequence. Having created a zero angle of biomicroscopy and having made sure that the beam of light is directed at the pupil area of the eye being examined, the doctor moves the coordinate table as close to himself as possible (to the edge of the instrument table). After this, having checked whether the light has shifted from the pupillary zone, the doctor takes a positive magnifying glass in his left hand, fixing it with the thumb and index finger by the frame and resting with the other fingers on the upper part of the facial mount. Having brought the magnifying glass closer to the eye of the person being examined, the doctor gradually moves it towards himself, finding at the same time under the microscope an image of the fundus, located in the air at the focus of the magnifying glass. The image is real and inverted. It is better to search for an image of the fundus with a wide illumination slit, therefore, at the beginning of the examination, the diaphragm of the illuminator should be widened and then narrowed.

Technical difficulties in mastering this method of examination are easily overcome even by novice ophthalmologists and are fully compensated by the advantages that this method provides. The examiner does not experience any difficulties in focusing the illuminator and microscope and obtains a clear image of the fundus of the eye in patients with any refraction. At first, it is advisable to examine the fundus with a wide illumination slit, using diffuse illumination, and then proceed to more detailed biomicroscopy. During the examination, if necessary, diffuse, direct focal, indirect and oscillatory illumination can be used. In case of retinal detachment, an examination can be carried out in transmitted light. The choroid serves as a reflective screen.

The use of direct focal illumination allows for the examination of the retina, optic nerve head and choroid in optical section, which makes it possible to judge the depth of localization of the pathological focus, i.e. to correctly determine the tissue where the disease process is occurring, thereby performing topical diagnostics. Obtaining an optical section of the indicated membranes does not present any difficulties.

After examining the fundus in diffuse light with a wide illumination slit, it is usually narrowed as much as possible, and the light beam is focused in the tissues at different depths by moving the handle of the coordinate table. Concentration of the focal beam of light in different planes of the fundus allows cutting out an optical section of the retina, optic nerve disc and choroid. The foci of the illuminator and the microscope must necessarily coincide.

When examining the fundus membranes using indirect illumination, the foci of the illuminator and microscope are not aligned. This type of illumination should be used in cases where differential diagnostics is required between a tumor and cystic formations of the fundus membranes. This creates a kind of diaphanoscopic illumination of the tissue being examined by rays reflected from the focally illuminated area of the fundus.

This type of illumination is especially convenient when examining a neoplasm localized in the area of the posterior parts of the eyeball, since with such localization it is not possible to use conventional diaphanoscopy through the sclera (excluding the method of blood diaphanoscopy). The illumination slit for this type of examination should not be too narrow. Transmitted light examination can be used, as indicated above, to examine a detached retina. The foci of the illuminator and the microscope do not coincide: the first is directed through the retina and subretinal fluid to the vascular membrane, and the second is directed to the retina. With this type of illumination, areas of thinning and cystic degeneration of the tissue are clearly visible in the detached retina. The sites of ruptures are especially prominent. Any degree of microscope magnification can be used for examining the fundus - from 5 to 60 times, but 18- and 35-fold magnification should be considered the most optimal.

Chapter 3

CLINICAL SIGNIFICANCE OF CATARACT BIOMICROSCOPY

The lens is the most important optical medium of the eye, providing a concentration of light rays in focus on the retina, which provides clear vision at various distances.

A violation of the transparency of the lens - cataract - can cause a decrease in visual functions. Therefore, early diagnosis of lens opacities is very important for the timely appointment of appropriate treatment.

This issue has attracted and continues to attract the attention of ophthalmologists.

Biomicroscopy ensures timely recognition of lens opacity. This method allows diagnosing cataracts at the earliest stage of their development, even when the patient himself does not yet notice any visual impairments and does not complain of decreased vision.

Biomicroscopy of the lens usually allows not only to notice cataract changes in time, but also to monitor the development of cataracts, to establish the possible time of surgical intervention. Based on biomicroscopic studies, the surgeon can currently choose the most rational method of cataract extraction for each patient individually.

Since among cataracts the most common are acquired lens opacities, we will touch upon the biomicroscopic characteristics of acquired cataracts, in particular senile cataracts.

Senile cataracts can manifest themselves in three clinical forms: cortical, nuclear, subcapsular.

Numerous observations show that this division is possible only in the early stages of cataract development, depending on the zone of the lens in which the first cataractous changes appeared. Later, as the cataract matures, when the opacity gradually spreads to the entire substance of the lens, accurate diagnosis of the clinical form of cataract is not so easy.

The use of a vitamin complex, iodine preparations and cysteine therapy is advisable precisely at the stage of early changes in the lens, when there is still no degeneration of the lens fibers and capsular epithelium.

Prescribing conservative therapy when clouding and disintegration of the lens substance has already begun is less successful.

Many ophthalmologists are aware of the fact that the initial cataract changes the type and degree of refraction of the eye, which leads

to a decrease in farsightedness and the appearance of myopia in some cases. Some patients begin to use weaker glasses for reading, and in some cases do without them at all. This circumstance is associated with a violation of the water exchange of the lens, retention of intraocular fluid in it, and swelling of the lens substance.

The process of hydration* of the lens is not always expressed to such a degree as to cause a change in the refraction of the eye. Meanwhile, signs of hydration of the lens are a sure symptom of the precataract period. Based on the above, it becomes clear that a wide circle of practicing ophthalmologists needs to become familiar with other, more reliable, more objective symptoms indicating the possible development of cataracts.

In senile cortical cataracts, the moisture retained in the lens is distributed in the cortical layer of the lens. It finds a place between the individual zones of the lens substance, distributing itself according to the location of the sutures of the cortex. Thus, a symptom appears that is called the symptom of water cracks or the symptom of gaping sutures of the cortex.

When examined in diffuse light, the aqueous fissures in the anterior cortex appear as dark radial stripes. The dark color of the aqueous fissures is due to their lower optical density, since the moisture that fills and expands the sutures has a significantly lower refractive index than the surrounding lens substance.

By analogy with the anterior cortical layer, the same process of formation of water gaps also occurs in the posterior cortical layer.

When examined in transmitted light, the aqueous fissures appear completely transparent. In direct focal light (in an optical section), the aqueous fissures appear as dark, irregularly shaped, sharply limited spaces of a dark color (Fig. 7). Against the background of the gray-blue substance of the lens, they have the appearance of voids.

Moving a beam of light in a horizontal direction produces a series of sections through the aqueous slit. The slits have different sagittal thicknesses. Some of them can extend over the thickness of the entire cortex, extending from the surface of the adult nucleus to the zone of lens detachment.

The aqueous slits usually never reach the surface of the capsule. They are most often localized in the middle and deep sections of the cortex. The aqueous slits in the area of the posterior cortex are not visible under diffuse illumination.

They are revealed only during examination in direct focal light, in the optical section of the lens. In their location and appearance, they are no different from the slits in the area of the anterior cortex.



Fig. 7. **Aqueous slits of the lens (optical section)**

Over time, the transparent contents of both slits begin to cloud. The slits are filled with small grayish inclusions, and their walls also become cloudy. The clouding process does not immediately affect the entire aqueous slit. Sometimes one can see how the transparent section of the slit turns into its already cloudy part. At this stage of development, the clouded aqueous slits become distinguishable when examined with an ophthalmoscope in transmitted light. They look like delicate radial opacities, appearing along the periphery of the dilated pupil in the form of spokes. In rare cases, the development of aqueous fissures occurs without cataracts and in the absence of them in the future.

The second pre-cataract symptom, which is an expression of more active saturation of the cortex with water, can be considered the separation of the plates and fibers of the lens substance by moisture. These changes are called the symptoms of dissociation of the lens cortex (Fig. 8).

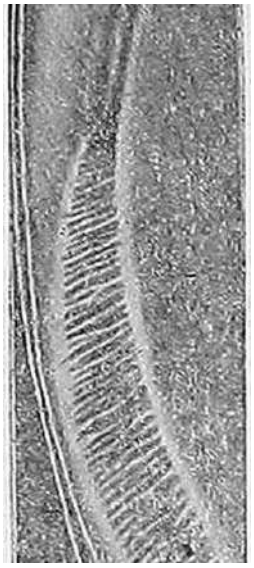

Fig. 8. **Dissociation of the lens cortex (optical section)**

The separation of the plates is recognized by the presence of parallel dark lines, usually located concentrically to the equator of the lens. The dark spaces, which are narrow water gaps, alternate with grayish opalescent layers related to the substance of the lens.

The separation of the lens plates is observed mainly in the deep and middle sections of the cortex. According to some authors, the separation of the plates in the anterior cortex occurs three times more often than in the posterior cortex. We think that the process of cortex dissociation occurs uniformly in both the anterior and posterior sections of the latter, but it is more difficult to see the posterior cortex, which is why the symptom of lens substance dissociation is less frequently observed there.

It should be said that when examining an optical section with a narrow slit, we were always able to quite well distinguish the separated plates and fibers of the lens in the area of the posterior sections of the cortex.

These changes are best seen when the focus of the illuminator is directed at the posterior surface of the adult nucleus.

Symptoms that indicate hydration of the lens include the formation of subcapsular vacuoles in it.

Senile cortical cataract most often develops in the form of a wedge-shaped cataract. During its development, it goes through several stages of maturation.

The diagnosis of incipient wedge-shaped cortical cataracts is made when the radial aqueous fissures and the lens fibers located in their circumference become cloudy.

Later, larger, specially shaped zones of cloudiness are formed, located in the middle and deep sections of the cortex concentrically to the equator of the lens (mainly in the lower zones of the lens).

The central parts of these opacities have elongated, jagged or slightly rounded edges. The process spreads simultaneously in the anterior and posterior cortical layers.

Since the optical section of the lens is positioned at a certain angle to the microscope axis when examined in direct focal light, it is possible to simultaneously examine both the anterior and posterior zones of opacity. They have the form of gray-white "riders" located on both sides of the adult nucleus.

When examined in transmitted light, the opacities overlap one another, making it impossible to see them separately. In addition, under such lighting, the opacities acquire a yellowish or even slightly brownish color due to the additional color from the sclerotic nucleus of the lens.

As the opacification progresses further, an immature cataract develops. It is characterized by the advancement of opacities toward the anterior and posterior capsules of the lens. The merged zones of opacities give the cortex a mottled appearance.

Along with the areas of opacity, gaping aqueous fissures and subcapsular vacuoles are visible. The alternation of swelling fibers of the lens with hydration zones sometimes gives the lens a peculiar pearlescent shine. In immature cortical cataracts, the subcapsular fibers of the lens are transparent. This explains one of the most typical biomicroscopic signs of immature cataracts—the presence of a dark (transparent) space between the cataract-altered cortex and the lens capsule.

The transparent layer of the lens represents the youngest subcapsular portion of the lens fibers.

When examining an immature cataract in direct focal light, only the beginning of the optical section of the lens can be seen; all other grayish sections are hidden in the fog. The posterior surface of the optical section and the area of the transparent cortex adjacent to the posterior capsule of the lens become indistinguishable since light rays penetrate with difficulty through the area of the cloudy cortex and sclerotic nucleus of the lens.

If the hydration and swelling of the lens substance become excessively active, this may lead to an increase in intraocular pressure and trigger an acute episode of secondary glaucoma. This type of glaucoma is called phacomorphic.

Biochemical processes in the lens are very complex and have not been fully studied. A certain composition of ions is always maintained inside the lens, which differs from the composition of the ions of the surrounding liquid. It has been proven that the lens capsule is permeable to water and substances with a small molecular weight. In living cells, a state of dynamic equilibrium between potassium and sodium is observed. If the formation of chemical energy decreases or stops, then the active movement of ions is interrupted. Potassium ions leave the cells, and sodium ions, which are usually in the intercellular space, enter the cells. The disruption of potassium and sodium metabolism inside the lens is accompanied by an increase in the amount of moisture in it. The passage of moisture through the capsule changes so that more of it enters the lens than the lens fibers can absorb. As a result, the lens swells, sharply increases in size, the angle of the anterior chamber is compressed, the outflow of intraocular fluid is disrupted, which leads to the development of an

acute attack of phacomorphic glaucoma with characteristic clinical manifestations.

The following clinical picture is observed: congestive injection of the eyeball, corneal edema, a shallow anterior chamber (sometimes slit-like), the iris is thinned and discolored, its trabeculae are smoothed, the stroma is stretched. The posterior pigment layer of the iris and the stretched sphincter of the pupil shine through the rarefied stroma, the pigment border of the pupil is partially or completely destroyed. The pupil is wide, often has an irregular shape and does not react to light. Sometimes the development of pronounced focal atrophy of the iris is observed. The lens is unevenly turbid. Biomicroscopically, it shows pronounced symptoms of hydration, dissociation of the plates, water gaps, and a pearly sheen to the nucleus (Fig. 9).

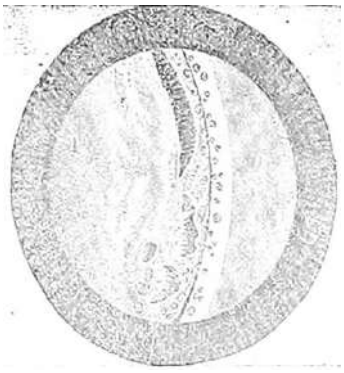

Fig. 9. **Immature cataract. Symptoms of lens hydration. Phacomorphic glaucoma**

There is no reflex from the fundus. In these cases, histomicroscopically it is possible to detect that the apex of the angle of the anterior chamber is blocked by the root of the iris. The depth of the anterior chamber varies in accordance with the degree of swelling (hydration) of the lens, its increase in size and displacement forward, sometimes close to the cornea, which is undoubtedly facilitated by dystrophy, weakening and rupture of the zonular ligaments.

At the same time, the intertrabecular spaces and the lumen of the Schlemm's canal in such eyes are clogged with tissue detritus and pigment slag; the contours of the canal are sometimes barely discernible (Fig. 10).

When the cataract is fully mature, the entire cortex of the lens becomes cloudy, accompanied by a process of cortex dehydration. The number and size of the aqueous fissures decrease. The clouding of the lens becomes more gray-white, becomes homogeneous, and reaches the capsule.

The presence of a mature cataract is determined by the absence of an optical section of the lens since a completely clouded lens substance reflects the rays of light falling on it.



Fig. 10. **Pathohistological changes in phacomorphic glaucoma (anterior chamber angle is closed) Hematoxylin and eosin staining, magnification 10x6.3**

Determining the degree of maturity of a cataract in the light of a slit lamp is of great importance for determining the time of the operation - cataract extraction, as well as for choosing the method of cataract extraction.

The presence of even a narrow translucent band of lens substance, water slits and subcapsular vacuoles indicates that the cataract is not fully mature. Cataracts where the lens hydration process has not yet ended are characterized, as surgical experience shows, by pronounced tension in the lens capsule. This sometimes leads to undesirable complications during cataract extraction.

Intracapsular removal of the lens in such cases is not always successful. In extracapsular extraction of an incompletely mature cataract, the surgeon must remember the significant amount of residual translucent lens masses and be prepared to remove them by thoroughly rinsing the anterior chamber with saline.

In the presence of a mature cataract, when the lens capsule is relaxed and the lens material appears completely opaque, intracapsular cataract extraction tends to proceed more smoothly. If the operation is performed extracapsularly, the removal of a small amount of fully opaque lens material generally does not pose significant difficulty for the surgeon.

With rapid overripening, the cortex and, to some extent, the lens nucleus liquefy. Lens proteins disintegrate into amino acids, the number of molecules increases, osmotic pressure increases, moisture enters the lens, the lens substance dissolves, it becomes homogeneous, milky in appearance (milk cataract).

The lens, as a result, increases in volume, blocks the angle of the anterior chamber, which leads to an increase in intraocular pressure. The clinical picture in this case: congestive injection of the eyeball, corneal edema, the anterior chamber is shallow, the pupil is wide, does not react to light. Significantly

pronounced depigmentation of the pupillary border and the posterior pigment sheet of the iris is noted. The stroma is affected by the dystrophic process much less. The lens is milky white, biomicroscopically homogeneous; sometimes in the cortex salt crystals are visible, shimmering with the colors of the rainbow.

With a slow process of cataract over-maturation, the cortical layer of the lens is mainly liquefied, and at the same time, its resorption begins.

The first, most constant sign of cataract over-maturation in this type, according to our observations, should be considered the appearance of folds in the lens capsule, which indicates liquefaction of the cortical substance.

When examined with a slit lamp in transmitted light, the folds of the anterior capsule of the lens have the appearance of double, sometimes branching reflexes, reminiscent of the folds of Descemet's membrane. They are distinguished by a wide variety of directions, sometimes crossing the entire pupil.

Along with the folds of the anterior capsule of the lens, the folds of the posterior capsule also appear. However, the posterior folds are usually not visible due to the complete opacity of the cortex.

The cortex itself acquires a uniformly homogeneous appearance and a peculiar milky-white shade. With complete liquefaction of the cortex, the nucleus of the lens sinks downwards due to gravity. A well-known type of Morgagni cataract develops.

Biomicroscopic examination in this case reveals a peculiar picture. The lens section becomes uneven in thickness. In the upper sections, it is significantly narrower and consists of two sheets of the lens capsule, separated by a layer of translucent cloudy cortex.

In the lower sections, corresponding to the location of the descended nucleus of the lens, the optical section becomes significantly thicker.

Through the liquefied masses of the lens, the nucleus shines through as a fairly clearly outlined rounded yellowish inclusion.

A rare biomicroscopic sign of overripe cataracts is the deposition of crystals in the cortex, which are most likely calcium and cholesterol elements. Crystalline inclusions are usually needle-like and shimmer with all the colors of the rainbow. The process of overripe cataracts is

usually accompanied by degenerative changes in the cyan ligament, which leads to phacodonesis and iridodonesis.

When the breakdown products of the lens substance penetrate through the lens capsule into the surrounding space, phacogenetic iritis and phacolytic glaucoma may occur.

Glaucoma in hypermature cataracts is aptly called phacolytic, since it is associated with leakage of liquefied lens substance through the capsule. The products of lens decay penetrate through the capsule into the anterior chamber, are captured by macrophages and clog the trabecular apparatus of the anterior chamber angle, resulting in an acute attack of glaucoma.

In this case, the following clinical picture is observed: congestive injection of the eyeball, corneal edema, the anterior chamber is often deep or of medium depth, the pupil is usually moderately dilated and weakly reacts to light, pronounced depigmentation of the pupillary border and the pigment sheet of the iris.

Biomicroscopy of the lens reveals folds in its capsule, the cortex is liquefied, homogeneous in appearance, and the nucleus is lowered (Fig. 11). As stated above, salt crystals often shimmer like a rainbow in the cortex. A suspension of such crystals can also be observed in the fluid of the anterior chamber, which masks the pattern of the iris.

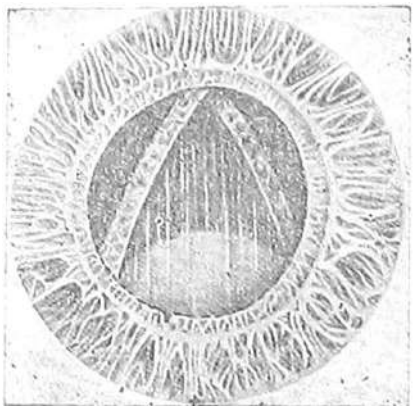

Fig. 11. **Hypermature cataract. Phacolytic glaucoma**

Histomicroscopic examination of eyes enucleated due to terminal phacolytic glaucoma reveals acute phenomena caused by the attack.

They are available in the presence of a deep anterior chamber, a wide chamber angle due to the displacement of the iris posteriorly. In the lens, the now-swollen structural core is well differentiated and surrounded by emulsified cortical material.

The lens masses are also determined in the anterior and posterior chambers of the eye, which is

associated with the destruction and rupture of the lens capsule. The same cortical masses fill the apex of the chamber angle, blocking it (Fig. 12). Macrophages are present here in large quantities.

Along with histomicroscopic changes characteristic of phacomorphic and phacolitic glaucoma which explain the pathogenesis of these conditions, cicatrical changes are established in the shell and other tissue structures of the eye, and the picture is characterized by a sharp attack of glaucoma (taking into account the time of its existence).

Based on the age of the patients (60-90 years), the changes detected should be assessed as geriatric tissue disorders. It is possible that these changes precede the cataract process or develop in parallel with it. From the above, we can conclude that the attack of phacogenic glaucoma is superimposed on a certain preceding background, and the resulting acute decompensation of ophthalmotonus is not only a consequence of the peculiarities of cataract maturation but also a complex of preceding age-related changes in the eye tissues. Frequent lack of effect from intensive hypotensive and distracting therapy, which mainly relieves acute vascular phenomena and helps eliminate the block of the chamber angle, is evidence of the presence of preceding changes in the eye.

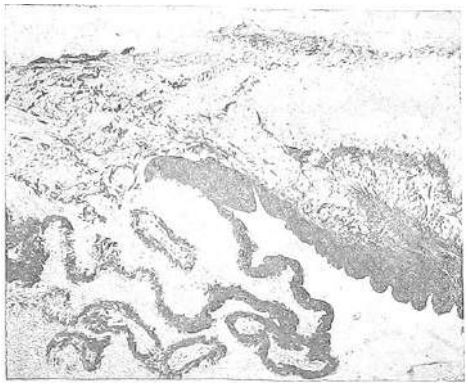

Fig. 12. **Pathohistological changes in phacolytic glaucoma (the anterior chamber angle is open, filled with lens masses, exudate). Hematoxylin and eosin staining, magnification 10x6.3**

The complex of these changes undoubtedly remains even after successful relief of an acute attack of phacogenic glaucoma by extraction of the cloudy lens. It can also be aggravated by the reparative postoperative process. This justifies the recommendation of careful monitoring of the patient who underwent surgery in the long term and also justifies the combination

of cataract extraction surgery with antiglaucoma intervention.

The conducted studies have convinced us of the necessity to recommend regular tonometry during outpatient care of cataract patients for the prevention of glaucoma associated with the maturation process of senile cataracts. Ophthalmologists should pay attention to biomicroscopic symptoms that predetermine the possibility of developing phacomorphic and phacolytic glaucoma.

In phacomorphic glaucoma, there is a possible shrinkage of the anterior chamber as a result of pronounced hydration of the lens cortex.

This is also evidenced by multiple aqueous fissures, subcapsular vacuoles in the lens. Such patients benefit from prophylactic administration of a 1% solution of pilocarpine in the form of instillations; patients should be warned that in the event of severe pain in the eye, redness of the eye, they should immediately seek help (and not in the eye office of the polyclinic, but in the on-duty eye hospital). Such a patient needs urgent hospitalization for emergency care.

He will be prescribed distracting, hypotensive drugs (glycerol, diacarb, magnesium sulfate leaks on the temple, hot foot baths, analgetics) and then surgery is necessary. Practical doctors should know that in the case of stooping to an acute attack of phacomorphic glaucoma the patient should not be discharged from the hospital. He needs (against the background of normal numbers of ophthalmotonus) in mandatory sugical treatment-cataract extraction.

Experience shows that if a patient is discharged from the hospital without surgical treatment, he will soon have to be hospitalized again due to a repeated attack of ophthalmotonus decompensation. In this case, surgical intervention is fraught with complications and a worse outcome, in particular, due to irreversible changes in the optic nerve associated with long-term increased intraocular pressure and ischemia of the nervous tissue. As for the prevention of phacolytic glaucoma, this issue is resolved more easily. All patients in the process of maturation of senile cataracts should be under dispensary observation, and the fact of maturity of the cataract, in the absence of general somatic contraindications, should serve as the basis for referring the patient for surgical treat-

ment. When the first symptoms of overripening of the cataract appear in the form of homogenization and liquefaction of the cloudy cortex, the appearance of folds in the lens capsule, the patient must be immediately referred for cataract extraction.

In case of refusal of surgical treatment, the patient should be warned of the possibility of the pain syndrome, which will require urgent hospitalization. Cupping of the acute attack of phacolytic glaucoma with a medication doesn't serve as a basis for abstinence from surgery: the acute attack of glaucoma will arise again and the operation will have to be performed but against the background of a more complex clinical picture with a worse outcome: it will be more difficult to restore visual functions and normalize intraocular pressure.

All patients with developed attacks of phacogenic glaucoma must be urgently hospitalized and undergo pathogenetically oriented cataract extraction surgery without delay. In acute attacks of secondary phacogenic glaucoma in patients with immature or hypermature cataracts, infinitely small visual acuity with incorrect light projection should not serve as a contraindication to cataract extraction surgery. Phacotoxic iridocyclitis is also not a contraindication to surgery.

After surgery, patients should be under dispensary observation, since in the long term they may experience a violation of the regulation of intraocular pressure, which is associated with a complex of geriatric and postoperative changes in the angle of the anterior chamber.

Based on the facts based on clinical observations and gnetomicroscopic changes in tissues enucleated due to phacogenic glaucoma of the eye, it is advisable to include an anti-glaucoma component in the form of sinus trabeculectomy in the cataract extraction operation. This is especially true for advanced cases of phacogenic glaucomas and for those cases where phacogenic glaucomas are superimposed on the primary glaucomatous complex.

Let us present a biomicroscopic characteristic of the following types of acquired age-related cataracts.

Nuclear cataract is a rather rare form of senile cataract. Much more often we have to observe mixed forms of nuclear-cortical or nuclear-subcapsular cataracts, when, in addition to the opacity of the adult nucleus zone, there are diffuse,

point, striped, or lamellar opacities of the cortex around the nucleus or in the subcapsular parts of the lens. These processes can occur both in parallel and in a certain sequence when cortical changes join the initial opacity of the nucleus.

In nuclear cataracts not accompanied by changes in the cortex, symptoms of lens hydration, gaping of the cortex sutures, and dissociation of the lens substance are usually absent. This is due to the fact that the above-mentioned pre-cataract changes develop only in the non-sclerotic parts of the lens, while nuclear cataracts occur in the densest, most sclerotic part of the lens.

The first opacities in nuclear cataracts appear in the internal embryonic nucleus. The posterior half of the nucleus is always opaquer than the anterior. The central space remains transparent for a relatively long time. Over time, the central opacities spread in all directions, involving the outer surface of the embryonic nucleus.

Between the opaque embryonic nucleus and the surface of the senile nucleus, a transparent zone is initially visible, but eventually the central opacity merges with the zone of the adult nucleus. The entire opaque nucleus is separated quite sharply from the transparent cortex.

The opacity in nuclear cataracts is homogeneous and diffuse. This distinguishes it from the opacity of the cortex. The diffuseness and homogeneity of the opacity allow, even in the case of a pronounced nuclear cataract, to penetrate into the depth of the lens using direct focal illumination, to see the posterior surfaces of the senile nucleus and the lens. In cases where opacity of the cortex is added, this can no longer be done. Nuclear cataract is also characterized by the absence of disintegration of the lens substance.

In practical work, it is often necessary to carry out differential diagnosis between the initial manifestations of nuclear cataracts and crystalline lens sclerosis. In both cases, only a slight decrease in vision is observed with a decrease in the intensity of the red reflex from the fundus.

During biomicroscopy, in order to differentiate the above phenomena, it is advisable to pay attention to the color of the nuclear zone and the state of the embryonic sutures of the lens. In the case of nuclear cataracts, a gray-white col-

oration of the internal parts of the lens and clouding of the embryonic sutures are observed.

In the case of sclerosis of the lens, the nucleus acquires a yellowish tint, and the sutures do not change their appearance.

Subcapsular senile cataract belongs to the category of very early and intensively reducing vision. Like cortical cataracts, the subcapsular form of lens opacity begins with the appearance of symptoms of hydration, which, as a rule, precede the development of true lens opacities.

This form of cataract is characterized by the appearance of subcapsular vacuoles. They, like water slits, are a unique expression of lens hydration. Vacuoles are usually easily detected when examined in transmitted light. They look like round, transparent cavities resembling honeycombs and sometimes occupy the entire subcapsular zone. Most often, vacuoles develop under the anterior capsule of the lens.

A study in direct focal light confirms the complete transparency of the vacuoles, which give a unique reflex and are clearly visible.

Subcapsular senile cataracts may appear under the anterior and posterior capsules. However, the latter localization is more common. This should be remembered when conducting differential diagnostics between posterior subcapsular senile and complicated cataracts.

The early stage of subcapsular cataracts is characterized by the appearance of delicate, point-like, and sometimes larger, granular, grayish opacities under the lens capsule (usually the posterior one), alternating with subcapsular vacuoles. This gives the entire opacification a peculiar mesh-like appearance when examined in diffuse light (Fig. 13a). The changes are usually localized in the circumference of the posterior pole of the lens.

They are clearly visible in the optical section of the lens at the posterior edge (Fig. 13 b).

Later, as the cataract progresses, the opacities spread radially toward the equatorial portion of the lens. At this stage, when examined in diffuse light, the posterior subcapsular cataract takes on a cup-shaped appearance.

A characteristic symptom of this cataract, which distinguishes it from complicated cataracts, is that the opacities and vacuoles in the initial stage of the process are located in one or two subcapsular layers and are sharply delimited

from the transparent cortex lying in front of them. An isolated type of subcapsular cataract is rare. More often, one has to observe a combination of this type of opacification with opacification of the nuclear or cortical part of the lens.

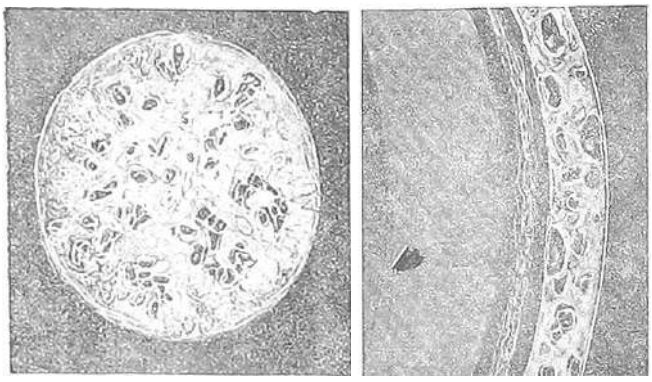

a b

Fig. 13. **Initial subcapsular cataract: a — diffuse swathe; b — optical section**

Recently an ophthalmologist more often has to meet with cataracts of a complicated type that occur as a result of exposure to the lens of tissue metabolism toxic products. These cataracts include the lens opacity in diabetes mellitus which according to the various authors develops in 2-62% of diabetes mellitus cases.

Such conflicting information about the cataract frequency in diabetes is associated with different levels of diagnostic capabilities of the authors and the fact that some take into account all kinds of lens opacity detected in patients with diabetes and others take into account only diabetic cataracts.

In diabetes, certain clinical types of lens opacity can be distinguished. These are senile cataracts, the classic type of diabetic cataracts, and a mixed form that includes elements of senile lens opacity with the addition of symptoms of diabetic cataracts. The clinical type of senile cataracts is the most common and, according to our data (diagnosis by biomicroscopy), occurs in 82% of cases in patients with diabetes mellitus.

This cataract occurs several times more often in diabetes and at a younger age (40-50 years) and is

characterized by active progression. Cataracts also come in three types: subcapsular, nuclear, and cortical.

The clinical picture of true complicated diabetic cataracts, according to our observations, occurs in only 2% of cases. It has its own distinctive features. This cataract mostly occurs in young people, teenagers, and children with severe diabetes. The process develops, as a rule, almost simultaneously in both eyes and is characterized by very rapid progression (not months and years, as in senile cataracts arising against the background of diabetes, but weeks, days, and even hours).

A precursor to cataracts may be the appearance and rapid progression of myopia, which can be associated with active hydration of the lens, leading to increased refraction. The patient complains of decreased distance vision. Minus optical correction clearly improves vision, and with appropriate corrective glasses, it remains normal. Objective examination of the lens, particularly via biomicroscopy, reveals no detectable opacities, although signs of cortical substance displacement are clearly evident.

Changes (subcapsular vacuoles, aqueous slits) are localized in the superficial layers of the lens and occupy both the anterior and posterior zones of detachment (the process is usually more pronounced at the back). Soon, under both capsules of the lens, gray opacities in the form of flakes, streaks, and dots appear around the hydration zones. They merge into a cloudy mass of a motley appearance, spreading to the central sections of the lens (Fig. 14). The lens areas are expressed fuzzily, the anterior chamber becomes clearly smaller. With a violent hydration of the lens an acute attack of secondary phakomorphic glaucoma may occur.

The mixed clinical type of cataract in diabetes initially develops as one of the variants of senile cataract with the addition at some stage of maturation of signs of true diabetic cataract, which is usually combined with a deterioration in the general course of diabetes.

The statement of pre-cataractal or initial cataractal changes obliges an ophthalmologist to take certain measures. If any of the listed symptoms are detected in the patient, it is necessary to perform a blood sugar test and an examination of urinary sugar from the daily urine output.

Examination for diabetes is preferable in all patients with cataracts because with senile cataract hyperglycemia is often detected. The human lens contains 52 mg % of glucose.

It penetrates the substance of the lens through the capsule since the latter has permeability from the outside to the inside for glucose. In the lens the glucose oxidizes freeing energy that is the main source of life for the lens.

Hormones of the endocrine glands, particularly insulin, affect the permeability of the lens capsule. Insulin deficiency in the body, causing a disruption of general carbohydrate metabolism, undoubtedly, along with other pathogenetic factors, changes the lens metabolism, despite a certain automatism of its vital activity (it is known that the lens itself synthesizes its proteins and performs liver and kidney functions).

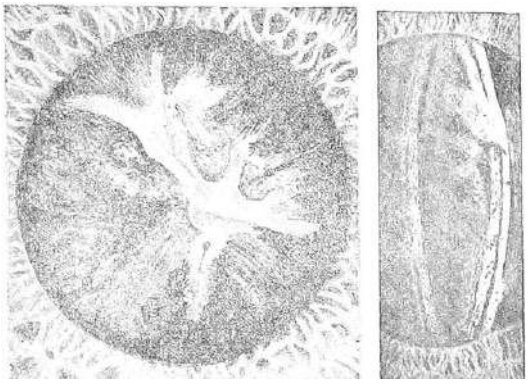

Fig. 14. **Diabetic cataract:**
a - diffuse light; b - optical section

Cases of regression and even the complete disappearance of diabetic cataracts under the influence of insulin therapy once again convince us of the pathogenetic role of carbohydrate metabolism disorders in cataracts. Cataract surgery, pursuing the radical goal of eliminating the clouded lens, does not always lead to the desired result.

After extracapsular cataract extraction, even with the modern level of microsurgical technology (and in particular, the use of phacoemulsification), the secondary cataract may develop.

Intravital microscopy of the cataract film allows differential diagnostics between the true secondary cataract and other forms of opacification related to the category of false secondary cataracts, which is of enormous importance when deciding on the tactics for treating the patient.

Slit lamp examination of secondary cataracts helps to make an informed and correct choice of the method of its removal.

In numerous studies of patients with secondary cataracts, we have observed the following, most constant biomicroscopic signs of this disease. When examined in the optical section, the film of secondary cataracts is multilayered and consists of several ingredients. The thickness of the film is uneven. It is possible to distinguish the anterior and posterior leaflets of the lens capsule.

The posterior leaflet of the capsule is a very delicate, thin and completely transparent membrane. In some cases, it is slightly folded, which can apparently be associated with tension from the fibers of the zonule and individual adhesions of the capsule to the pupillary edge of the iris.

With a dilated pupil, the remains of the anterior capsule are often visible. It is located parallel to the posterior capsular leaflet and is partially fused with it. In the anterior capsule, corresponding to the central parts of the cataractous film, there is usually an opening. Between the leaves of the anterior and posterior capsule, one can often see shapeless, gray, organized masses of the lens.

In cases where the anterior capsule, at the site of its integrity violation (incision, tearing out), is adjacent to the posterior capsule of the lens and adheres to it, the resorption of the lens masses not removed during the operation is very slow and sometimes does not occur at all. This is due to the fact that the cataract masses enclosed between the capsule layers are completely isolated from the chamber moisture and its proteolytic influence.

This type of cataract, where residual, organized elements of the lens prevail, can be called residual secondary cataract. According to our observations, this cataract occurs mainly in elderly people. When examining the secondary cataract film in the light of a slit lamp, it can often be seen that its main component is newly formed lens fibers.

Since part of the anterior capsule is left during extracapsular cataract extraction, it is natural that the subcapsular epithelium, which

under normal conditions ensures the growth of lens fibers, also remains with it. After cataract extraction, the epithelium of the anterior capsule continues to function. It continues to multiply and form lens fibers. At first, the fibers are located between the layers of the capsule, and then gradually tighten all the "windows" formed in the anterior bag of the lens during cataract extraction.

Since there are no normal conditions for the growth of newly formed fibers, they acquire an irregular, often tortuous, wavy shape. Contact with intraocular fluid causes the fibers to become cloudy.

This type of regenerative secondary cataract, when the cataract film consists mainly of masses of elongated, tortuous and cloudy fibers, is observed in younger individuals, in whom the regenerative properties of the tissues are expressed to a greater extent.

In young patients, mainly children, another symptom can be seen, which is also a consequence of excessive regeneration of the capsular epithelium. These are the Adamuk-Elschnig balls.

The increasing number of cells of the epithelium of the capsule often undergoes vacuolar degeneration. This occurs due to their retention of chamber moisture. Some cells increase to such an extent that they exceed their previous sizes several times. The cell nucleus is pushed aside and eventually lyses.

Conglomerates of such cells, otherwise called Adamuk-Elschnig pearls, sometimes occupy the entire surface of the cataract film. In places, they extend beyond the pupil and protrude into the anterior chamber.

By their shape, transparency and a peculiar shine the balls of Adamyuk resemble miniature soap bubbles or colonies of frog caviar. Some authors compare them with grapes.

The number of Adamiuk pearls is not constant. Along with the disappearance of individual cells, new cellular elements appear.

Secondary cataracts with the presence of Adamiuk-Elschnig pearls, due to incorrect refraction of light, cause a strong decrease in vision.

Crystalline inclusions shimmering with rainbow colors can sometimes be found in the cataract film. In some cases, significant pigment layers are visible in the secondary cataract film, most often located in the peripheral areas near the pupillary edge of the iris. If the pigmentation sign becomes predominant, then a diagnosis of sec-

ondary pigment cataracts should be made. Pigment inclusions are often star-shaped and form mesh structures. The color of the pigment is light or dark brown. With intense dark pigmentation, the deeper elements of the cataract film are usually not visible.

From the description of secondary cataracts, it follows that its biomicroscopic picture may be different in elderly and younger patients. In the former, the residual component in the form of organized masses of the lens often predominates, while in the latter, regenerative components in the form of newly formed lens fibers and Adamuk-Elschnig pearls prevail.

Some of our patients had nearly every feature typical of secondary cataracts visible when the cataract film was biomicroscopically examined (Fig. 15).

If the secondary cataract develops as a result of the process happening in the residual elements of the lens and isn't fought with the iris, it is classified as a simple secondary glaucoma.

In cases when on the caratactal film or in its circumference traces of inflammation are visible to noticeable fusion of the film with an iris or a ciliary body, such a cataract is called complicated secondary. It is usually thicker and rougher than a simple cataract, which causes significant vision loss.



Fig. 15. **True secondary cataract**

If a secondary cataract develops as a result of a process occurring in the residual elements of the lens and is not fused with the iris, then it is classified as a simple secondary cataract.

True secondary cataracts must be differentiated from false cataracts, which develop as a result of scarring and wrinkling of the anterior border plate of the vitreous body. In some cases, after intracapsular cataract extraction, the vitreous body, due to constant contact with the aqueous humor, begins to change, becomes dense and calloused, which ultimately leads to a decrease in the patient's visual acuity. In these cases, biomicroscopy

does not allow one to see the elements of the lens.

The dense anterior border plate of the vitreous body appears grayish, sometimes reflective. In some cases, pigment deposits are visible on it.

Differential diagnosis of the type of secondary cataract plays a decisive role in choosing the tactics of its surgical removal or the use of laser radiation to create an opening in the cataract film.

Chapter 4

ELEMENTS OF BIOMICROVITREOSCOPY AND OPHTHALMOSCOPY

The importance of biomicroscopic examination of the vitreous body is difficult to overestimate, since, unlike other structures of the eyeball, it is impossible to see the vitreous body normally using conventional examination methods (examination in transmitted light using an ophthalmoscope). An optically empty space appears in front of the examiner, from which it follows that the vitreous body is transparent. As for pathological changes in the vitreous body, the ophthalmologist's capabilities are also very limited here. He cannot, using transmitted light, see the pathological substrate in the vitreous body and is forced to be content with only the ability to analyze the "behavior" of this substrate. Thus, having established the presence of opacity in the vitreous body, there is nothing left to add to this, except how to assess the opacity as diffuse, floating, or fixed.

The above confirms the value of biomicroscopy of the vitreous body, which allows one to examine the tissue elements of the latter both in normal conditions and in pathology. The vitreous body is a colloid-gel by its biochemical nature. It consists of a denser part - colloidal micelles, which form the stroma, or skeleton of the vitreous body, and a semi-liquid jelly-like substance containing up to 98-99% water.

The stroma of the vitreous body is thin intertwining fibers that begin between processes and from a flat part of the ciliary body, permeate the entire jelly-like substance and attach to the internal borderline membrane of the retina in the circle of the optic nerve disc.

The examination of the vitreous body with a slit lamp begins, as mentioned above, with the placement of the focal beam of light on the posterior capsule of the lens. A dark, optically empty retrolental

space is revealed behind the lens. In front, it is limited by the posterior surface of the lens, and behind, by the anterior border plate of the vitreous body. This space can also be seen with phentoscopy. The appearance of the normal vitreous body is very variable and changes with age. However, even in people of the same age and sex, the vitreous body looks different. In some cases, the stromal elements stand out clearly against the background of a dark jelly-like substance, while in others, they are barely noticeable. This depends on the refractive indices of the constituent elements of the vitreous body: if the refractive indices of the vitreous body stroma and its liquid part differ little, then the vitreous body is poorly visible, and vice versa. There are two types of vitreous body stroma: fibrillar and lamellar (pseudomembranous). Both types of structure can be found in structural combinations of the vitreous body.

When examined with a slit lamp, immediately behind the more or less pronounced, slightly shiny anterior limiting membrane, bundles of the vitreous stroma are revealed. They have the appearance of fibrous, parallel, iridescent bands of gray color, which gives the structure of the vitreous body a certain layering. With stronger illumination, fibers running in an oblique direction and crossing the vertical membranes are also visible.

The anterior stromal bundles stand out more prominently since they are coarser and, in addition, are more brightly illuminated. Behind two or three vertically arranged parallel layers of stroma, there is a more delicate and poorly illuminated network of trabeculae, as well as the stroma of the deep sections of the vitreous body, which no longer has a regular layered structure.

When examined in direct focal light, it is clearly visible that the bundles and membranes of the vitreous body stroma alternate with dark, optically empty spaces filled with a gelatinous substance. The latter is, as it were, included in the existing fibrillar framework and moves with it (Fig. 16).

The normal vitreous body is characterized by pendulum-like movements. When the head or eye is turned, the elements of the vitreous body begin to move. After several swinging movements in the direction in which the eye was turned, the vitreous body stops in the position it was in before the movement. At the same time, the previous combinations and relationships of its elements are pre-

served. The stability of the structure of the vitreous body indicates its normal condition. This sign has great diagnostic value.



Fig. 16. **Vitreous body in normal condition**

The vitreous body is an inert, avascular, almost cell-free medium that is incapable of regeneration. Independent diseases of the vitreous body occur extremely rarely. Much more often, it changes as a result of a disease of the surrounding membranes of the eye. In this case, its physicochemical properties are disrupted, which leads to the transformation of the colloidal gel into a sol. This process is accompanied by the formation of opacities, often visible during ophthalmoscopic examination.

It should be remembered that opacities of the vitreous body usually have a black color when examined with an ophthalmoscope, but their true color and shape are revealed with biomicroscopy in direct focal light. Dystrophic (destructive) changes in the vitreous body are most often encountered in practical work.

Let us examine those that can be ascertained (in the early phase of development) only by the biomicroscopy method. Changes in the vitreous body in myopia are the most striking example of this kind of pathology. They occur in almost 80% of patients with myopia.

The observed changes are primarily due to the destruction of the trabecular network. Slit-lamp examination fails to reveal regular trabecular structures—the trabeculae are scattered, some of them are in a state of disintegration into fragments. This process is called granular destruction of the stroma. The disintegrated fibers, their fragments, and detritus fill the gelatinous substance. Reflecting the incident light, they create a peculiar opalescence of the vitreous body and enhance the Tyndall phenomenon. The fibrils of the vitreous body can undergo changes of a different kind, expressed, on the one hand, in the splitting of the fibers, and on the other, in their gluing together into coarser bundles, which appear brighter in the light

of the slit lamp. This process is called filamentous destruction of the stroma (Fig. 17).



Fig. 17. **Changes in the vitreous body in myopia (granular and filamentous destruction of the stroma)**

Along with the destruction of the stroma, a change in the basic gelatinous substance of the vitreous body occurs. Liquefaction of the gel is observed with the formation of peculiar dark, optically empty cavities, which primarily appear in the central sections of the vitreous body. In some cases, liquefaction is diffuse and covers the entire vitreous body as a whole. Pendulum-like movements of the vitreous body during the destruction of the stroma and liquefaction of the gel disappear. They give way to the active chaotic movement of coarsened glued fibrils in the liquid watery substance of the vitreous body, which occurs with the slightest changes in the direction of the patient's gaze. When examined with a slit lamp, a constant, kaleidoscope-like change of biomicroscopic pictures is observed, and new combinations of elements of the altered stroma appear before the eyes of the researcher.

Unfortunately, no types of therapeutic effects are in state to return to the ciliary body to its normal state. These changes usually progress and in the end the doctor begins to see them when examining in the passing light with the help of ophthalmoscope in the form of floating, very rough opacities in the form of dark threads and conglomerates sailing against the background of red reflexes of the eyeball.

Another nosological form of vitreous pathology of the dystrophic type is its hernia. Hernia is called a protrusion of the vitreous body into the anterior chamber, which occurs with a penetrating wound to the eyeball, contusion (even mild), during or after some operations on the eyeball (intracapsular cataract extraction, removal or dissection of the secondary cataract film). In operations for secondary cataracts, a hernia occurs at the time of surgical intervention. In cases of intracapsular cataract extraction, the protrusion of the vitreous body into the anterior chamber is usually noted in the postoperative period, but sometimes it appears months after the operation.

Vitreous hernias are primary, or uncomplicated, and secondary, or complicated. In the first case, the integrity of the anterior limiting plate is not violated. The protruding vitreous body has the appearance of a transparent bubble hanging over the pupillary margin with a smooth or slightly wavy surface, the wall of which is formed by the anterior limiting membrane (Fig. 18 color).

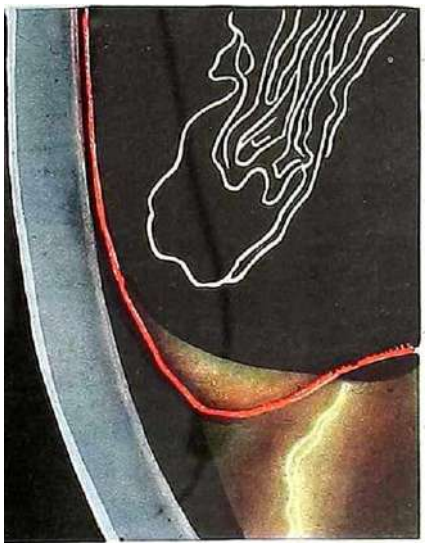

Fig. 18. **Vitreous hernia (uncomplicated)**

A complicated vitreous hernia is characterized by a rupture of the anterior border membrane. The latter most often ruptures if the vitreous body is liquefied. Apparently, this process is accompanied by a weakening of the strength of the border membrane itself. The vitreous body elements, not restrained by anything, freely exit into the anterior chamber and are located in it. The protrusion has an uneven surface, individual fibers of the vitreous body protrude into the chamber in the form of bundles and threads.

A complicated hernia can develop from an uncomplicated one. In some cases, the entire anterior chamber can be filled with vitreous body. At the same time in the chamber instead of watery moisture a jelly-like substance with a thin retinal structure is visible. The vitreous body unlike the chamber humor doesn't make convectional movements.

For easier diagnosis of vitreous hernia, it is recommended to examine the anterior chamber with a narrow illumination slit, maximum illumination brightness and medium microscope magnification. It is also useful to move the focused beam of light in the horizontal direction, which causes it to slide along the surface of the hernial protrusion. In this case, a delicate, haze-like, grayish membrane is revealed, limiting the mass of the protruding vitreous body.

The diagnosis of a vitreous hernia is significantly simplified in cases where there is a hemorrhage

in the hernial sac. The blood, like hyphema, is located in the lower parts of the sac and has a horizontal level. Sometimes the hemorrhage is located in layers. The spilled blood is absorbed very slowly.

Pigmented deposits frequently observed on or within a protruding vitreous body can serve as diagnostic indicators.

Over time the hernia of the vitreous body of small sizes can be flattened and decreased. Uncomplicated hernias of large sizes usually do not disappear. Constant contact with intraocular fluid can lead to a thickening of the borderline membrane of the vitreous body and in the cases of the complicated hernia - to the formation of the new delimiting membrane due to the sealing and condensation of the surface layers of the vitreous.

The presence of a vitreous hernia is not always of no importance to the eye. It can cause a slowdown in the recovery of the anterior chamber in the postoperative period, lead to a distortion of the pupil shape, and finally to the development of secondary glaucoma. The latter occurs when the vitreous body blocks the pupil, the angle of the anterior chamber, and when vitreo-corneal synechiae form. A vitreous hernia can cause retinal detachment. From the above, it is clear how important it is to timely detect vitreous body elements in the anterior chamber. In the process of diagnosis, it is sometimes difficult to distinguish a vitreous hernia from an inflammatory fibrinous effusion into the anterior chamber. The examiner may be confused by the fact that the fibrinous exudate, just like a vitreous hernia, has a jelly-like appearance with the presence of delicate grayish strands. However, the fibrinous effusion, unlike the hernia, is not associated with the pupillary opening, does not hang over the edge of the pupil, does not have strictly defined boundaries and, what is very important, and does not make active movements with the movements of the eyeball. In the difficult cases of the differential diagnosis dynamic observation may help: the type of the vitreous body hernia for a short time usually doesn't change; in the presence of fibrinous exudate its resorption or organization occurs.

Biomicroscopy of the posterior vitreous body is similar to biomicro-ophthalmoscopy in its methodological techniques.

Biomicroscopy of the fundus is a promising method for examining the fundus membranes in normal

and pathological conditions. This method significantly expands and deepens the possibilities of ophthalmoscopic diagnostics.

With ordinary ophthalmoscopic examination a normal retinal tissue is not detected. The exception is the vessels of the retina, in particular the branches of the first, second and third order.

A study with a slit lamp in diffuse light doesn't allow one to see the retinal tissue itself, although the biomicroscopic picture of the fundus as a whole seems to be stereoscopic and relief-like.

The use of diffuse lighting of the blue - green light filter allows detecting some structural parts of the retinal tissue since the filter turns off the red part of the spectrum.

At the same time the lighting in the circle of the yellow spot and the optic nerve disc we may see the delicate radial striation of the retinal tissue, indicating the presence of a layer of nerve fibers.

In young patients a naturally saturated yellow color of the central hole of the yellow spot which is disguised under the usual conditions of the lighting with a vascular membrane red reflex protrudes well.

In the elderly - the color of the yellow spot seems not to be saturated that may be associated with the absorption of yellow rays with a sclerosed lens.

The retinal vessels in a non-red light are distinguished in the form of dark, almost black branching trunks and are very clearly protruding the small branches almost not distinguishable during the usual ophthalmoscopic study.

Examination of the retina in diffuse light is inferior in its significance to examination using direct focal illumination. This method of illumination especially clearly reveals the advantages of the biomicroscopic method of examination. It allows one to obtain an optical section of the retina, to isolate it, and, as it was, to isolate it from the surrounding tissues, in particular from the underlying vascular membrane and the adjacent posterior limiting membrane of the vitreous body.

When examined in direct focal light, it becomes possible to examine the tissue of the retina itself. Under low magnifications of the microscope, the optical section of the retina has a saucer-shaped form, which corresponds to the curvature of the inner surface of the eyeball.

Unlike a stained histological section, biomicroscopy of the retina does not allow one to see individual layers of its tissue. However, under medium magnification of the microscope, the entire thickness of the retina is very clearly visible in the form of a silvery, slightly reflective strip.

In the section, its internal concave rib facing the vitreous body can be distinguished, which corresponds to the internal surface of the retina. This rib has the appearance of a fairly clear, grayish strip. It usually appears shiny due to the reflection of focal light by the internal limiting membrane of the retina.

The posterior edge of the optical section has a convex shape and is directly adjacent to the choriondea. It is not as clearly visible as the anterior edge and has a slightly yellowish, golden color, which is due to the presence of a layer of pigment epithelium here.

The entire tissue of the retina in the optical section has a homogeneous appearance, light gray color. Under the anterior edge of the section, the branches of the central vessels of the retina are clearly visible (Fig. 19). When examining the retina in an optical section in the area of the macula with careful focusing of light and a very narrow illumination slit, it is evident that here the section becomes narrower.

Along the edge of the optic nerve disc the front rib of the retinal cut in the norm almost doesn't change its direction and curvature, smoothly turning into the area of the disk itself. This indicates that in the main masses of people there is no difference in the survival of the retina and optic nerve in normal conditions.

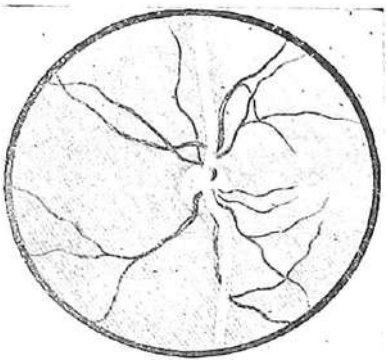

Fig. 19. **Optical section of the retina and optic nerve disc**

As for the back rib of the optical cut of the retina, it is in a norm at the edge of the optic nerve disc disappears which is associated with the disappearance of the pigment epithelium and tissue of the vascular shell itself.

The most common pathological form of retinal disease is its detachment, which usually does not

require special biomicroscopy. However, there are cases when the detachment is flat, not accompanied by typical changes in the fundus and visual field, which can present significant diagnostic difficulties. The biomicroscopic examination is indispensable in these cases. Examination of the detached retina in direct focal light using a very narrow and intense beam of light reveals that the optical section of the retinal tissue is not adjacent to the choroid. They are separated by a space filled with subretinal fluid. The configuration of the section itself changes.

If under normal conditions it has a concave-convex shape, then with retinal detachment the section becomes convex-concave, and sometimes wavy, which indicates the presence of retinal folds (Fig. 20). The anterior edge of the optical section with retinal detachment usually does not change color, and the posterior edge loses its characteristic golden color, which is associated with the absence of a layer of pigment epithelium under the detached retina. In cases of long-standing detachment, the optical section of the retina becomes dull and less transparent, acquiring a whitish tint.

A retinal tear is not always clearly defined during ophthalmoscopic examination. When a tear is localized in the central parts of the retina, especially in the area of the macula, diagnostic difficulties arise due to the frequent presence of dystrophic changes here.

In practical work, every ophthalmologist has to carry out a difficult differential diagnosis between the true extension, i.e., a penetrating hole in the yellow spot area and degenerative changes in this zone when a sharply contrasting area of the thinned retina is very reminiscent of the gap.

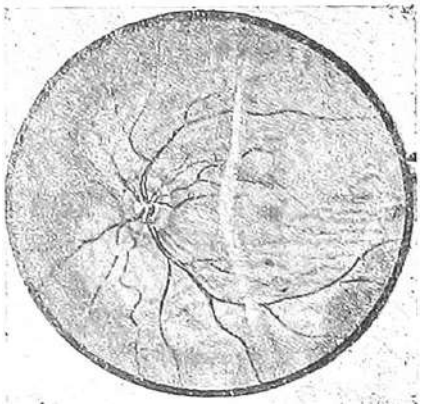

Fig. 20. **Retinal detachment (optical section)**

Diagnosis is especially difficult in the presence of a confused anamnesis, unilateral changes, the absence of a clear retinal detachment, unclear parallactic displacement of the damage zone com-

pared to the surrounding areas of the fundus.

Meanwhile, an accurate diagnosis in such cases is absolutely necessary.

A true retinal rupture is characterized by the fact that the optical section of the tissue at the edge of the rupture breaks off and disappears completely. The light beam seems to fall through, dives into the depths. In this case, the pattern of the vascular membrane is clearly visible. On the other side of the rupture, the optical section of the retina reappears as a clearly visible gray strip. In some cases, along the edge of the perforated rupture, the retina appears somewhat raised, edematous, protruding into the vitreous body. When using oscillatory lighting, a parallactic shift of the rupture zone appears.

Let us present the following observation.

Patient B, 60 years old, was admitted to the hospital with a complaint of decreased vision in the right eye over the past month.

The anterior segment of the eye is unchanged. The optical media are transparent. The fundus shows an elevated retina, mainly in the central sections. A round red spot was found in the macular area, resembling the central pit of the macula, which contrasts against the background of edema. Visual acuity is 0.03, correction does not improve.

When examining with a slit lamp in diffuse light, a sharply contrasting area was found in the macular area, resembling a retinal tear.

When examined in direct focal light, it was found that the optical section of the retina in the central parts of the fundus was raised, and in the area of the supposed rupture it completely disappeared, interrupted, which indicates a complete absence of retinal tissue here. The edges of the rupture were slightly raised and thickened due to the thickening and turbidity of the retina. Between the opening in the retina and the choroid there is a space occupied by a transparent fluid. In the depth of the opening, in the area of the focal beam, a pattern of the choroid is revealed (Fig. 21).

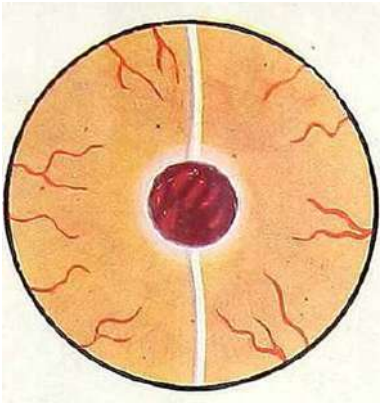

Fig. 21. **Rupture of the retina (optical section)**

The conducted study is the basis for deciding on the possibility of laser coagulation of the rupture.

The method of bio-microophthalmoscopy allows differential diagnostics between a true rupture of the retinal tissue and its dystrophic degeneration.

The optical section of the retina in the area of dystrophy, unlike a retinal rupture, never disappears. The section can sometimes be thinned to such an extent that its anterior and posterior edges almost merge, but the retinal tissue is not interrupted anywhere.

Patient F, 17 years old, complained of decreased vision in the right eye, which he associated with blunt trauma.

The anterior segment of the eye is unchanged. The optical media are transparent. In the fundus in the macular region, there is a rounded area with clear borders, 0.5X 1.0 RD in size, deep red. In its circumference, there is a delicate radar defect of the retina. Visual acuity is 0.1, correction does not improve. The visual field is normal.

Due to a suspected retinal rupture, the patient was examined with a slit lamp. It was found that in the affected area the optical section of the retina is thinned, but not interrupted anywhere, which indicates the preservation of the retinal tissue (Fig. 22).

The absence of an elevated section of the retina around the dystrophic focus made it possible to reject the presence of retinal detachment.

In some areas of dystrophic degeneration of the retina, the thickness of the section, on the contrary, increases noticeably. It is evident that the anterior rib is located at a considerable distance from the posterior one and slightly protrudes towards the vitreous body. The space between them appears darkened, which indicates that it is filled with a transparent liquid. The pattern of the choroid, visible behind the section of the retina, is quite clear.

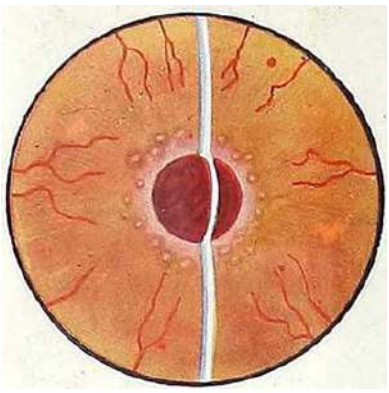

Fig. 22. **Retinal dystrophy (optical section)**

Such variants of the biomicroscopic picture indicate that there is no through hole in the retina, there

is only thinning and cystic degeneration of its tissue.

Sometimes, next to the centrally located section of the rebirth, there are several more zones with a similar biomicroscopic picture. This circumstance facilitates the correct diagnosis. The diagnosis is also confirmed by examination using indirect lighting (examination in a dark field). This type of lighting is easy to create by moving the focal beam to the side and slightly expanding the lighting gap.

At the same time the zone of cystic degeneration, illuminated by indirect rays of light, begins to shine through like a flashlight.

Among the other retinal degenerations (dystrophies) in which slit lamp examination can be of undoubted benefit, we should dwell on senile dystrophy.

In the initial stage of the disease, the changes are so insignificant that they are not detected by ophthalmoscopic examination, although patients present certain complaints, in particular the appearance of metamorphopsia.

At this stage, when examining the retina in diffuse and especially in red-free light under a slit lamp microscope, one can detect small yellowish foci, point deposits of pigment, located in the form of a circle or oval in the region of the central fovea of the macula. When examined in direct focal light, these changes are inscribed in the optical section of the retina. The subsequent destruction of the retinal pigment epithelium leads to the exposure of the choroidal tissue and the translucence of the vascular layers of the latter. Morphological studies have established that in this case, the death of the first neuron of the retina occurs, the spread of pigment epithelium into its tissue. This is accompanied by sclerotic atrophy of the choroid. It should be said that such changes can also occur at a young age and even in children.

Coloboma of the macula is one of the changes in which biomicroscopy of the fundus is of particular interest. This examination is necessary if the process is observed in only one eye, since in this case central chorioretinitis may be erroneously diagnosed.

In typical cases of colobomas in the area of the yellow spot the atrophic section of the white color choroid is visible. The retinal cut in the coloboma region is there but it is thinned. Retinal vessels visible under the front edge of the cut, aren't changed.

The edge of the coloboma is clearly outlined. On this edge the

slice of the retina makes a sharp bend towards the choroid.

Biomicroscopic examination of the retina is also useful in cases of difficult diagnosis of subretinal cysticercus. The parasite's vesicle, having destroyed the vascular membrane, usually extends under the retina and causes its peculiar limited detachment. It is most often localized in the central parts of the fundus near the optic nerve disc. The detachment has clear boundaries and a yellowish-golden color.

Slit lamp examination under high magnification of the microscope helps to see the neck and head of the parasite under the detached retina. In typical cases, these details can also be seen with regular ophthalmoscopy. Biomicroscopic examination helps to establish a diagnosis mainly in cases where a dense capsule forms around the cysticercus bubble. Ophthalmoscopically, a gray-white formation resembling a tumor is visible.

The head and neck of the parasite are not visible, just as its movements are not visible. Study with a slit lamp by the indirect lighting helps to detect the translucency of the bubble and reject its blastomatous nature.

During biomicroscopy of the optic nerve disc, it is clearly visible that the nerve tissue that forms the disc and the nerve trunk itself in its intrabulbar part is translucent and translucent, which can be explained by the absence of the pulpy membrane here.

This circumstance allows us to penetrate into the depth of the nerve trunk with the help of a focal beam of light. Here we can see the dense lattice plate of the sclera. It has a bright white color and actively reflects the incident focal light.

The cribriform plate usually reveals openings for the passage of nerve fibers, and the fibers themselves, due to the absence of a myelin sheath, are differentiated very indistinctly. On the surface of the cribriform plate, especially in red-free light, the trunks of the central retinal vessels are clearly visible.

When moving the focus of a microscope from the edge of the optic disk in the area of the lattice plate, it’s possible to catch a larger or lesser degree settled from the surface of the disk. The optic nerve neuritis is characterized by biomicroscopy with a thickening, fuzziness of the optical cut of the retina in the circle of the disk. The retinal slice is drained with the thickened, fuzzy and cloudy cut of the nerve fibers forming the nerve barrel. Physiological excavation of the disk and the lattice plate of the sclera are

not visible, veiled by the exudate (Fig. 23).

In the tissues of nerve fibers small, mainly radial hemorrhages are determined which gives an optical cut a reddish tint. The central vessels in the cut are poorly visible.

Optic neuritis is characterized by thickening and blurring of the optical section of the retina around the disk in biomicroscopy. The section of the retina merges with the thickened, blurry and cloudy section of the nerve fibers that form the nerve trunk. The physiological excavation of the disk and the cribriform plate of the sclera are not visible, veiled by exudate (Fig. 23).

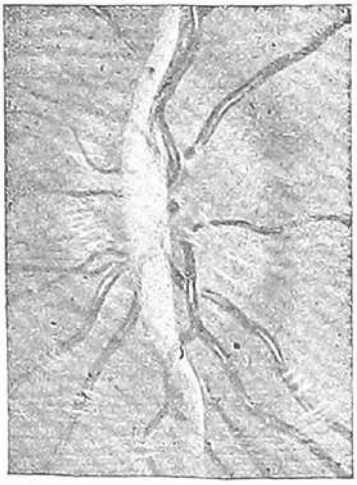

Fig. 23. **Optic neuritis**

In the tissue of nerve fibers, small, mainly radial hemorrhages are determined which gives an optical cut a reddish tint. The central vessels in the cut are poorly visible. During biomicroscopy of the posterior sections of the vitreous body, it is often possible to see accumulations of delicate cloud-like exudate in it.

Sometimes the inflammatory changes are very subtle. They are expressed both in the appearance of the Tyndall phenomenon in the space in front of the optic nerve head and in the deposition of point elements on the posterior limiting membrane of the vitreous body.

The process is usually accompanied by a decrease in visual functions, especially a narrowing of the field of vision for red and green colors. In cases of initial development of stagnation of the papilla, thickening of the layer of nerve fibers is observed only along the edge of the optic nerve disc (marginal edema). The section of nerve fibers in the central parts of the disc is unchanged.

It is clearly visible how the thickened optical section of the retina in the circumference of the optic nerve disc sharply "breaks off", protruding forward towards the vitreous body, and accordingly, in the central zone of the disk, the section of nerve fibers seems to roll down, diving into the depths.

This distinguishes the congestive papilla from neuritis, where, as stated above, thickening and blurring of all nerve fibers forming the optic nerve disc, including those located centrally is observed.

With congestive papilla, physiological excavation is clearly visible at first, the cribriform plate of the sclera is clearly defined, which is not observed with inflammation of the optic nerve. With congestive papilla, despite the thickening of the optical section of the fibers along the edge of the disk, the section itself remains transparent for a long time, which also distinguishes congestive papilla from neuritis, where the section of the nerve elements already in the early stages of the disease becomes unclear and cloudy. The posterior portions of the vitreous body with congestive papilla, as a rule, remain transparent.

It goes without saying that when conducting differential diagnosis between the initial stages of the neuritis of the optic nerve and the congestive nipple, it is necessary to take into account the nature of the ophthalmological picture as a whole, the anamnesis data, general clinical examination, the state of visual functions which with the congestive nipple, unlike neuritis, remain reliable for a long time.

The result of the biomicroscopic study in these processes should only complement and clarify the overall picture of the disease since in the ophthalmological diagnosis it is necessary to use a larger number of data from a comprehensive study of the patient so that the conclusion is closer to the truth.

A biomicroscopic examination is no less important in the early and differential diagnosis of choroid diseases. The biomicroscopic picture of the normal choroid may vary depending on the degree of pigmentation of the fundus. In blondes and albinotic individuals, some details of the structure of the choroid proper can be seen quite well. When examined in an optical section, it is evident that the choroid tissue is not compact, it has a spongy appearance. Vascular loops located at different depths of the section are clearly visible. The intervascular spaces are filled with semi-transparent homogeneous tissue of a light pink color. Pigment lumps are visible in it.

With careful focusing, in addition to the fairly clearly defined intertwined vascular trunks, wide, less contrasting red lacunae stand out, which should be attributed to venous collectors.

The biomicroscopic picture of the choroid in brunettes is com-

pletely different. Only individual, largest intersecting vascular branches are visible, separated by densely pigmented zones of irregular shape. Abundant, especially finely dispersed pigmentation masks the pattern of the choroid and in many cases, completely deprives the possibility of penetrating into the depth of the tissue being examined.

Changes in the choroid are known to be mostly inflammatory in nature, which is due to the structural characteristics and blood circulation of the uveal tract.

Inflammation of the choroid is usually accompanied by inflammation of the retina. The diagnosis of chorioretinitis at any stage of its development can be established by means of a routine ophthalmoscopic examination, taking into account the data of the general somatic and laboratory examinations of the patient.

We have observed how in some cases, with a favorable course of the disease, an increase in visual functions and a change in the ophthalmoscopic picture, indicating the clinical recovery of the patient, the anti-infective treatment that had been started was stopped.

After a short time, a relapse of the disease occurred. This, in our opinion, should be associated not with a new dissemination of the infectious agent, but with the reactivation of an incompletely cured inflammatory focus.

This circumstance is confirmed by the fact that the inflammatory reaction usually appears not in new areas of the choroid, but within the old chorioretinal focus.

That is why in practical work, in order to judge the complete clinical recovery of the patient in some cases in addition to the general somatic, ophthalmoscopic and functional examination of the patient, conduct a biomicroscopic examination.

As is known, the inflammatory infiltrate in the choroid under the influence of the treatment is partially absorbed, partially replaced by cicatricial connective tissue.

The completed process is characterized by the formation of a chorioretinal lesion of a variegated appearance with clear boundaries. The central sections of the lesion are white, with lumps of pigment located on its periphery.

Biomicroscopic examination reveals unevenness and instability of the retinal section. Along the edge of the lesion, the retinal section bends, as if plunging into the depths, which indicates thinning and atrophy of the vascular membrane tissue. The retinal vessels

above the lesion are narrowed. The optical section of the retina is tightly fused with a thin, translucent film of connective tissue, which is located in place of the vascular membrane destroyed by inflammation. This film contains almost no vessels, with the exception of several large branches that are located on the inner surface of the sclera.

Such choroidal vessels, not masked by pigment, are visible better than under normal conditions. They are thicker than the retinal vessels and are characterized by various branching variants (Fig. 24). The vascular wall is usually compacted and thickened to the point of complete obliteration of the vessel lumen.



Fig. 24. **Chorioretinitis (finished stage)**

The above picture is typical of a completed inflammatory process. If, during a biomicroscopic examination, signs of unabated inflammation can be noticed somewhere along the edge of a seemingly completely calm choroidal focus, the disease cannot be considered completely cured. Such signs include thickening and clouding of the optical section of the retina, obscuring of its vessels, the presence of a gray-yellow coloration of the choroidal tissue with an unclear section of the choroid, the absence of pigment in the tissue, and a slight cloud-like clouding of the adjacent parts of the vitreous body.

The biomicroscopic examination is of great importance in diagnosing choroidal melanoblastoma.

In the presence of a tumor, the section of the retina appears more or less elevated. Underneath it, compact, homogeneous tissue is visible, usually brown in color, sometimes permeated with a significant number of newly formed vessels.

The latter looks like the loops of the tumor branching in the dense mass. On the surface of the tumor tissue, hemorrhages and coarse pigment accumulations are sometimes found. In the case of so-called apigmented melanoblastoma, pigmentation elements can always be found during examination with a slit lamp. In these cases, the pigment is most often located along the periphery of the tumor node.

Examination of the tumor in indirect (diaphanoscopic) light, as a rule, does not provide transillumination, which emphasizes the compactness and density of the tissue being examined. The presence of a flat transudative retinal detachment above the tumor almost does not limit the possibilities of examination.

In the differential diagnosis of a choroidal tumor and inflammatory granuloma, it must be taken into account that with inflammation, the biomicroscopic picture is characterized by greater polymorphism, greater variegation.

Along with dense areas of proliferation, there are areas of tissue rarefaction, accumulations of inflammatory exudate, visible during examination in a dark field. In the circumference of the granuloma, daughter foci of inflammation are sometimes located.

A great interest in the process of the retina and especially the vitreous body is noted. In the latter, cloud-like inclusions of preretinal exudate can be observed above the granuloma, masking the tissue of the retina and choroid.

Differential diagnostics of initial planar melanoblastoma and congenital pigmented spot of the choroid - nevus are very important.

The latter is often located in the fundus central departments and has the appearance of a round or oval section of the aspid-gray color. The main difference between the pigment spot is its flat location. The optical section of the retina over the spot does not change in shape, direction, or thickness, as is typical in melanoma. Additionally, loops of newly formed vessels within the pigmented spot are not observed, which further distinguishes it from melanoma. The diagnosis of a nevus requires dynamic monitoring, as cases of malignant transformation have been well documented.

During observation, attention should be paid to the increase in the size of the pigment spot along the plane and especially to the increase in the degree of its protrusion above the surrounding fundus. The latter circumstance is a sure sign of the beginning of blastomatous growth. This sign can be detected by monitoring the change in the curvature of the optical section of the retina. The appearance of newly formed vessels in it and the movement of the pigment should also be considered a sign of malignant degeneration of the pigment spot. It would be wrong to think that the biomicroscopy method is the only and leading one in the complex process of differential diagnosis of initial cho-

roidal melanoblastoma and nevus. A practicing physician should be aware of the great possibilities that are opened up by the methods of ultrasound echography, fluorescent angiography, and choroidal angiography.

However, these methods are used mainly in clinical institutions. In conditions of ordinary clinical intake, a biomicroscopic examination can be supplemented by perimetry and examination of the fundus in a steady light. Since melanoblastoma raising the retinal neuro-epithelium leads to a violation of its functional possibilities, it is during the blastomatous process that the skotoma appears in the visual field. The same circumstance of involving in the process the choroid of the retina in melanoblastoma leads to the fact that melanoblastoma remains visible in the unred light, and the nevus of the choroid disappears.

SECTION III

FUNDAMENTALS OF OPHTHALMOLOGICAL VIROLOGY

At present, viral diseases occupy a leading place in human infectious pathology. Advances in general virology, which is a major section of microbiology, have led to the emergence of a new direction in the study of eye diseases - ophthalmovirology.

The study of viruses dates back to 1892 when the Russian botanist D.I.Ivanovsky became interested in the problem of tobacco mosaic disease. He established that the causative agent of this disease passes through dense ceramic filters that retain bacteria. The filtrate obtained by D.I.Ivanovsky was free of bacterial elements and at the same time infectious for healthy tobacco leaves. Thus, a new world of living beings was discovered - filterable viruses that cause diseases in humans, animals and plants.

Currently about three thousand pathogens of viral diseases have been identified and many of them are directly related to eye pathology.

This may be due to the fact that the eye is a system that actively reacts to the introduction of viruses through the conjunctiva, cornea, and also endogenously, i.e. through the blood and lymph. An ophthalmologist has to deal with infectious viral agents of various tropisms (selectivity) in relation to the tissues of the eyeball and its adnexa. These are dermotropic, neurodermotropic, epitheliotropic viruses, adenoviruses, enteroviruses. There are pathogens with mixed tropism, the so-called polytropic viruses. The tropism of a virus depends on the presence of special receptors on its surface that correspond to certain receptors on the surface of the cells of the tissue where the virus is able to parasitize.

It is interesting that in a number of cases mixed infection with two or three pathogens occurs. Thus, in viral diseases of the conjunctiva and cornea, according to statistics, mixed infection is observed in 17% of cases. This fact has been proven by special immunological research methods.

The most frequent symbiosis is between adenovirus and rhinovirus, herpes virus and influenza and parainfluenza virus. Such com-

bined infection can cause an atypical clinical manifestation of the conjunctiva disease, cornea or iris, relapses of the disease, difficulty of ethnological diagnostics based on clinical signs of damage.

The discovery of new viruses with the emergence of previously unknown clinical forms of eye tissue damage and the facts of mixed viral infection require that practicing ophthalmologists master the basics of ophthalmovirology. The published materials should promote a more active perception of information on this issue. They include information from the course of general virology, a description of the clinical signs of the most common eye diseases of viral origin.

Chapter 1

ACUTE VIRAL CONJUNCTIVITIS

In recent years, among conjunctival diseases, which according to various authors account for 30 to 47% of all ophthalmological pathology, clinical forms that owe their origin to viral infection are increasingly encountered. The emergence of new, as yet insufficiently studied forms of damage to eye tissue by viral infection has been noted.

Epidemic hemorrhagic conjunctivitis (keratoconjunctivitis)

This acute disease of the conjunctiva of the eyelids, vault and eyeball in the form of an epidemic outbreak was recorded in the country's eye hospitals in 1971.

Foreign ophthalmologists working in the hot climates of Asia and Africa had the opportunity to observe outbreaks of hemorrhagic conjunctivitis epidemics in previous years and in a more developed and pronounced form. 10F. Maychuk cites information on the defeat of epidemic hemorrhagic conjunctivitis in a quarter and even half of the entire population of cities in equatorial Africa. The fact of high contagiousness of the disease was established (100% morbidity in the absence of effective preventive measures).

The clinical manifestations of conjunctivitis are very specific. First of all, it is an acute onset. Incubation, which takes one or two days (sometimes 8-12 hours), is usually not felt by the patient. The first symptom of conjunctivitis is a feeling of burning in the eyes, the inability to look at the light. In this condition, the patient certainly consults a doctor, unable to continue working or studying. During examination, edema of the eyelids, chemosis of the conjunctiva, its infiltration are noted, with the presence of

individual follicles on the lower transitional fold of the conjunctiva. The discharge is usually not very abundant, mucous, or mucopurulent in nature.

Typical symptoms, as all ophthalmologists believe, are hemorrhages in the conjunctiva and under the conjunctiva, appearing in the first hours of the disease and disappearing after a few days, and in some cases after two weeks. They have a wide variety of sizes and shapes. Sometimes it is a continuous hemorrhage, located over the entire area of the conjunctiva of the sclera, sometimes it is a hemorrhage in the form of a smear (Fig. 25). In some cases, microhemorrhages in the form of petechiae occur. They cannot be seen with the naked eye, and examination of such patients should be carried out using the method of biomicroscopy. The search for barely noticeable hemorrhages should be carried out in the upper half of the conjunctiva of the sclera, where they are most often concentrated.

The second clinical sign, pathognomonic for this conjunctivitis, is the appearance of small, point-shaped spots of white or white-yellow color in the conjunctiva. They resemble infarctions of the meibomian glands, which are well known to ophthalmologists. We have not encountered this symptom in other clinical forms of viral conjunctivitis. It owes its origin to the cytopathic action of the virus that causes hemorrhagic conjunctivitis.

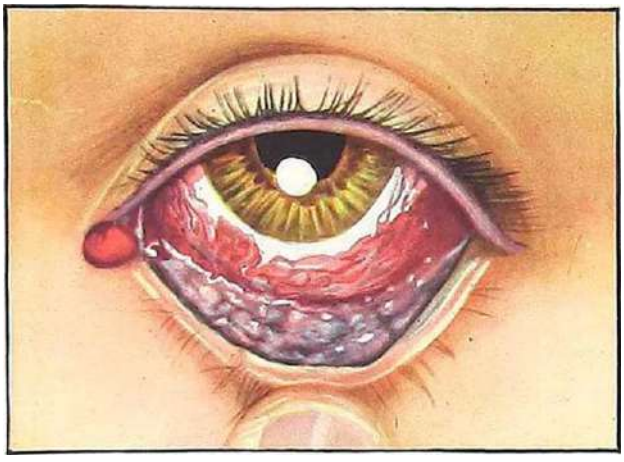

Fig. 25. **Epidemic hemorrhagic conjunctivitis (hemorrhage under the conjunctiva of the sclera)**

Penetrating into the excretory ducts of the mucous and accessory lacrimal glands of the conjunctiva, it causes their blockage by necrotic cells lining the duct.

Electron microscopic studies have shown that this virus belongs to the group of ribonucleic viruses and parasitizes the human intestine (enterovirus). It is very small in size, hence the name "picornavirus" from the word "pico", which means "small".

The clinical picture of conjunctivitis is generally supplemented by adenopathy of the preauricular lymphatic glands, expressed in their soreness and obvious enlargement. In some cases, keratitis develops. Its peculiarity lies in the very superficial epithelial localization of the process. Small infiltrates, stained with a 2% fluorescein solution, usually appear on the cornea. After a few days, the keratitis phenomena disappear almost without a trace, and as for the symptoms of conjunctivitis, they last on average up to 10 days, sometimes up to 2 weeks.

It cannot be said that after the disappearance of clinical manifestations, the patient recovers completely. Trace reactions may remain for some time, which leads to complaints of discomfort at work, a sensation of a foreign body in the eye. Observations indicate that there are cases when the clinical picture of conjunctivitis is combined with general symptoms in the form of weakness, malaise, increased body temperature, and then the diagnosis of influenza or catarrh of the upper respiratory tract is mistakenly made, against the background of which the general practitioner may not take into account or falsely interpret the eye symptoms.

Differential diagnostics of epidemic hemorrhagic conjunctivitis should also be carried out with such conditions that seem to have no relation to this disease as electric ophthalmia and snow ophthalmia. They are related to conjunctivitis by the commonality of subjective sensations: acute pain, photophobia, lacrimation, which can also be present in a person exposed to ultraviolet radiation. A thorough examination, carried out after the instillation of a 0.5% solution of dicaine into the conjunctival cavity, will allow one to easily diagnose hemorrhagic conjunctivitis based on the pathognomonic symptoms described above.

The epidemic situation and the mass nature of the lesion force us to conduct a differential diagnosis of hemorrhagic conjunctivitis with another, very common and already well-studied disease in all respects - acute epidemic adenoviral conjunctivitis (keratoconjunctivitis).

Acute epidemic adenoviral conjunctivitis (keratoconjunctivitis)

The epidemiological medical service encountered adenoviruses for the first time in 1953, when pathogens were isolated from human adenoid tissue, causing, as it later became known, various diseases: gastroenteritis, encephalitis, catarrh of the upper respiratory tract, pneumonia. Currently, about 40 different serotypes of human adenovirus have been isolated. Many of them are related to eye pathology, being transmitted by airborne droplets and through direct and indirect contacts (through a handshake, handkerchief, with a runny nose, cough). According to epidemiologists, adenovirus infection in 40% of cases is combined with influenza and some other diseases.

Acute epidemic adenovirus conjunctivitis is most often caused by type VIII adenovirus. It is very contagious and can retain its virulent ability for several days in the air and in liquid, especially at low temperatures. The latter circumstance may be the reason why conjunctivitis epidemics occur more often in colder seasons, during periods of changing temperatures and increased humidity.

The process, unlike cases of epidemic hemorrhagic conjunctivitis, does not begin so acutely and is not accompanied by sharp pain, which patients compare to the feeling experienced when a foreign body gets into the eye. The incubation period averages 10 days.

Characteristic features include swelling of the eyelids, hyperemia of the conjunctiva of the eyelids and the eyeball in combination with pronounced infiltration of the tissue of the lower transitional fold, lacrimal caruncle, and semilunar fold (Fig. 26), which is not seen in hemorrhagic conjunctivitis.

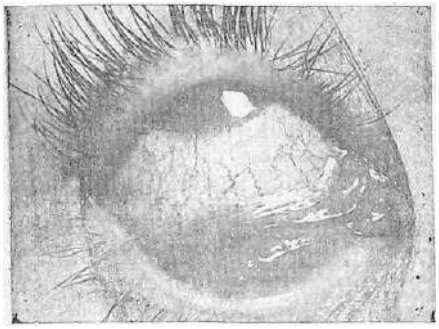

Fig. 26. **Acute epidemic adenoviral conjunctivitis (infiltration of the inferior transitional and semilunar folds, lacrimal caruncle)**

Characteristic features include the appearance of numerous translucent gray follicles both in the transitional fold and on the structures of the semilunar fold and lacrimal caruncle, which resembles a trachomatous process (Fig. 27).

It should be emphasized that even an ophthalmologist with limited experience is unlikely to make

a diagnostic mistake, remembering that trachoma never begins acutely and that the follicular elements in trachoma are primarily concentrated in the upper tarsal conjunctiva.

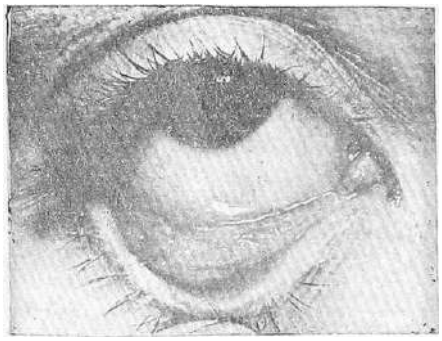

Fig. 27. **Acute epidemic adenoviral conjunctivitis (follicles on the lower transitional fold)**

During the differential diagnosis with a trachomatous process the fact of the gray raid appearance in the form of a film should also be used, particularly in children, and also the appearance of adenopathy from the sublary and submandibular lymphatic nodes.

Acute epidemic adenovirus conjunctivitis occurs with a small amount of discharge from the conjunctival cavity, which is serous-mucous in nature. If it happens that the disease of both eyes does not develop simultaneously, and the second eye is involved in the process later, then in this second eye, all clinical symptoms are less pronounced, apparently as a result of the development of immunity to adenovirus serotype VIII.

During epidemic keratoconjunctivitis, three stages can be distinguished: 1) acute clinical manifestations, which last up to 5-7 days and end with the complete disappearance of adenopathy, when the state of the lymph glands returns to normal; 2) attenuation, during which, however, with a unilateral process, a disease of the second eye may occur, where all the clinical symptoms of the primarily diseased eye occur in a milder form; 3) damage to the cornea. Keratitis occurs. It develops in 2/3 of cases, is superficial, and is accompanied by a decrease in corneal sensitivity. Knowledge of the typical clinical signs of keratitis allows the doctor to conduct differential diagnostics with other forms of viral conjunctivitis. Keratitis is usually focal. It suddenly appears in the second or third week of the conjunctival disease as a mass of grayish infiltrates. Initially, infiltrates appear in the cornea at the limbus, and then in more central areas (Fig. 28).

Their localization in the optical zone leads to a significant decrease in visual acuity (up to one or two-tenths or even hundredths). The infiltrates are rounded and are located in the superficial, so-called conjunctival layers of the cornea (Fig. 29).

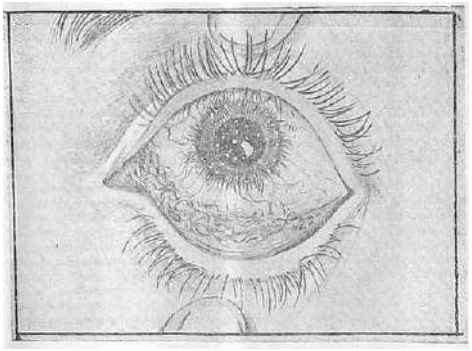

Fig. 28. **Focal keratitis in acute epidemic adenoviral conjunctivitis**

The peculiarity of this infiltration is that it is located in the stroma, without occupying the layers of the corneal epithelium. This is confirmed by the absence of staining of the corneal surface with fluorescein. The stromal localization of infiltrates, which sometimes have a pronounced, so-called coin-shaped character, explains the fact of their long-term existence.

Despite the resorption therapy, months, and sometimes even one to one and a half years, pass before the infiltration disappears and the previous visual acuity is restored.

From a conversation with ophthalmologists who had the imprudence to become infected during an outbreak of epidemic conjunctivitis from their patients, it was possible to find out that due to corneal opacities, with conjunctivitis having long since ended, they were forced to temporarily change the profile of their medical activity, since insufficient visual acuity did not provide them with the possibility of clear ophthalmoscopy.



Fig. 29. **Superficial localization of corneal infiltrates in acute epidemic adenovirus conjunctivitis (optical prism)**

Experience shows that in rare cases adenoviral conjunctivitis can begin with damage to the cornea.

Characterizing acute epidemic adenoviral conjunctivitis in general, it should be said that in the group of viral conjunctivitis, it is distinguished by the most severe and the longest and most persistent course, calculated at 3-4 weeks. In some cases, the matter is not limited to the presence of conjunctivitis or keratitis. Adenoviral iridocyclitis may occur, characterized by symptoms characteristic of inflammation of the iris and ciliary body of the serous or fibrinous (plastic) type.

Pharyngoconjunctival fever

This disease does not belong, like the described conjunctivitis, to the category of epidemic. There is not a single case of a significant contingent of the population falling ill with fever in the literature.

Pharyngoconjunctival fever is caused by adenovirus III, V and VII serotypes. All of them are resistant to low temperatures, are transmitted by contact, as well as by airborne droplets. If we analyze the patients by age, it turns out that the main percentage falls on children of preschool and primary school age. Eye disease is preceded by a clinical picture of acute catarrh of the upper respiratory tract.

This is expressed by an increase in body temperature to 38-39°C, the appearance of pharyngitis, rhinitis, tracheitis, bronchitis, and sometimes otitis.

Patients complain of weakness, malaise, a feeling of dryness and scratchiness in the throat, cough, and runny nose. During the examination, follicles can be seen on the back wall of the pharynx, sometimes in significant quantities, located on a hyperemic base; with grayish follicles on the uvula. The process is characterized by a clear line of demarcation of the inflamed mucous membrane of the pharynx from the normal mucous membrane lining the hard palate.

Against the background of general clinical manifestations or against the background of their slight abatement, usually on the 2nd-4th day of the disease, unilateral or bilateral conjunctivitis occurs. Its clinical picture consists of hyperemia and roughness of the conjunctiva of the eyelids, the appearance of small, transparent follicles in the area of the lower transitional fold, and sometimes the appearance of filmy deposits of a grayish color. Discharge from the conjunctival cavity is most often serous-mucous in nature.

A fairly typical sign is the reaction of the preauricular lymphatic glands. In some cases, especially in children with a history aggravated by allergies or diathesis, a more widespread reaction of the adenoid tissue is observed. This is expressed in an increase and soreness of the submandibular, cervical, subclavian and even axillary lymphatic glands. Pediatricians believe that such a reaction should be assessed as a complex clinical picture of an acute respiratory disease.

Against the background of the described general and local clinical picture the cornea is often affected. The cornea is involved in the process simultaneously with the conjunctiva.

The small pointed surface keratitis of epithelial localization occurred. Gray-colored infiltrates are stained with fluorescein. It is possible to verify their presence and conduct differential diagnostics with changes characteristic of corneal keratoconjunctivitis only with the help of biomicroscopy.

All clinical symptoms that form the basis of pharyngoconjunctival fever last no more than two weeks. Keratitis symptoms disappear without a trace.

Cases of relapse of pharyngoconjunctival fever are described in the literature. Relapse is usually provoked by a cold factor. It is possible that this is due to the absence of stable immunity during fever, it is also possible that a repeated outbreak of the disease is caused by infection with an adenovirus of another serotype, to which the body does not have immunity.

In practical work, it is necessary to deal not only with differential diagnostics of the three described forms of viral lesions of the conjunctiva. However, first of all, it is necessary to strive to distinguish them from conjunctivitis of bacterial origin, without which it is impossible to prescribe a justified pathogenetic treatment. Bacterial conjunctivitis is currently most often caused by staphylococcal infection, which some microbiologists figuratively call the plague of the 20th century.

Conjunctivitis of bacterial etiology usually differs from viral conjunctivitis by a large amount of discharge from the conjunctival cavity and different nature of the discharge, which very quickly becomes purulent.

Bacterial conjunctivitis, as a rule, never produces a general reaction in the form of an increase in body temperature, weakness and other sensations. They are not characterized by a follicular reaction from the conjunctiva (with the

exception of cases of follicular catarrh), and, as a rule, there is no involvement of regional lymphatic glands in the process.

Particular attention in differential diagnostics should be paid to the examination of the cornea. A decrease in its sensitivity, the appearance of point (and in some cases, coin-shaped) infiltrates of epithelial or subepithelial localization should direct the doctor's diagnostic thought towards a viral infection.

If differential diagnostics of conjunctivitis is difficult - classifying it as bacterial or viral, as well as in cases of mixed infection, which can cause a blurred picture of the clinical manifestations of the process, it is advisable to turn to bacterioscopic (bacteriological) and cytological research methods. These methods are available to every ophthalmologist and can be carried out in any institution with a minimum of laboratory equipment and a conventional light microscope.

During a bacterioscopic examination the material of the conjunctival cavity picked up by a platinum loop after applying a thin layer on the item is fixed above the flame of the burner, after which for 1-2 minutes stain the blue solution. The smear is considered under 90X increase in the microscope with immersion.

The detection of neutrophilic leukocytes and microbial flora (staphylococcus, pneumococcus) in a smear provides grounds for diagnosing conjunctivitis with an etiologic interpretation in accordance with the detected microflora (Fig. 30). Microorganisms are usually located outside the cells of the conjunctival epithelium and blood cells. But they can also be found intracellularly, which is typical for gonococcal conjunctivitis in particular. As for the cytological method of examining the conjunctiva, the technique for conducting it is as follows.

The procedure of taking a conjunctival scraping should be preceded by good anesthesia: three times instillation of a 1% solution of dicaine into the conjunctival cavity. It is possible, and even advisable, to use another technique, using an application of dicaine to the area of the lower transitional fold. To do this, a cotton wick soaked in a 0.5-1% solution of dicaine is placed in the lower conjunctival fornix for 3-5 minutes. Such anesthesia will make the procedure of taking a scraping completely painless.

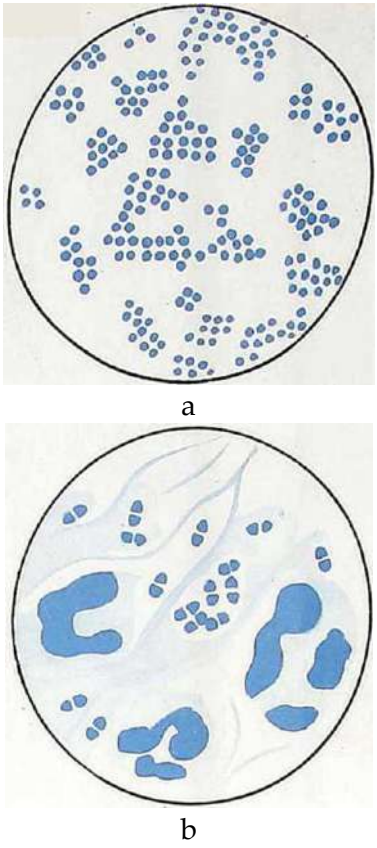

a

b

Fig. 30. **Bacterioscopic picture in acute bacterial conjunctivitis: a – staphylococci; b – pneumococci**

If the material for examination must also be taken from the upper transitional fold, then a similar application can be placed in the upper conjunctival fornix.

Having received anesthesia with a stupid object glass, with a blown knife of Grefe or a platinum loop with a certain pressure, the scraping of the conjunctival tissue from the desired area is performed. Having transferred the material to the item, they fixed it for 10 minutes in ethyl alcohol, then dried it in the air. They paint according to Romanovsky for 40 minutes, washed off with water from the tap and dried it in the air. After this, the microscopic examination begins.

What can a doctor observe under a microscope with 90x magnification and immersion?

In conjunctivitis of bacterial origin, conjunctival epithelial cells will be visible, lying in a scattered composition or in the form of a whole epithelial layer. The cell nuclei, their cytoplasm, and membrane appear unchanged. Along with cellular elements, neutrophils and bacteria can differentiate, which naturally get into the scraping material along with tissue structures.

In viral infection, a monocytic reaction occurs, and the tissue cellular elements are greatly altered. Nucleus lysis, nuclear fragmentation, and vacuoles in the protoplasm of conjunctival cells are observed (Fig. 31).

The membrane of the epithelial cells is destroyed, and it happens that the destroyed nucleus is outside the cell. Sometimes diseased cellular elements with destroyed membranes, merging, represent a giant cellular multinuclear struc-

ture, the so-called symplast. The presence of symplasts is very typical for viral infection. But in order for the described picture not to be artificial, it is necessary to very carefully scrape the conjunctival tissue, preventing its destruction and kneading.

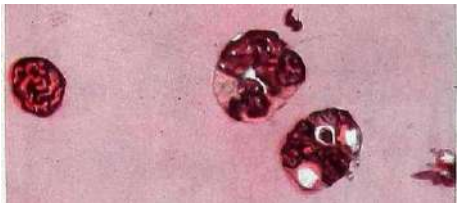

Fig. 31. **Cytological changes in acute VIRAL conjunctivitis**

As for hemorrhagic epidemic conjunctivitis in this case in the conjunctival scraping there are large quantities of erythrocytes that indicate the toxic effects of the virus on the vessels. The mononuclear type of cell exudate is characteristic, histiocytes are found.

How can the described cytological changes be explained from the standpoint of modern general virology and why are they characteristic of viral infection?

The fact is that the viral infectious agent, the virus (virion), unlike bacteria, has the ability to reproduce, to reproduce its offspring only on living cells, in a living organism, or in tissue culture. Viral disease pathogens do not parasitize on an artificial nutrient medium or extracellularly. They need a living cell. The virus is a precellular form of protein existence. It consists of nucleic acid and a membrane - a capsid. Nucleic acid (it can be ribonucleic or deoxyribonucleic, depending on which viruses are divided into RNA viruses and DNA viruses) penetrates the cell membrane, having previously been adsorbed on it in accordance with its tropism to a particular tissue. If we characterize this process more strictly, from a virological position, then we should say that the virion, after adsorption on cellular receptors, is captured by the cellular membrane, which invaginates into the cell, forming a vacuole. After this, the capsid is destroyed, and the viral nucleic acid becomes free. Then the nucleic acid molecule of the virus restructures the vital activity of the cell in such a way that the infected cell is no longer able to continue its previous existence.

It gives all energy resources to the formation of young viral progeny. In this case, the structures of the nucleus, nucleolus, and cytoplasm of the cell are used. All this, figuratively speaking, is the building material for the formation of initial viral particles. It becomes clear why it is precisely during vi-

ral infection that the epithelial (and lymphoid) cells of the conjunctiva lose their normal appearance and irrevocably lose their architecture.

The newly formed progeny of virions eventually leaves the cellular structures. In this case, the cellular membrane ruptures, and the cell nucleus and its nucleolus can exit into the surrounding space through the resulting defect. Then we see their extracellular location. The formation of symplasts - cellular multinuclear structures - also becomes clear. This is a group of conjunctival cells that have merged together due to the disappearance of the dividing membranes between them.

So, the cytological picture of the taken tissue scraping can provide an invaluable service in the diagnosis of viral infection. Unfortunately, it is not able to decipher which of the viruses is the cause of conjunctivitis (picornavirus, adenovirus, herpes simplex virus, virus cori). This is a means of differential diagnosis of only viral and bacterial infection.

To identify a specific pathogen of a viral infection, a method of immunofluorescence or fluorescent antibodies has been developed. Immunofluorescence is the luminescence in the ultraviolet light of a microscope of a biological object containing the antigen being studied after preliminary treatment with specific antibodies labeled with fluorochrome (fluorescent). At present, it is used only in large ophthalmological institutions where the laboratory service has a fluorescent microscope and appropriate serums containing antibodies against various pathogens of viral infections.

Nevertheless, an ophthalmologist must have an idea of this diagnostic method.

Its essence consists of the fact that stained serum (dye-labeled antibodies, for example, to adenovirus serotype VIII) is applied to the material of the conjunctival scraping located on a glass slide. If the patient has acute epidemic adenovirus conjunctivitis, the antibodies penetrate the virus-antigen located in the cells of the conjunctival scraping. When examined under a fluorescent microscope, the cell begins to fluoresce (glow). If the antigen and the attracted antibody are found in the nucleus, the cell nucleus will glow; if the antigen-antibody complex is localized in the cytoplasm, it is the cytoplasm that will glow (Fig. 32). Sometimes the entire cell begins to fluoresce, which indicates the presence of a viral infectious agent in all cellular structures.



a b

Fig. 32. **Immunofluorescence method in diagnostics of internal infection: a - reduction of the cell nucleus; b - luminescence of the cell cytoplasm**

This diagnostic method not only provides indisputable proof of a viral infection but also enables identification of the specific pathogen – i.e., the type of virus or, in some cases, multiple viruses in a mixed viral infection. Recently, up to seven types of antibodies have been detected using colored blood serum.

Undoubted successes in the study of the clinical picture and diagnostics of viral conjunctivitis correlate with achievements in the treatment and prevention of infection.

Since in some cases viral conjunctivitis occurs with certain general phenomena, it is useful to include general antibiotics in the antiviral treatment complex.

The category of etiological (etiotropic) local antiviral treatments includes syntomycin 1% liniment, oxolinic ointment 0.25%, tebrofen ointment 0.25–0.5%, florenal 0.25%, and glutadine 1% solution.

Deoxyribonuclease in the form of the eye drops is very popular among doctors and patients. It's the enzyme of the protein series, produced from the pancreas of cattle, inactivates deoxyribonucleic acid of viruses. The disadvantage is the inconsistency of the solution (12 hours).

A major event in the fight against viral infections was the creation of interferon and interferonogens. In the USSR, interferon was first obtained in 1960 by Academician Z.V.Ermolyeva. Interferon is associated with antiviral immunity.

It is well known that in response to any infection, the human body produces a protective reaction of immunity. It can be specific, i.e. aimed at combating a certain infectious agent, developing 2-3 weeks after the onset of the disease.

The carrier of such targeted, specific humoral immunity is an antibody produced by the reticuloendothelial system.

This immunity occurs both in bacterial and viral infections. However, in viral infection, unlike bacterial, another type of immunity develops - tissue immunity, which occurs in the cell affected by the virus very quickly (2 hours after infection).

The carrier of this immunity is a low-molecular, water-soluble protein - interferon. It is a source of non-specific antiviral immunity, which is expressed in a protective effect in relation not only to the pathogen that stimulated the formation of interferon but also to all other viruses. Therefore, if another viral infectious agent is introduced into the infected tissue, where interferon was produced in response to viral infection, a new infection will not follow since the cellular structures are protected by interferon immunity. It also prevents the spread of the emerging viral infection to healthy cellular structures that have not yet been affected by the process.

In conjunctivitis the use of the leukocytic human dried interferon in drops is adopted. In this case you should use one ampoule of solvent for two dry powders of interferon. Installations are made 6-8 times a day. The disadvantage is the fact that the drug retains its activity within 12 hours.

Interferon in the form of drops is called exogenous. However, it can be achieved that the eye tissue begins to produce endogenous interferon. These substances should be used to stimulate tissue structures to produce endogenous interferon.

Such viral interferogens include IVS (inactivated Semliki Forest virus), the UV-inactivated swine influenza virus, and an avirulent strain of the mumps virus.

There are bacterial interferon inducers, which include prodigiozan – a polysaccharide derived from bacteria – and pyrogenal.

It should be noted that in young children there is a reduced ability to produce interferon; therefore they should not be prescribed interferonogens.

When choosing antiviral drugs, it is not recommended to get carried away with their wide combination in order to avoid toxic-allergic reactions. It is possible to combine one of the solutions (deoxyribonuclease or interferon) with the ointment. Moreover, the instillation of the solution should precede the placement of the ointment into the conjunctival sac in time. In

cases of mixed infection, when bacterial flora joins, which can be judged by the presence of abundant purulent discharge and the results of bacterioscopic examination, it is advisable to include antibacterial drugs in the treatment complex. Some researchers attach great importance to the rhythm of the instillation of antiviral drugs. It is proposed to stretch the intervals between instillations of drops during the day and mandatory administration of drops, medicinal films and ointments at night. This allows maintaining therapeutic concentrations of drugs in the eye evenly throughout the day.

In addition to antiviral etiotropic agents, drugs with a nonspecific profile of action are indicated for viral conjunctivitis. This is, first of all, a group of desensitizing antiallergic drugs. This includes diphenhydramine, calcium gluconate and glycerophosphate. As for the use of corticosteroid drugs (prednisolone, dexamethasone) as antiallergic and anti-inflammatory agents, a certain amount of caution should be observed.

It is preferable to prescribe drugs locally (oftan dexamethasone solution). In case of pronounced symptoms of hemorrhagic conjunctivitis, it is advisable to prescribe ascorutin. It is much easier to take measures to prevent an epidemic of viral conjunctivitis than to stop an outbreak that has already begun.

Epidemiological studies have established that adeno- and enteroviruses persist in eye drops for quite a long time, up to two weeks. This explains the fact of hospital outbreaks of acute epidemic adenovirus and epidemic hemorrhagic conjunctivitis. The viral infectious agent can be transmitted even through solutions of disinfectants, antibiotics (sodium sulfacyl, furacilin, chloramphenicol), not to mention such drugs as pilocarpine, dicaine, vitamin solutions.

In addition to drops, the source of infection can be instruments and devices, poorly washed hands of medical personnel, bedding, towels, handkerchiefs of the sick person. You can even become infected through a door handle that the patient touched. A major role in the development of conjunctivitis is played by minor traumatic injuries to the conjunctiva or cornea that occur during procedures such as rinsing the lacrimal ducts, tonometry, oxygen therapy, removal of a foreign body from the conjunctival cavity or from the cornea.

When conjunctivitis appears, it is necessary in the hospital to isolate patients in the separate room where all treatment and medical examinations are carried out. In the stationary conditions it's necessary to distinguish for the patients a

separate medical table with medicines with a daily shift eye drop. It's necessary to use an individual pipette for each patient for dropping.

When performing tonometry on healthy people, tonometers must be disinfected with 6% hydrogen peroxide solutions, 1% chloramine solution or 5% phenol solution. Surgical instruments must be in the 6 % solution of hydrogen peroxide at cast 18 hours. Some metallic instruments, pipettes, solutions of medicinal preparations may be disinfected by 10-15-minute boiling.

The room should be cleaned in a moist way twice a day using a 1-2% solution of chloramine. During the epidemic it is advisable to produce a monument with a special text.

The resulting "entry gates" serve as a conductor of infection, and conjunctivitis in such cases is characterized by a more violent clinical course with a shortened incubation period. This is evidenced by the statements of the patients themselves, who clearly associate the onset of the disease several hours after one of the above procedures.

In the event of an outbreak of viral conjunctivitis in the hospital, as is required for infectious diseases, a corresponding registration card is filled out. By order of the administration, a quarantine is declared and visits to patients by relatives are temporarily prohibited.

In some cases, in the event of mass infection, the eye department has to be closed, and as for patients, they can be discharged from the hospital only after recovery from conjunctivitis. After washing and disinfecting the department, which also includes the treatment of mattresses, pillows and warm gowns in the disinfection chamber, the hospitalization of a new contingent of patients is permissible only after several days.

In the event of an epidemic of viral conjunctivitis, the reception of eye patients in the outpatient clinic should be reorganized. Patients with conjunctivitis are served after all other patients, i.e. at the end of the appointment.

When examining patients with conjunctivitis, it is necessary to turn back the upper eyelid, and this procedure must be learned to be performed without touching the eyelid with the right hand using a glass eye stick.

Chapter 2

HERPETIC EYE DISEASE

Herpetic infection is one of the most ancient in the history of mankind. It was known in ancient

times. Perhaps, it is the first infection from a large group of viral diseases that man encountered. Naturally, at that time there could be no talk of any scientific concepts defining viral infection.

The word "herpes" itself is of Greek origin. Translated into Russian, "herpes" means "crawling". It is possible that the name of the disease came from the subjective sensations experienced by a person during the disease, and perhaps is associated with the clinical manifestations of the disease.

From a morphological standpoint, herpes is defined as a disease characterized by a rash on the skin and mucous membranes of grouped vesicles on a hyperemic base.

Currently, herpes infection is one of the most common viral infections in humans. According to F. Manchuk, the number of patients with ophthalmic herpes in our country is 400-500 thousand per year (1979). Apparently, this is due to the known multiple tropism of the herpes simplex virus to various tissues of the human body. The causative agent of herpes belongs to large-sized HSV-containing viruses (Fig. 33).

It is known that the virus parasitizes and develops on epithelial, nervous, mesodermal tissues. Depending on the localization of the infectious process, the herpes simplex virus affects the skin, mucous membranes, central nervous system and peripheral nerve trunks, internal organs, and the organ of vision.

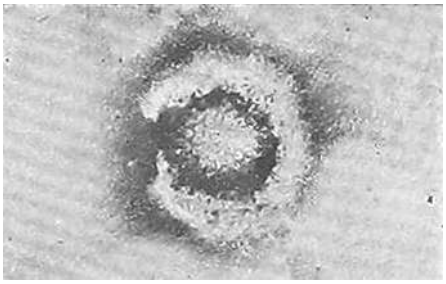

Fig. 33. **Herpes simplex virus by electron microscopy (negative contrast), magnification 250,000 times**

Neonatal herpes in newborns can also develop with genital infection in the mother. It flows hard. Infection with generalized localization can lead to a lethal outcome.

A special place in herpetic disease is occupied by damage to the organ of vision, in which the eyelids, conjunctiva, sclera, cornea, anterior and posterior sections of the vascular tract, retina, optic nerve can suffer. But the cornea suffers most often, due to its low immunity.

Herpes of the eye is more common in countries in the middle zone of the globe, where respiratory diseases are most common.

During the transitional season, the number of patients clearly in-

creases. It is possible that in these cases there is a mixed infection with the herpes simplex virus and the influenza or parainfluenza virus.

It is also necessary to take into account the fact that the viral infection persists for a long time (up to two years), in particular in the salivary, lacrimal glands, and conjunctiva.

Let us move on to the clinical characteristics of the herpes infection, following the anatomical principle of presenting the material.

In its clinical picture, herpes simplex of the eyelids usually does not differ from group herpetic eruptions in other parts of the skin of the face (near the wings of the nose, around the mouth opening, etc.).

The rash is usually preceded by general symptoms such as chills, headache, and fever. This is accompanied by local symptoms such as burning and sometimes itching of the skin of the eyelids. Following these symptoms, grayish blisters appear, which are the result of the peeling of the epithelial layer of the skin due to exudative effusion. The blisters are usually located on the hyperemic base of the skin, grouped in several pieces, sometimes merging (Fig. 34).

A few days after their appearance, the contents of the blisters become cloudy, crusts appear, which disappear without leaving scars on the skin. With a relapse of herpes, the rash of blisters usually occurs in the same place.

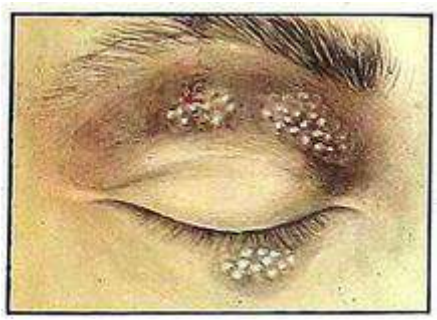

Fig. 34. **Herpetic dermatitis of the eyelids**

The application of exogenous interferons to the skin of the eyelids interrupts the process. If interferon is used at the initial stage of dermatitis, is it possible to prevent further development of the disease?

As for herpetic conjunctivitis, it should be said that it occurs more often in children, does not have constant pathognomonic signs for herpes, and is distinguished by polymorphism of symptoms. There is a catarrhal clinical form of conjunctivitis, a follicular form similar to adenoviral conjunctivitis, and a membranous form. Mixed viral infection of the conjunctiva cannot be ruled out, which determines the diversity of the clinical picture. The final diagnosis is established by

cytological and immunofluorescence studies (see above), after which appropriate therapy is carried out (see treatment of viral conjunctivitis). Herpetic conjunctivitis is characterized by a sluggish course, a tendency to relapse.

The clinical picture of herpetic keratitis has been studied most thoroughly at present. Herpetic keratitis accounts for 20% of all keratitis, and in pediatric ophthalmological practice even 70%. In 10% of cases, keratitis leads to blindness. Herpetic keratitis, unlike other viral diseases, develops in animals (monkeys, rabbits, rats), which allows for experimental studies of this pathology. Herpetic keratitis can be primary and post-primary. Knowledge of these concepts is absolutely necessary for a practicing physician.

Newborns usually have antibodies to the herpes simplex virus. They receive them during the intrauterine period through the placenta and after birth through the mother's milk. Thus, a newborn, if he was not infected in the antenatal period or at birth, is to a certain extent protected from herpes infection by the passive immunity given to him by the mother. This immunity protects the child from infection for 6-7 months. But after this time, all people, as a rule, become infected with the herpes simplex virus. This happens unnoticed. The infection gets to the baby from others by airborne droplets, through kisses of adults, dishes. Incubation is 2-12 days. This primary herpes infection is asymptomatic in 80-90% of cases but can lead to severe diseases of the skin, mucous membranes, eyes, and even viral septicemia with cyanosis, jaundice, and meningoencephalitis.

Primary herpetic keratitis accounts for 3–7% of all herpetic eye lesions. Because the antibody titer against the herpes simplex virus in affected children is still quite low, primary herpetic keratitis tends to be very severe. The process most often begins in the central parts of the cornea, where trophism is somewhat lower than in the peripheral areas adjacent to the marginal looped vascular network, which are therefore in better nutritional condition.

Keratitis occurs with ulceration of the corneal tissue, early and abundant vascularization. As a result, there remains a pronounced clouding of the cornea.

At the age of 3-5 years, children in 90% of cases already have immunity to the herpes simplex virus, and the infection goes into a latent state, remaining in the body for life and subsequently causing

an exacerbation of the disease under the influence of a variety of factors, such as any infection, most often viral (acute respiratory disease, flu, parainfluenza), hypothermia, intoxication, trauma. These conditions cause a decrease in the tension of antiviral immunity, and the disease recurs. It can have a variety of clinical manifestations, for example, herpes of the lips, stomatitis, encephalitis, vulvovaginitis, cervicitis, conjunctivitis, keratitis.

This type of keratitis, which occurs against the background of a latent herpes infection, is called post-primary. The patient does not necessarily have had primary herpes keratitis in the past. The herpes infection could have been localized in a different way. But the keratitis that has developed after the primary herpes infection, against the background of existing but unstable immunity, already belongs to the category of post-primary keratitis. Very rarely is the process limited to just one (single) outbreak. Most often, it recurs, causing an exacerbation 5-8-10 times (in 60% of cases). Relapses are cyclical in time, occur in the same eye, in the same place, or near the old lesion. Sometimes a relapse is preceded by an eye injury.

Sometimes a recidive is preceded by an eye injury. Very often the next exacerbation coincides with the appearance of temperature, cough, runny nose and flu standing.

This clinical detail should be used by an ophthalmologist in the diagnosis. The recidives are very burdened by the flow of keratitis and the prognosis since after each of them there is an opacity in the cornea.

Before focusing the attention on the state of the sick eye, it is necessary to examine the skin and mucous membrane of the patient, whether there are any manifestations of nervous infection on them, which is often combined with the herpes of the eyeball and its appendage apparatus.

Currently, two strains of herpes have been identified. The first, oral, causes herpetic lesions on the face, lips, and nose. The second, genital, affects the genital area and the anal area. Therefore, when examining a patient, one should avoid false modesty and examine all suspicious areas of the skin and mucous membranes, keeping in mind that herpetic lesions are located mainly around natural openings, in those places where the mucous membrane passes into the skin.

When analyzing the condition of the diseased eye, it should be remembered that herpetic keratitis is mostly unilateral. Despite the fact that the herpetic infection is spread throughout the body and, in particular, is localized in the tissues of the healthy eyeball, as evidenced by the characteristic cytological changes in the conjunctiva of the healthy eye and a positive immunofluorescence reaction with the herpetic antigen, the pathogenic properties of the infection are realized only on one side.

However, in 5% of cases, keratitis is bilateral. The reason for this is unknown. It is possible that it is connected with a more virulent strain of the herpes simplex virus or insufficient tension of the antiviral immunity, which allows the infection to realize its pathogenic properties in the cornea of both eyes. Viral keratitis is characterized by a sharp decrease or complete absence of sensitivity of the cornea, which is explained by the neurotropic features of the herpes simplex virus.

In practical work, to establish this important fact - a decrease in the sensitivity of the cornea - it is not necessary to have an algesimeter or Frey hairs. You can use ordinary cotton hair, checking the sensitivity of the cornea first of the healthy and then of the diseased eye. When assessing sensitivity (in comparison), you should stick to symmetrical zones of the cornea, checking and comparing the sensitivity of both corneas in the center, at the top, at the bottom, in the temporal sections, in the medial sections. You should not be confused by the fact that a clinically healthy eye may also have some decrease in the sensitivity of the corneal tissue.

This is understandable taking into account the above: the cornea of a healthy eye is also in a viral infection state but here the infectious principle doesn't show its pathogenic opportunities.

The fact of decreased or complete absence of tissue sensitivity in herpetic keratitis is explained by original findings in biomicroscopic examination. Examination of the cornea in diffuse illumination or in direct focal light with an expanded illumination slit, which makes it possible to obtain an optical prism of the cornea, reveals thickening of the nerve trunks covered with a myelin sheath, their bead-like appearance. This, together with a decrease or absence of tissue sensitivity, makes it possible to establish the presence of neuritis or perineuritis

of the trunks of the long and short ciliary nerves responsible for the sensitivity and trophism of the cornea. Objective hypoesthesia of the cornea is accompanied by subjective hyperesthesia.

Post-primary herpetic keratitis is characterized by a small number of newly formed vessels and even their complete absence. In primary herpetic keratitis, characterized by the disintegration of corneal tissue, there may be abundant neovascularization.

In concluding the description of the general semiotic signs of post-primary herpetic keratitis, it is necessary to emphasize the sluggish course of the inflammatory process, the very slow regeneration of the affected tissue. Usually, the acute onset does not correspond to the rigid background of the disease.

The listed common and local signs, characterizing the corneal herpes, allow to make a diagnosis as such. But the corneal herpes as is known, can proceed in various clinical versions on which the process largely depends.

A thorough examination of the diseased cornea reveals the following most common clinical forms of herpetic keratitis.

Superficial keratitis with the process localized in the epithelial layer of the cornea. The epithelial action of the herpes simplex virus is mainly manifested here. Point-shaped infiltrates alternating with vesicular detachments of the edematous corneal epithelium (Fig. 35) cause a rather motley picture of damage to the corneal tissue.

It is often dotted with small vesicular or gray point elements of infiltration, which are stained with fluorescein and epithelialize very slowly. They are usually localized at the end of the corneal nerves.

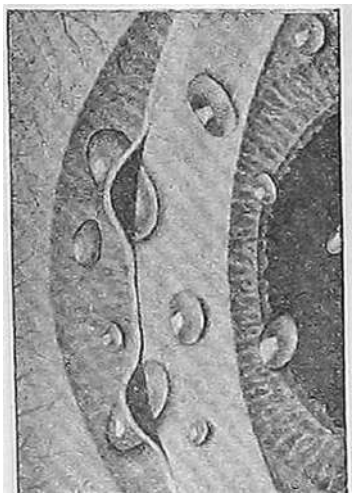

Fig. 35. **Superficial herpetic keratitis, bullous form (optical section of the cornea)**

Sometimes the exfoliated epithelial layer with flashing movements of the eyelids is twisted into

a kind of thread being in some area attached to the erosion surface of the cornea. This gives a clinical form of a rather rarely encountered filament or thread-filiform keratitis. Corneal erosions heal extremely slowly and often recur.

Practitioners are well aware of the clinical form of dendritic or bushy herpetic keratitis (Fig. 36). It received its name due to the peculiar type of erosion of the corneal epithelium, which resembles a branch of a bush or tree.

This is due to the fact that infiltration in the damaged cornea is located along the inflamed nerve trunks. It is here that bullous elements of the epithelium appear very quickly, which open up and lead to the formation of a branched erosion, since the nerve trunks of the cornea also branch.

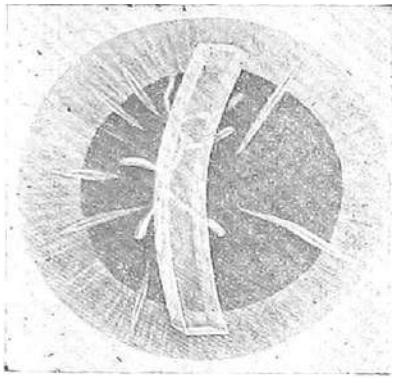

Fig. 36. **Dendritic herpetic keratitis (optical prism of the cornea)**

Despite the fact that the dendritic form is related to the forms of corneal herpes of superficial localization in its clinical manifestations, it also contains elements of a deeper localization of the process. This is expressed in the edema of the corneal stroma surrounding the dendritic erosion, the appearance of folding of the Descemet membrane.

The classic form of deep herpetic keratitis is discoid keratitis. It develops when the herpes simplex virus penetrates the corneal stroma from the outside, or by hematogenous means. The infiltration occupies the central optical zone of the cornea and has the shape of a disc, for which this form is called discoid (Fig. 37). The disc is usually sharply defined, clearly delimited from the healthy tissue of the cornea; it is located in its middle layers. Sometimes the disc is surrounded by two or three rings of infiltrated tissue. The rings are separated by light spaces. The corneal epithelium above the disc localization zone is edematous, exfoliated to the point of forming fairly significant bubbles. The endothelium of the posterior surface of the cornea undergoes the same changes.

The cornea in the affected area is thickened. Sometimes the thickening is so significant that the opti-

cal section of the cornea changes its shape. From a crescent shape, it acquires the shape of a barrel, resembling to a certain extent the optical section of the lens. The anterior edge of such a section protrudes forward, and the posterior edge protrudes significantly into the anterior chamber.

The process is accompanied by the expressed folds of the descemet membrane. Over time discoid keratitis may lead to the development of deep, poorly vascularized areas on the cornea. The outcome of the process in terms of restoring normal visual acuity is rarely favorable.

In cases where herpetic corneal infiltrate ulcerates, a rigid corneal ulcer develops, often with festoon edges, called landcardlike. Healing of such an ulcer is extremely slow.

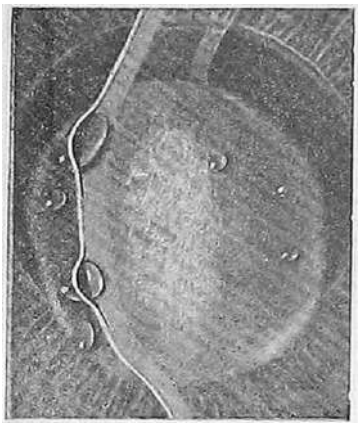

Fig. 37. **Discopid herpetic keratitis (optical section of the cornea)**

The clinical picture of metaherpetic keratitis deserves special attention. Metaherpetic keratitis is a specific form (transitional form) of the process, which develops from any clinical manifestation of viral herpetic keratitis against the background of weakened resistance of the organism and weakened immunity of the cornea. Most often, metaherpetic keratitis arises from dendritic or landscape-like keratitis. By the type of lesion, the metaherpetic form resembles the herpetic landscape-like clinical form, i.e. it has the appearance of a stromal ulcer of the cornea. It accounts for 30% of all herpetic keratitis. The difference from the landscape-like process is that the metaherpetic ulcer is deeper. The cornea around the ulcer is infiltrated and thickened. The epithelium against this background is edematous and bullous raised. The process is mostly accompanied by iridocyclitis.

Diagnosis of herpetic and metaherpetic keratitis, in the absence of typical features of the clinical manifestation of the process, can be very difficult. In these cases, it is necessary to resort to laboratory tests. The most common method is cytological examination of the conjunctiva and the method of fluorescent antibodies, which are de-

scribed in relation to the diagnosis of viral conjunctivitis.

Along the way it should be said that in herpes in the scraping the lymphocytes, plasma cells and monocytes are found.

Despite the obvious practical importance of the above laboratory diagnostic methods, they cannot satisfy the ophthalmologist in all cases. Therefore, the intradermal test with an antiherpetic vaccine has become increasingly used for diagnostic purposes. The vaccine is a preparation obtained from strains of the herpes simplex virus of the first and second types, inactivated by formalin. The active principle of the vaccine is specific antigens of the virus. The intradermal test has great diagnostic value in primary herpes in children.

0.05 ml of herpes polyantigen vaccine is injected into the skin of the forearm (inner surface), and the same dose of control antigen from uninfected material is injected into the skin of the other forearm. If after 24 hours the hyperemia of the skin that occurs in the zone of herpes polyantigen injection is 5 mm larger than on the control side, the herpes test should be considered positive. There is also a focal allergy test with the antiherpes vaccine, proposed by A.A.Kasparov. It is indicated as a diagnostic etiologic test for patients with frequent relapses of conjunctivitis, keratitis, iridocyclitis and other clinical forms of ophthalmic herpes, with sluggish processes. The test is very important because it is assessed by the presence of an exacerbation of the inflammatory process in the eye (increased pericorneal injection, pain, the appearance of new infiltrates in the cornea, precipitates, newly formed vessels in the cornea and iris).

These signs of an outbreak of the process require urgent active treatment: to strengthen desensitizing and specific antiviral therapy. Given the above, there are a number of contraindications to the test: an acute process in the eye, the presence of infectious and allergic diseases, diseases of the endocrine system, tuberculosis, kidney diseases. A focal test, which in some cases can also cause a general reaction, should be carried out only in a hospital setting.

The focal test technique consists of introducing 0.05-0.1 ml of antiherpetic vaccine into the skin of the forearm. If the above signs of exacerbation of the process in the eye are absent after 48 hours, then the injection of the drug is repeated in the same dose after one or two days.

The diagnostic value of the focal test is 28-60%, which apparently also depends on the localization of the inflammatory process in the eye membranes. For the sake of objectivity, it should be noted that the test is considered positive not only in the case of an exacerbation of the inflammatory process, but also in the presence of an improvement in the condition of the eye, which is determined by using a number of ophthalmological techniques, starting with the biomicroscopy method and ending with methods for studying visual acuity, perimetry, campimetry, and others.

The most evidence-based method of etiological diagnosis of herpetic keratitis is an experiment with a vaccine on the rabbit's cornea or the introduction of the material taken in the form of a scraping from the affected human cornea in the mouse brain. The development of herpetic keratitis in a rabbit or the occurrence of encephalitis in the mouse indicates viral infection.

Significant difficulties are presented by the diagnosis of viral iridocyclitis occurring in isolation, without clinical symptoms from the cornea. It should be said that the role of viral infection in the pathology of the vascular tract has not been sufficiently studied.

It is believed that patients with herpetic iridocyclitis make up 17-25% of the total number of patients with iridocyclitis. The infectious agent can penetrate into the eye in two ways: from the outside through the corneal epithelium, into the stroma and then into the uveal tract, and hematogenously.

It is known that the herpes simplex virus can be latent in the eye tissues for a long time, manifesting itself at high virulence or under the influence of provoking agents.

Young people and children are more often affected. In 17% of cases, iridocyclitis is bilateral and relapses in 50% of cases (A.A.Kasparov, 1976).

The development of iridocyclitis is usually preceded by factors characteristic of ophthalmic herpes: fever, hypothermia, the appearance of herpetic rashes on the skin and mucous membranes of various parts of the body. Iridocyclitis often occurs in an eye that has had herpetic keratitis in the past.

Among the clinical manifestations of herpetic iridocyclitis, as with other types of iridocyclitis, acute and sluggish forms can be distinguished.

The acute form is observed less frequently. It is characterized by sharp pain, pronounced injection of mixed character, fibrinous effusion into the anterior chamber.

The sluggish clinical form, observed much more often, is distinguished by mild pain, or even its complete absence, a small injection of the eyeball (the eye is almost calm). It is characterized by the appearance of large precipitates of a greasy type, fibrinous deposits on the posterior surface of the cornea, the appearance of herpetic granulomas in the iris with subsequent tissue atrophy in the places of their localization. In this case, the iris in the affected areas becomes thin, discolored, acquires a mottled appearance.

When the granuloma is localized in the area of the pupillary margin, stromal posterior synechiae occur. The pupil is resistant to the action of mydriatics. The process is accompanied by active fibrinous effusion into the vitreous body, with the development of pronounced opacities.

During iridocyclitis, the complicated cataract may develop, and, quite typically, a secondary increase in intraocular pressure with a decrease in the coefficient of ease of outflow of intraocular fluid and the appearance of gonioscopic changes. This is more often observed in the acute form of iridocyclitis.

Quite often, iridocyclitis occurs with hypervascularization of the iris and recurrent hyphema (Fig. 38). Practical experience convinces us that the hemorrhagic component in the general clinical picture of any iridocyclitis should always be alarming in terms of herpes infection: other pathogens of the process usually do not have such an ability to cause vascular reactions.



Fig. 38. **Herpetic ridocyclitis**

It cannot be said that the listed symptoms are pathognomonic for viral iridocyclitis. The same changes, expressed to one degree or another, are inherent in serous-fibrous iridocyclitis of tuberculous etiology, iridocyclitis developed on the basis of streptococcal infection, iridocyclitis of sarcoidosis nature.

Therefore, it is not easy to carry out the etiological diagnosis of herpetic iridocyclitis.

It is necessary to resort to searching for other symptoms, in particular, determining the sensitivity of the cornea, which in herpetic iridocyclitis is usually reduced. It helps to establish a characteristic cytogram of the conjunctiva, determined by scraping the conjunctival epithelium. A positive immunofluorescence reaction in the conjunctival epithelium is taken into account when using the appropriate antiherpetic serum. Finally, one should not forget about the possibilities of an intradermal test with an antiherpetic poly-vaccine. It has proven itself in cases of isolated iridocyclitis, with a sluggish course and relapses. When diagnosing this allergic reaction, one should remember the possibility, in the case of a herpes infection, of an exacerbation of the process, which will require the administration of desensitizing agents and increased antiviral treatment (see above).

With herpathic iridocyclitis changes in the central and peripheral nervous system, as well as in the visual field of both the injured and healthy eye, and a decrease in dark adaptation can be observed.

Herpetic infection from the iris and ciliary body can have direct spread along the anatomical continuation both anteriorly and posteriorly with the development of posterior corneal herpes and bullous herpetic keratitis, the development of focal chorioretinitis, optic neuritis, periphlebitis of the retina, secondary exudative detachment of the retina. However, it should be noted that the described pathology in herpetic infection does not carry any specific differential diagnostic features and can only serve as an aid in establishing an ethnological diagnosis.

Among the therapeutic factors for herpetic diseases of the conjunctiva, cornea, and anterior vascular tract, specific virusostatic drugs should be singled out. These include deoxyribonuclease, 5-iodine-2-deoxyuredinium (IDU), also known as kerecide in a 0.1% solution, used in the form of eye drops. The drug is a metabolite and has high antiviral activity. Its mechanism of action consists in influencing the deoxyribonucleic acid of the viral infectious agent. A solution of 5-iodine-2-deoxyuredinium in polyvinyl alcohol is called herplex. Both drugs (kerecide, herplex) are successfully prescribed in the form of drops for herpetic keratitis, but mainly in cases of superficial localization of the process.

At first, in our practice, we prescribed 5-iodine-2-deoxyuredin without any problems and for a long time, but then we came to the conclusion that it is not advisable to use it for more than ten days. The drug can have a toxic effect on the epithelium of the cornea and conjunctiva, causing follicular allergic conjunctivitis, punctate keratitis, and even the development of micropannus. IDU is not administered under the conjunctiva due to its toxicity.

A good virusostatic drug occurring without damaging the corneal epithelium, is oxolin. In solution, oxolin turned out to be unstable, therefore, it is used mainly in the form of a 100% ointment. Oxolin is a derivative of naphthalene. This is a white powder, in dry form it can be stored for up to two years. It is approved by the Pharmacological Committee of the Ministry of Health of the USSR for the treatment of viral eye damage. Oxolin, unlike keratsid, cures not only herpetic but also adenoviral keratoconjunctivitis.

The toxicity of oxoline is low. However, when prescribing it to patients, one should warn about the irritating effect of the drug (it has a dnonin-like irritating effect, causing a burning sensation, conjunctival hyperemia and even chemosis). However, this seemingly undesirable property of the drug contains a positive factor. Against the background of treatment with oxoline, due to its irritating effect, the resorption of inflammatory infiltrates in the cornea is accelerated.

Antiviral drugs play a major role in the treatment of herpetic keratitis: tebrofen, florenal in the form of ¼-½% ointment. In some cases, the use of florenal ointment causes a slight burning sensation in the eye, which the patient should also be warned about.

However, interferon and interferonogens made an era in the therapeutic effect on herpesvirus processes.

Leukocyte interferon is used in the same scheme as for viral conjunctivitis. For deep forms of keratitis, interferon can be used in the form of subconjunctival injections of 0.3-0.5 ml. The course of treatment usually prescribes 15-20 injections.

The effectiveness of the treatment of viral keratitis increases with a combination of interferon with kericide. Among interferonogens, pyrogenal has proven itself with wide application in practice. It is used in drops, drugs. A course of treatment consists of 5 to 20 injections of intramuscularly to the subconjunctiva of the eyeball. The lat-

ter methods of administration are preferable for deep keratitis and iridocyclitis. The drug has a fibrinolytic effect, slows down the cicatricial process.

Pyrogenal is used intramuscularly every other day by 25 MPD, then the dose increases by 25-59 MPD (the maximal single dose for adult is 1000 MPD). The treatment course is 10-30 intramuscular injections of pyrogenal. Intervals between the courses are 2-3 months. Pyrogenal is prescribed under the conjunctiva at 25-30-50 MPD 5 times a week.

A combination of subconjunctival injections of pyrogenal with gamma globulin at 0.2 daily or every other day should be assessed positively. A course of treatment consists of 25 injections of both interferonogen (according to A.A. Kasparov).

Antiviral treatment gives the best results if it is carried out against the background of desensitizing drugs (diphenhydramine, calcium preparations), including locally - in the form of drops.

Naturally, the most active antiallergic agents are corticosteroids (0.5% hydrocortisone suspension, 0.5% cortisone emulsion, 0.1% prednisolone solution, 0.1% dexamethasone solution). However, their use in viral infection of the cornea should be treated with extreme caution. By reducing the inflammatory reaction, these drugs inhibit the formation of antibodies and slow the production of endogenous interferon, thereby inhibiting epithelialization and scarring of the cornea affected by the herpes simplex virus. It has been proven that when treating herpetic keratitis with prednisolone in an experiment, the virus remains in the tissue longer than without treatment.

In our practice, against the background of intensive cortisone therapy, when the drug was administered under the conjunctiva, there were cases of descemetocele of the cornea. Therefore, cortisone preparations should be prescribed only in drops for keratitis that occurs without intensive disintegration of corneal tissue, better against the background of gamma globulin in drops or under the conjunctiva, since it increases the level of antiviral immunity. In iridocyclitis, corticosteroids can also be administered under the conjunctiva, but do not get carried away with them and monitor the intraocular pressure.

In patients receiving steroids for a long time, pneumococcus may join the herpes virus, as evidenced by the appearance of a yellow tint in the corneal infiltrate. In this case, it is advisable to prescribe 10% sodi-

um sulfacyl, 1% tetracycline ointment or 1% erythromycin ointment.

A more favorable course of herpes infection is undoubtedly facilitated by the administration of vitamins of groups A and B, aloe extract, and novocaine blockade.

An old method of autohemotherapy in the form of the instillation of autoblood or its introduction sub-conjunctively in order to raise the antibody titer in the diseased eye is available to all ophthalmologists. This treatment can be prescribed 2-3 weeks after the onset of the disease when the titer of antiviral antibodies in the patient's body increases.

Treatment of the same profile is the use of anti-measles gamma globulin, which, given the widespread infection of the population with the herpes simplex virus, also contains antibodies to this pathogen.

Gamma globulin can be prescribed in the form of intramuscular injections of 1.5-3.0 ml 3 times with a break of 4-5 days, in the form of subconjunctival injections of 0.2-0.5 ml every other day and in the form of drops.

The drip method of treatment is naturally preferable for superficial keratitis, and the introduction of gamma globulin under the conjunctiva or intramuscularly is more advisable for deep localization of the infectious process in the cornea, iris and ciliary body.

In the treatment complex of herpetic diseases of the eye, for the purpose of a more active introduction of medicinal substances and the use of the neurotrophic effect of direct current, it is useful to use medicinal electrophoresis through a bath, closed eyelids or endonasal. Aloe, adrenaline, atropine, vitamin B1, heparin, hydrocortisone, lidase, novocaine, calcium chloride can be administered by electrophoresis. The medication, depending on the indications, is selected by the attending ophthalmologist, and as for the method of administration, the initiative belongs to the physiotherapist, who takes into account the possibility of electrophoresis of a given medicinal substance by one method or another.

Since the choice of preparations for their electrophoretic introduction must be strictly justified, we consider it necessary to characterize some of them. In particular, aloe extract should be prescribed during regression of the herpetic process, with the aim of resolving corneal opacities. Aloe, vitamin B1 and novocaine are indicated for the purpose of improving the trophism of the diseased tissue, in particular for accelerating corneal epithelialization.

Heparin is introduced to activate the herpetic process of cupping since it inhibits the growth of the virus in the tissue culture. Hydrocortisone as well as lidase contributes to the infiltrate's absorption, more delicate scarring of tissue, reducing neovascularization.

Patients with ophthalmic herpes are treated with diadynamic currents, microwave ultrasound therapy and phonophoresis of drugs, in particular interferon and dexamethasone.

Patients with herpes of the eye are treated with diadynamic currents, microwave ultrasound therapy and phonophoresis of medicinal substances, in particular interferon, dexamethasone.

Particular attention should be paid to the possibilities of surgical treatment of herpetic keratitis. These include cryoapplication, which is very popular among ophthalmologists and is performed not only in hospitals but also on an outpatient basis. It is performed under instillation anesthesia with a 1% solution of dicaine, every other day. Up to 10 procedures are prescribed for a course of treatment. The exposure time of tissue freezing is 7 seconds, the tip is removed during the defrosting period.

Some ophthalmologists are attracted to the trepanoneurotomy operation. After anesthesia, a trephine is installed on the area of the herpetic lesion of the cornea. Circular movements of the instrument are used to perform non-penetrating trepanation of the cornea (without removing the disk), after which more rapid healing of the lesion and its epithelialization are observed.

The method prevents the formation of persistent and gross corneal opacities.

In the case of corneal perforation, layer-by-layer keratoplasty has to be performed. Unfortunately, this measure does not contribute to the prevention of keratitis relapses. Relapses occur more often in the area of the border ring of the transplant. The successes of recent years in the problem of corneal transplantation based on microsurgical techniques, the development of seamless methods of fixing the transplant using bioglue (gamma globulin) or a soft hydrogel contact lens have made keratoplasty the main method in the treatment of herpetic corneal lesions occurring with tissue decay. The method is available to almost all ophthalmic surgeons. Particularly captivating is the use of a 10% or 50% solution of anti-measles gamma globulin for the purpose of fixing the donor's cornea, which, as mentioned above, increases antivi-

ral immunity. Some surgeons have recently begun adding leukocyte interferon to gamma globulin to enhance antiviral protection.

Sometimes in practical work, there is a need for surgical intervention on the eyeball that has suffered a herpetic infection in the past. In this case, after the outbreak of inflammation, it is necessary to wait 3-4 months. Before the intervention, it is advisable to use interferon in combination with some.

In recent years, laser argon coagulation has been used in the leading clinics of the country for herpetic corneal ulcers, creating a temperature in the radiation exposure zone of up to +70 °. Laser coagulation promotes more gentle scarring and has a virustatic effect.

Experimental investigations have proven that the therapeutic efficiency of laser coagulation exceeds IDU and cryotherapy reducing the treatment of the patient two-three times. Laser coagulation also justifies itself in cases of drug-resistant forms of ophthalmic herpes.

It should be noted that even after successful treatment of severe herpetic keratitis, a decrease in corneal sensitivity, weakness of the epithelial cover of the diseased cornea, and sometimes its rejection are observed for many years afterwards.

Treatment of such successive conditions, called postherpetic epithelial pathologies, has not yet been properly developed. Vitamins A and B, cryoblowing, electrophoresis with novocaine, lysozyme in drops, and laser coagulation are indicated. It is inappropriate to prescribe antiviral drugs in these cases.

Complex treatment of patients with ophthalmic herpes, according to the materials of the V All-Union Congress of Ophthalmologists (1979), leads to positive results in 95% of cases. However, every ophthalmologist knows that stopping the herpetic process does not mean a complete cure with a guarantee of the absence of possible relapses of ophthalmic herpes.

Therefore, prevention of relapses of the disease, issues of prophylaxis occupy an important place in the problem of herpetic eye disease. Despite clinical recovery, the presence of latent herpetic infection in the body dictates the need to exclude unfavorable influences of the external environment. Extremely dangerous are hypothermia of the body, colds, eye injuries, physical and mental overstrain, in a word, all factors that contribute to a decrease in the body's resistance, antiviral immunity.

In case of frequent, sometimes annual, relapses of herpes of the eye, mainly keratitis, the use of antiherpetic poly-vaccine is indicated. Treatment should never be started in the acute period of the process. After all clinical signs of keratitis have disappeared, one should wait one month, and only then start the vaccination course. This is due to the fact that even when vaccination is carried out in the "cold", i.e. inter-relapse period, exacerbation of keratitis is possible, which requires interruption of vaccination and prescription of desensitizing and antiviral treatment.

The method of antirecurrent therapy consists of intradermal administration (on the inner surface of the forearm) 0-1-0,2 ml of polyvaccine with the formation of a papule with a “Lemon crust”. They make five injections with the interval between them in two days. The first course of vaccination should be carried out in the stationary, the subsequent ones after 3-6 months (during the first year) can be carried out on an outpatient basis. Further, the courses are held only outpatiently every 6 months.

The preventive measure of the next possible relapse of keratitis is the installation of interferonogens.

A large role in the fight against various clinical manifestations of the eye pathology belongs to the dispensary service (all patients with the frequent recurrences of disease must be under dispensary observation).

For practicing ophthalmologists, it is no less important to know about another herpetic infection of the eye and its appendages, called shingles (herpes zoster). This name is apparently due to the fact that the disease involves a certain zone in the process, most often the branching zone of the intercostal nerves, which seem to encircle the human chest. The disease belongs to the category of cutaneous diseases, occurring with pronounced neuralgic pain syndrome, which is explained by the tropism of the virus to the nervous tissue and skin. Research in recent years has revealed that the neurodermotropic filterable virus, discovered in 1911, has two types, which determine the clinical picture of shingles and the clinical picture of a childhood disease - chickenpox. The cases of children becoming infected with chickenpox from those with shingles have become clear. However, the opposite phenomenon is not observed. In addition, children almost never get shingles.

The incubation period of shingles is two weeks, the disease occurs more often in the transitional

season (autumn or spring), leaves behind a strong immunity, practically without recurrence. The factors that provoke shingles include any infectious disease, trauma, intoxication, exposure to chemicals, food, medicinal agents, especially with an allergic reaction to them.

The disease is preceded by a prodrome in the form of lethargy, apathy, headache, and an increase in body temperature. Following this, in a certain area (the zone of the belt, semi-belt), depending on which intervertebral ganglion and the nerve trunk extending from it are affected (most often this is the third or seventh nerve), hyperemia of the skin appears, its swelling with the formation of papules and vesicles. Vesicles usually do not open. They can be filled with pus, blood. Later, crusts appear in place of the vesicles, falling off by the end of the third week.

In the place of papules and vesicles there are dents (ospins) like those that are observed in children who have suffered chickenpox. The skin in the locations of the lichen elements is excessively pigmented or vice versa is depigmented. The process is accompanied by severe neuralgic pains combining with severe hypostasy or skin analgesia in the lesion area.

Herpes is characterized by the location of the rash only on one side of the body without moving to the other. The same applies to the defeat of the ophthalmic nerve, which is the first branch of the trigeminal nerve, which occurs in 10% of cases of herpes zoster of other localizations. The process develops in the branching zone of the ophthalmic nerve (skin of the upper eyelid, forehead, temple and scalp to the midline) (Fig. 39). In 50% of cases, i.e., in almost every second patient with ophthalmic localization of herpes zoster, the eye becomes ill. Herpetic conjunctivitis, keratitis, iridocyclitis may occur.

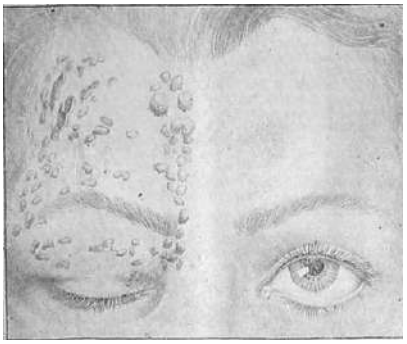

Fig. 39. **Herpes zoster of the orbital localization**

This is due to the fact that certain branches of the nasociliary nerve (namely the long ciliary nerves), which arise as a result of the branching of the ophthalmic nerve trunk, perform the function

of sensory and trophic innervation of the cornea, iris and ciliary body, penetrating into the optic nerve through the sclera into the perichoroidal space. When these branches are involved in the inflammatory process, a clinical picture of herpetic keratitis arises, sometimes iridocyclitis, bearing the features characteristic of keratitis and iridocyclitis in infection with the herpes simplex virus.

It is very interesting that a knowledgeable clinician can predict the possible spread of herpes zoster to the eye tissue. To do this, it is necessary to closely monitor the condition of the skin located in the area of the inner corner of the eyelids and under the inner commissure of the eyelids. The fact is that the sensitive innervation of these skin areas is carried out by the infrablock nerve, which, like the long ciliary nerves, departs from the nasociliary trunk. The appearance of hyperemia of the skin, its infiltration in the indicated zones, the rash of herpetic elements here indicates the involvement of the infrablock nerve in the process, after which the long ciliary nerves are usually affected with the manifestation of pathological changes in the cornea, iris and ciliary body.

In case of orbital localization of lichen, the ophthalmologist should coordinate actions with a neuropathologist and dermatologist to prescribe general treatment. To relieve pain syndrome a 50% solution of analgin is usually prescribed in injections by 1.0-2.0 ml intramuscularly. The use of broad-spectrum antibiotics, intramuscular vitamin B1 every other day, alternating with 200 mcg of vitamin B12, is recommended. The herpes area should be treated with an interferon solution.

Local treatment of keratitis and iridocyclitis is the same as for treatment of herpes simplex.

Timely measures, strengthening of antiviral and desensitizing therapy, instillation of exogenous interferon and interferonogens into the conjunctival cavity can prevent the development of a viral infection in the eye.

In the process of curing a patient with shingles, it is necessary to remember the need to isolate children from him, since, as stated above, the shingles and chickenpox viruses are almost identical in many characteristics.

As for herpetic chorioretinitis, optic neuritis, the absence of sufficiently clear clinical signs characterizing these diseases in accordance with their herpetic nature did not allow us to include their description in this book.

SECTION IV

DAMAGE TO THE ORGAN OF VISION

Damage to the visual organ is one of the most pressing problems in modern ophthalmology. Eye trauma is of interest to ophthalmology doctors at any level, as it occurs quite frequently, accounting for up to 30% of all injuries. Eye trauma is the main cause of visual disability, which is why the problem is of great importance not only from a medical point of view but also from a social perspective.

The chapter "Complications of the wound process and contusion of the eyeball" includes data related to the clinical picture and possibilities of modern treatment of traumatic iridocyclitis, purulent intraocular infection, secondary posttraumatic glaucoma and retinal detachment. Sympathetic ophthalmia is presented from the modern positions of the immunological theory of its origin, which determined the appropriateness of the immunosuppressive component in the treatment complex of this severe complication.

Special attention is paid to emergency care and treatment measures for mechanical injuries of the eyeball. These materials indicate measures to prevent intraocular infection, methods of conservative treatment in the post-traumatic period, taking into account the possibilities of modern pharmacotherapy and the latest achievements in ophthalmology.

The major role of the vascular factor in the mechanism of blunt trauma, which determines the features of its therapy, is emphasized. Due attention is paid to the work of trauma centers created in our country and their multidisciplinary activities.

Brief information is given on the organization of dispensary observation of persons who have suffered damage to the organ of vision, which serves as a prevention of complications, and thereby determines the outcome of the injury.

Based on clinical observations and the experiment, taking into account the pathogenesis of the identified disorders, a set of measures to prevent eye injuries in some branches of chemical production is given. Microsurgery of penetrating wounds and contusions of the eye-

ball is presented in the corresponding section "Propaedeutics of Eye Microsurgery". This is explained by the need to precede the special section of trauma microsurgery with coverage of general issues related to the basics of eye microsurgery as such, microsurgical equipment, instruments and technical methods, knowledge of which is necessary for mastering microsurgical assistance in case of eyeball injury.

Chapter 1

PENETRATING INJURIES OF THE EYEBALL

Penetrating injuries of the eyeball are the leading problem of modern ophthalmotraumatology. Despite significant achievements in this area and enormous preventive work, the number of severe injuries of the eyeball, which include penetrating injuries, remains high.

Penetrating eye injuries account for 40-60% of all eye injuries (according to hospital data). Not only do they account for a large proportion of the overall structure of eye morbidity (6-7%), but they are also characterized by severe outcomes; 30% of visually impaired people are individuals with consequences of penetrating wounds to the eyeball.

Familiarization with literary sources allows us to trace the following: at the beginning of the century, issues of intraocular infection and sympathetic ophthalmia were widely covered; then the problem of intraocular foreign bodies was on the agenda; in the fifties, a number of major works were devoted to morphological studies and the search for the optimal option for treating penetrating wounds of the eyeball. Now the organization of emergency care, the use of the most effective methods of diagnosis and treatment, and timely medical rehabilitation are relevant. This is how the main directions were defined by the V All-Union Congress of Ophthalmologists (N.A.Puchkovskaya, 1979).

But in any case, no matter what issues of this problem we touch upon, the basis of the basics for a practicing physician is knowledge of the clinic and modern diagnostic capabilities of penetrating eye wounds. This ensures the choice of the correct tactics of the ophthalmologist, rational therapy and correction of complications.

According to the location of the wound, all of the penetrating wounds are divided into corneal,

which account for about 50%, corneoscleral and scleral, which have approximately the same frequency. In addition to the above, it is customary to distinguish penetrating wounds with prolapse or infringement of the membranes of the eyeball, with traumatic cataracts, with an intraocular foreign body, and wounds complicated by intraocular infection. All these details should be well known to the practicing physician since these concepts are included in the content of a detailed clinical diagnosis.

In presenting the issues of classification of penetrating wounds in peacetime, it is necessary to note the peculiarities of modern trauma according to the conditions of its occurrence.

Industrial injuries in industry, despite some tendency to decrease, remain to a significant extent severe and in recent years have been distinguished by the fact that intraocular foreign bodies are often amagnetic or weakly magnetic (plastics, high-quality alloy steels). Diagnostics of such foreign bodies (including X-ray) and especially their removal are difficult.

Agricultural industrial injuries (in some regions, they account for 40% of all damage to the organ of vision) are approaching industrial ones in their nature under conditions of mechanized labor: the number of intraocular infections has decreased, but the number of injuries complicated by intraocular foreign bodies has increased.

Domestic injuries still account for a high percentage of eyeball injuries (up to 55%), and not only in adults but also in childhood.

Transport injuries, as a rule, are a combination of penetrating wounds of the eyeball (or contusion) with damage to the eye socket, skull bones, limbs, and vital organs. Severe injuries are typical for penetrating wounds of this kind: crushing of the eyeball, extensive cut wounds of the cornea and sclera, amagnetic intraocular foreign bodies (glass). Severe and especially severe injuries are inflicted by the horns of animals (elk, deer), which often go out onto highways; this has recently been reported in domestic and foreign ophthalmological literature.

Sports injuries such as penetrating wounds of the eyeball are, as a rule, the lot of "unorganized" athletes and are generally rare. Usually, the adnexa of the eye is damaged or contusions of the eyeball occur in sports such as boxing, skiing, football, and hockey.

The clinical picture of a penetrating wound of the eyeball is determined by a number of factors,

among which the localization of the wound and its size are very significant. As a rule, extensive wounds do not cause difficulties in diagnosing a penetrating wound. However, small wounds with well-adapted edges, especially in the limbus or sclera, cause significant difficulties and, as clinical experience shows, are sometimes not diagnosed in a polyclinic setting. Therefore, we consider it appropriate to recall the main clinical manifestations of a penetrating wound of the eyeball.

There are absolute signs indicating that the injury to the eyeball is penetrating. These include: a wound that goes through all layers of the cornea, sclera or corneoscleral zone; pinching of the internal membranes and vitreous body in the wound; intraocular foreign body; traumatic coloboma of the iris; air bubble in the vitreous body. All other signs are considered relative. They can be present in other types of injuries and various diseases. However, a combination of relative symptoms and their combination with the anamnesis sometimes allows us to confidently diagnose a penetrating injury to the eyeball.

The group of relative signs includes: hemorrhage into the vitreous body and anterior chamber, fibrin effusion into the anterior chamber, changes in its depth (most often the chamber becomes shallower), damage to the lens capsule and localized clouding of the lens substance, and ocular hypotension.

A penetrating wound is usually accompanied by photophobia, lacrimation and injection of the eyeball, however, with small wounds, especially scleral ones, complaints are minimal, and sometimes completely absent.

Eye pain accompanies extensive wounds and most often corneal or scleral, respectively, in the ciliary body zone. The visual functions of the eye depend on the location of the wound, the presence of blood in the anterior chamber and vitreous body, the degree of transparency of the lens and the involvement of the retina and optic nerve. Penetrating wounds of the eyeball, unlike penetrating ones, have not only an entrance but also an exit hole. Their frequency is insignificant - about 8% of the total number of penetrating wounds.

Most penetrating wounds are of an industrial nature and are accompanied by the presence of a foreign body in the orbit. The entrance hole is most often located in the anterior segment of the eyeball, determining the exit hole is often

difficult due to the opacity of the optical media of the eye.

In penetrating wounds, as well as in penetrating wounds of the eyeball, the ophthalmological literature distinguishes between absolute and relative signs.

A penetrating wound in the anterior part of the eyeball with a simultaneous exit hole, determined by external examination or ophthalmoscopy, is an absolute sign of a penetrating wound. In addition, a strong confirmation of the diagnosis is the combination of a penetrating wound of the eyeball with a foreign body located behind the eye in accordance with the course of the wound channel in the membranes and tissues of the eye.

However, it is often difficult to diagnose a penetrating wound, especially with small foreign bodies. This is due to the fact that when they exit the eyeball, they do not leave behind a large exit hole. The hole is closed by a blood clot and edematous tissues, which immediately exclude hypotension, typical for the clinical picture of a penetrating wound. In addition, small foreign bodies have little penetrating ability, so they usually remain near the exit hole or even partially in the eye membranes, creating enormous diagnostic difficulties during radiographic examination. Clinical experience shows that, as a rule, penetrating wounds with large entrance and exit holes are rare. Patients with so-called borderline situations are mainly admitted to the hospital - the foreign body is radiographically determined at the posterior pole of the eye. And only careful X-ray localization in combination with ultrasound echography, determining the true size of the eyeball allows us to determine where the foreign body is: in the eye - parietal, wedged in the membranes, or the foreign body is outside the eye. For obvious reasons, such differentiation is necessary, since it determines the surgeon's tactics.

In percentage terms, this type of particularly severe injury is rare, accounting for about 1% of the total number of penetrating injuries to the eyeball. The fate of a crushed eye is clear - this injury is incompatible with the life of the eye as an organ, and in this case, primary or preventive enucleation is needed. However, it is sometimes difficult to decide on the nature and severity of the injury during an external examination. The ophthalmological literature provides a number of clinical examples when, with the apparent destruction of the eyeball at first glance, it was not only possible to preserve it but also to ob-

tain normal vision. Only an ophthalmologist, during surgical treatment, can diagnose crushed eyeballs and perform primary enucleation. A general surgeon should not decide the diagnosis, much less perform enucleation, although the destruction of the eyeball is often encountered in trauma combined with damage to the face and skull, and it is surgeons and traumatologists who provide first aid to victims. Biomicroscopy plays a major role in the diagnosis of penetrating wounds of the eyeball. Slit lamp examination is especially necessary for small wounds of the eyeball when there are no other symptoms of penetrating injury.

In direct focal light, it is usually possible to trace the course of the wound channel in the cornea even with minimal puncture wounds. It is possible to determine whether the wound passes through Descemet's membrane or ends blindly in the layers of the cornea, i.e. the wound is non-penetrating.

The damage to Descemet's membrane and corneal endothelium should be clarified in a mirror field.

Certain difficulties are caused by oblique corneal wounds when the edematous and infiltrated anterior layers of the cornea do not allow a clear view of the posterior sections of the wound channel. The presence of folds of Descemet's membrane around the wound can serve as a landmark for a penetrating wound.

The biomicroscopic picture of the wound channel of an incised corneal wound depends on the time elapsed since the injury. The wound channel is dark in the first hours, and over time it acquires a grayish color as a result of hydration phenomena; in addition, the wound channel has a cone-shaped appearance in the optical section due to the contraction of the elastic Descemet's membrane.

There are certain difficulties in diagnosing small limbal wounds with well-adapted edges, especially if the wound has a radial direction and seems to repeat the pattern of the palisade. The search for such wounds is facilitated by biomicroscopic examination in diffuse light with preliminary instillation of fluorescein into the conjunctival cavity - the wound area is then colored green.

To clarify the penetrating nature of the corneal and limbal wound, a test can be used by dropping a fluorescein solution onto the surface of the eyeball. In the case of a penetrating wound, where there is no complete adaptation of the edges (and this can

also happen with small stab wounds), a flow of fluid from the anterior chamber is observed in the form of a green trickle on a general yellowish-brown background.

Small penetrating wounds of the sclera are also difficult to diagnose. Their detection is facilitated by careful biomicroscopy in direct focal light. In this case, it is possible to detect a wound of the conjunctiva of the eyeball (sometimes only after staining with fluorescein) with lumps of pigment or a bubble of the transparent vitreous body, indicating the presence of a penetrating scleral wound.

Currently, there are numerous methods by which the presence and localization of a foreign body in the eye can be established. These are primarily conventional clinical research methods: biomicroscopy, ophthalmoscopy, gonioscopy. Ultrasound echography is becoming widespread. At one time, a large number of different subjective and objective tests were proposed, such as magnetic, pain, etc. Transillumination and research using metallophones are becoming well-known. However, one of the main methods in the diagnosis of intraocular foreign bodies is considered to be the X-ray method in its various variants and modifications.

Since the section on X-ray diagnostics is the subject of special studies, it is usually presented in a separate course (E.S.Vainshtein, 1967). Nevertheless, every ophthalmologist providing assistance to patients with eyeball injuries should know the main indications for X-ray examinations and the modern capabilities of this method. X-ray examination allows detecting a foreign body in the orbit and resolving the issue of where it is located - in the eyeball or outside it. In addition, with the help of this method, it is possible to determine the shape, size and localization of an intraocular foreign body (its meridian, distance from the plane of the limbus, relation to the eye membranes).

Every ophthalmologist providing assistance to patients with eyeball injuries should know the main indications for X-ray examinations and the modern capabilities of this method. X-ray examination allows detecting a foreign body in the orbit and resolving the issue of where it is located - in the eyeball or outside it. In addition, with the help of this method, it is possible to determine the shape, size and localization of an intraocular foreign body (its meridian, distance from the plane of the limbus, relation to the eye membranes). X-ray examina-

tion helps in resolving the issue of the mobility of a foreign body and its physical nature.

At present, all patients with penetrating wounds of the eyeball and those who have clinical data and anamnesis indicating the possibility of penetrating wound, undergo mandatory X-ray examination. This is the installation of modern ophthalmotraumatology.

Two overview images of the orbits (anterior and lateral) are mandatory, and it is advisable to take the frontal image with the patient face down. In addition, a third image is necessary - a skeletal-free image according to the Baltin method, which allows obtaining an image of the anterior third of the eyeball outside the bony orbit. Based on these overview images (of both orbits), they judge the presence of a foreign body in the orbit and approximately decide on its localization in the eyeball.

In a number of clinics, the method of X-raying the orbits in axial projection is widely used.

This image is taken in addition to the overview (frontal and profile) images when the foreign body is detected only in one plane.

Traditional methods of diagnosing intraocular foreign bodies in the anterior part of the eyeball include skeletal-free radiography using the Vogt method. However, it can be used no earlier than 7-10 days after a penetrating injury, since the introduction of a film into the conjunctival cavity is a traumatic procedure that does not always ensure proper sterility.

However, such standard methods do not always allow the detection of a foreign body.

Clinically, there are known examples when a foreign body visible ophthalmoscopically or biomicroscopically is not detected on an X-ray. This depends on many reasons, in particular, on the atomic weight and mass of the foreign body. Therefore, new methods of X-ray examination are being developed and created, allowing the diagnosis of small-sized and low-contrast foreign bodies, as well as multiple foreign bodies. These primarily include tomography using a simultaneous cassette, which was proposed by Professor E. S. Weinstein. The tomographic technique is not only not inferior, but sometimes surpasses standard methods in identifying and localizing small, low-contrast and multiple foreign bodies.

It is now possible to use non-contact radiography in pediatric practice, as well as stereo radiography and tele-radio-video recording methods for multiple foreign

bodies. However, these delicate and sometimes technically complex methods of radiological examination are used only in specialized ophthalmological institutions at the level of research institutes, since they require complex equipment and technical equipment.

Most eye departments and hospitals use only traditional standard methods of X-ray examination to detect intraocular foreign bodies: overview images of the orbits in two mutually perpendicular planes (frontal and profile), as well as skeletal images according to Valtin and Vogt.

The images should be analyzed by an ophthalmologist immediately before the film dries, but they should be carefully examined again in a dry state. If a foreign body is detected in the images, which can presumably be located inside the eye, it is necessary to perform X-ray localization of this foreign body. The most common method of X-ray localization of a foreign body in the eye is the Komberg-Baltin method. It is simple to perform and not complicated in calculations. However, this method cannot be recognized as fully satisfying the requirements of modern ophthalmotraumatology. This is due to the fact that the calculation is carried out on the basis of a schematic eye, therefore, in a number of cases, without additional determination of the true dimensions of the eyeball, it is impossible to obtain an accurate localization of the foreign body, especially when it is located in the "border" zone, i.e. near the wall.

In addition, if the foreign body is mobile and is located in the visible body, then in the images in two mutually perpendicular planes there may be a discrepancy in the position of the foreign body due to its displacement when turning the head by 90°. The disadvantage is the very fact of applying an aluminum prosthesis to the eyeball - in the case of extensive wounds, such manipulation is not indifferent to the injured eyeball, and is sometimes even contraindicated.

X-ray localization of foreign bodies using the Komberg-Baltin method is described in detail in textbooks and monographs. Its principle is familiar to every ophthalmologist who provides assistance to patients with penetrating wounds of the eyeball in a hospital. At the same time, we consider it appropriate to dwell on some details of the method and the main errors that are made by ophthalmologists working in hospitals where there is no specialized ophthalmology service and where ophthalmologists independently "read" the images and carry out all the calculations.

The Komberg-Baltin prosthesis should be inserted into the conjunctival cavity after its disinfection with alcohol and ether (preliminary instillation anesthesia with a solution of dicaine is performed) and removed by an ophthalmologist, not entrusting this manipulation to an X-ray technician.

It should be remembered that if a lateral image with a prosthesis is always taken with the patient's damaged eye facing the cassette, then a frontal image is taken both face down (similar to a survey image) and face up (we recommend the latter option). Taking this into account, the distance from the X-ray tube to the cassette should be changed: for a lateral and frontal image face down - 60 cm; when the patient is facing up, the distance for a frontal image increases to 90 cm.

This situation should also be taken into account when choosing Baltin templates for calculation - small schemes are suitable for lateral and front face-down images, large ones - for front face-up images, since on the film, due to the greater divergence of X-rays, the image of the eyeball and the foreign body is enlarged.

It is known that the meridian of the foreign body and its distance from the anatomical axis are determined from the front image. The third, often the most significant indicator for the surgeon is calculated from the lateral images - the distance of the foreign body from the plane of the limbus. In order to avoid erroneous data, you must remember the following: when superimposing a lateral scheme on a picture, the limbus line of the scheme must be placed behind the marks of the Baltin prosthesis, since the prosthesis and its marks are on the surface of the eyeball, i.e. in front of the limbus.

In cases where the position of the prosthesis on the eyeball or the fixation of the gaze is not quite correct, a divergence of the marks at 3 and 9 o'clock appears on the lateral radiograph. If this has a small vertical divergence, then the calculations should be based on the median distance between the marks. A divergence of the marks horizontally (more than 1 mm) is unacceptable, since an error in calculating the distance of the foreign body from the plane of the limbus is possible: then the image should be repeated.

There are several methods for determining the true size of the eyeball. Among them, the method of E.S.Vainshtein with the definition of the contour of the eyeball on a lateral X-ray image (a lead plate is used) deserves attention. A number of authors have developed special measuring schemes, including the Polyak grid. But the most convenient, simple and, most importantly, sufficiently accurate method for

determining individual eye sizes is ultrasound echography. Eye biometry is carried out using the domestic echo-ophthalmograph "ECHO-21"; the data obtained are used for final calculations of the position of the foreign body.

Thus, knowing the localization of the foreign body using the Komberg-Baltin radiological method (meridian of occurrence, distance from the anatomical axis and the plane of the limbus), as well as the individual dimensions of the eyeball, established echographically (or in some other way), it is possible to clarify the true position of the foreign body.

It is necessary to dwell especially on the possibilities of ultrasound echography in penetrating wounds of the eyeball. In addition to the fact that ultrasound examination allows to clarify the true localization of a foreign body, which was mentioned, echography is used as one of the sufficiently accurate and independent methods of diagnosing intraocular foreign bodies or foreign bodies located in the orbit near the eyeball. Without dwelling on the details of the method, it should be said that echo diagnostics and echo localization are possible due to the fact that a foreign body gives an independent echo signal against the background of a normal standard complex of echo signals from the membranes and structures of the eyeball.

For diagnostic purposes, this method is needed, firstly, for foreign bodies of small sizes or radiolucent ones, which are not detected during an X-ray examination. Secondly, ultrasound echography allows one to independently determine and specify the localization of a foreign body located in the lens, anterior or posterior chambers, ciliary body, and also near the membranes of the posterior pole of the eye. Data on the location of the fragment at the posterior pole may vary.

Accurate localization of an intraocular foreign body allows determining the optimal surgical option — the approach to the foreign body — diascleral, transvitreal or anterior. In addition to X-ray and ultrasound methods of diagnosing and localizing intraocular foreign bodies, the transillumination method can be of invaluable help, for which a number of special devices and several options for transscleral and transcorial diaphanoscopy have been proposed. The use of a conventional diaphanoscope, due to the low brightness of the incandescent lamp, is difficult in hemophthalmos, as well as when localizing a fragment in the ciliary body area. Recently, special diaphanoscopes with fiberglass light guides have been developed; they

are produced by the domestic industry (serial illuminator for fiber-optic instruments "OS-250"). The ability to use powerful light sources and a large illumination area are the main advantages of modern transillumination with fiber optics.

Undoubtedly, an important issue in ophthalmotraumatology is the clarification of the magnetic properties and mobility of an intraocular foreign body. Knowledge of these qualities of a foreign body determines the surgeon's tactics as a whole and the choice of the method for removing the fragment. The relevant manuals describe in detail numerous tests that have found clinical application at different times. These are magnetic tests for fragment displacement, "adhesion", pain, and a test for moving a clinically invisible fragment (radiographic). However, these tests should be treated critically, since they may cause additional damage to the eye tissue and hemorrhages. Less safe is the Geilikman test. When the patient's head is in the ring of a magnet-solenoid, ophthalmoscopy is performed and the electric current is simultaneously turned on and off; the magnetic foreign body is slightly displaced at this moment. However, the test is only possible with transparent optical media, and this is its disadvantage. At present, modern ophthalmology has a number of other methods for detecting the magnetic properties of an intraocular foreign body. In addition to the Geilikman test used in the clinic, its modification has been proposed for opaque optical media, when instead of ophthalmoscopic control of the mobility of a foreign body, ultrasound echography is used. In a number of clinics, electronic locators are used for the same purpose, which changes the tone of the sound when a magnetic or amagnetic foreign body is detected.

The mobility of a foreign body located in the eye cavity can be determined by the method of ultrasound echography, recording the localization of the fragment in the patient's lying and sitting positions.

Summarizing the section on the diagnosis of intraocular foreign bodies, it should be emphasized that the leading role in solving the problem is the clinic, and the data of the main foreign body examination - X-ray, ultrasound and other additional instrumental methods should be assessed and interpreted taking into account the clinical picture. Such an approach to the analysis of information obtained as a result of a comprehensive examination of a patient with a penetrating wound of the eyeball will ensure accurate diagnosis, the choice of the correct surgical tactics and optimal therapy for the damaged eye.

The morphology of the wound process in the eye is presented in the system of postgraduate improvement of ophthalmologists for understanding the essence of the changes occurring in the tissues of the eye caused by penetrating injury. The process of healing wounds of the eyeball appears to be complex and, as experimental studies and clinical observations show, is not limited to a local reaction to trauma. Penetrating injury of the eyeball causes a change in the general reactivity of the organism.

In case of uncomplicated injury to the cornea and sclera, when the edges of the wound are adapted, the membranes of the eye are not pinched in the wound and there is no intraocular infection, the wound in the first hours is filled with fibrin, gluing its edges together, and wound healing, in this case, occurs according to the type of regeneration due to the proliferation of the corneal and scleral stroma cells without the participation of blood vessels, without the development of granulation in the wound channel.

However, in the case of gaping wounds or those complicated by strangulation and prolapse of membranes, the scarring process is carried out with the participation of vessels, excessive regeneration, i.e. by the fibrovascular type. Usually, this type of wound healing is accompanied by extensive adhesion in the eye cavity, ultimately leading to its subatrophy. Much credit for studying the wound process in the eye belongs to E.F.Levkoeva, whose morphological works largely served as convincing evidence of the need for careful surgical treatment with complete alignment of the edges of both the corneal and scleral wounds.

For completely understandable reasons, gaping wounds, as well as wounds with prolapsed membranes, are entry points for intraocular infection and epithelial ingrowth into the eye cavity.

It should be noted that this type of wound process, occurring with rough scarring and mooring, is currently the lot, as a rule, of severe extensive wounds.

Recent work has also made it possible to clarify the nature of the healing of iris wounds. The treatment of these wounds, along with iridoplasty in many clinical situations, has become possible due to advances in microsurgery. The iris tissue is capable of regeneration due to pigment epithelial cells and stromal elements; endothelial cells of blood vessels form new vessels.

Chapter 2

EYE CONTUSIONS

A contusion or bruise of the eye is an injury in which, unlike penetrating wounds, the integrity of the fibrous capsule of the eyeball is not violated. A contusion may occur as a result of the following causes: a blow to the eyeball with a blunt object, a bruise of the eye against some hard object, an impact with an air wave and general shaking of the body, bones of the skull and facial skeleton.

A contusion is considered direct when a blunt object directly affects the eyeball. Indirect contusion should include cases of damage to the eyeball with general damage to the body.

Blunt eye injuries are most often of a domestic nature (up to 75%), of which almost half occur in childhood (44%).

Dwelling on some issues of classification of contusion of the organ of vision, developed in detail and presented in the works of B.L.Polyak (1972), G.A.Petropavlovskaya (1975), V.V.Volkov, V.G.Shilyaev (1976), it is necessary to distinguish isolated injuries of the eyeball, as well as combined and associated eye injuries. Practitioners should be well aware of the possibility of combined injuries with the simultaneous impact on the eye of several damaging factors: mechanical blunt trauma, thermal and chemical exposure. Combined damage means simultaneous damage to the eye and other areas of the body by one factor.

Classification of contusion eye injuries by severity is quite difficult. This is due to the fact that at the first moment of blunt trauma when the diagnosis is clarified and the degree of damage is determined, it is extremely difficult to predetermine the subsequent course of the process and prognosis. Sometimes an outwardly insignificant injury to the eyeball ends in a serious outcome. In the classification of B.L.Polyak (1972), accepted by domestic ophthalmologists, three degrees of contusion severity are distinguished.

The mild group includes contusions of the eyeball with reversible changes in the tissues, which end in the restoration of vision. The average severity is characterized by minor anatomical damage to the tissues of the eyeball and moderate hemorrhagic syndrome; the decrease in vision as a result of the injury should not be lower than 0.5. Signs of a severe contusion are a rupture of the sclera, extensive damage to the iris, disruption of the integrity of the retina, massive

hemorrhages in the cavity and membrane of the eye, damage to the optic nerve, crushing of the eyeball. In addition, with severe blunt trauma, in some cases, hypertension of the eye occurs, and sometimes persistent deep hypotension. But these changes should most likely be regarded as a consequence of the contusion process in the eye, although in the classification of G.A.Petrovpavlovskaya, they are included in the group of direct signs of severe contusion.

For the completeness of the presentation of the classification scheme, it is necessary to recall that in the clinic, contusions of the adnexa of the eye (eyelids, conjunctiva, lacrimal organs) and the orbit are also distinguished. In addition to the clinical classification of contusions of the organ of vision, in practical activities, ophthalmologists often have to determine the severity of blunt injuries according to two, rather than three, gradations when it comes to "investigating and recording accidents at work."

The mechanism of contusion trauma is very complex, diverse and appears to be more polymorphic than with penetrating injury to the eyeball. Firstly, tissue damage occurs at the site of direct impact of a blunt object: compression, ruptures, displacement of tissue elements in relation to each other. The nature of these injuries depends largely not only on the force and direction of the blow but also on the anatomical structure of the membranes and tissues, their density and elasticity. Very typical for a contusion of the eyeball are also anatomical changes in the counter-blow zone, explained by the fact that the eyeball is an elastic spherical cavity filled with liquid. Sometimes the changes in the counter-blow zone are more pronounced than in the zone of direct injury.

Secondly, neuroreflex mechanisms play an important role in the development of post-contusion changes.

However, the third factor, vascular, closely related to neuroreflex, is especially pronounced, to a much greater extent than in penetrating injury.

Vascular spasm alternates with their expansion, the permeability of the vascular wall increases, and hemodynamics in the vessels of the eyeball changes. Such a vivid vascular reaction, along with anatomical changes in tissues, determines the diversity of clinical manifestations of eye contusion.

The above factors largely contribute to the long-term instability of ophthalmotonus and the diversi-

ty of ophthalmotonic reactions - from hypotension to high hypertension. This to a certain extent distinguishes contusion from penetrating injury to the eyeball.

Drawing a parallel between contusion and penetrating injury, it should be emphasized that contusion is a very prolonged process, and with apparent clinical recovery, it has not yet actually occurred. This is confirmed, in particular, by long-term fluctuations in intraocular pressure, as well as the reaction of the eye in the form of redness and pain in response to atmospheric influences, sudden changes in temperature, colds, severe physical exertion (for almost a year). Contusion of the eye is distinguished by a more pronounced general reaction of the body to the injury than with penetrating injury (headache, dizziness, vomiting) and a friendly reaction of the other eyeball. It is manifested by a change in the hemo- and hydrodynamics of the intact eye.

The prognosis for an eye contusion is complex and, in the figurative expression of Academician M.I.Averbakh, very reckless. The outcome of a blunt eye injury is influenced not only by the force, direction and nature of the blow but also by the patient's age, the presence of general vascular or concomitant eye diseases.

The impact of various pathophysiological mechanisms leads to secondary reactive and dystrophic changes in the tissues of the eyeball, which determine the outcome of the injury. When determining the tactics for treating patients with eye contusion, a practicing ophthalmologist must undoubtedly take into account all of the above.

The clinical picture of eyeball contusion is presented in the literature widely and quite fully. Dwelling on the main clinical manifestations, we mainly pay attention to those that either most often occur during contusion or are severe in their consequences.

In addition to pain in the injured eye and the corresponding half of the head, pain when palpating the eyeball, with a contusion, swelling and hematoma of the eyelids are often observed, leading to a narrowing of the eye slit. But this in no way reflects the severity of the damage to the eyeball itself. One of the most typical and obligatory signs of a contusion is a mixed injection of the eyeball, increasing in strength during the first day and gradually disappearing by the second week from the moment of injury. However, as has already been said, vasomotor instability persists

for a long time – up to a year – causing redness and discomfort in the injured eye with any physical exertion, general malaise, and heavy visual load.

This fact should be taken into account when giving work recommendations to the victim - heavy physical labor, active sports during the first year, especially after a severe contusion, should be limited.

From the side of the mucous membrane of the eyeball during a contusion, a reaction in the form of edema, subconjunctival hemorrhages, and also a violation of the integrity of the conjunctiva is possible. In principle, these are minor injuries, but their presence may indicate deeper changes - a rupture of the sclera. Therefore, the indicated symptoms, especially with simultaneous hypotension and a change in the depth of the anterior chamber, should alert the ophthalmologist and require active tactics - revision of the sclera in the area of damage to the conjunctiva to determine the integrity of the fibrous capsule of the eye.

The types of corneal damage in the contusion of the eyeball are very diverse. Most often these are erosions, which usually do not cause persistent visual impairment. Much less often, with damage to the endothelium, corneal opacities in the form of a disk are encountered; ruptures of the Descemet membrane and corneal dystrophy are also noted. A complete rupture of all layers of the cornea is described as an extremely rare type of injury. The most serious type is imbibition of the cornea by blood pigment and the subsequent appearance of "hematocornea". As a rule, it does not respond to therapeutic treatment, and the patient requires keratoplasty. The cause of this serious post-contusion complication is long-term or repeated hyphema.

According to the literature, approximately 60% of all eyeball contusions are accompanied by hyphema. Hemorrhage into the anterior chamber usually resolves quickly, but repeated hyphemas are possible. This occurs with early use of miotics, mydriatics, dionin, physiotherapeutic procedures against the background of deep vasculopathy, which is very characteristic of contusions. In the clinic, there are also known cases of changes in the transparency of the fluid of the anterior chamber due to fibrinous effusion, which is a transudate from the affected vessels of the iris and ciliary body; it quickly disappears.

Dwelling further on the pathology of the anterior chamber, we

will present possible options for changing its depth. Anterior displacement of the lens, as well as a rupture of the sclera in the area of Schlemm's canal, will lead to grinding of the chamber. Dislocation of the lens into the vitreous body, its subluxation in the posterior direction, rupture of the sclera under the rectus muscles are manifested by a deepening of the anterior chamber and iridodonesis.

The iris, due to the delicacy of its structure and its unique location, is very often subject to traumatic injuries. Being in the path of a shock wave from almost any direction, the iris takes the blow, resulting in either iridodialysis of varying degrees, up to complete detachment of the iris at the root, or ruptures of the sphincter of the pupil.

As a reaction to the trauma of the iris muscles and the nerve elements innervating them, mydriasis is typical in the clinical picture of contusion. It may decrease or completely disappear over time. Less common is persistent miosis. Mechanical damage to the vessels of the iris, causing hemorrhage into its tissue or the anterior chamber, is also possible. As a result of massive ruptures of the iris at the root, sphincter ruptures, and traumatic mydriasis, a significant decrease in central vision may occur.

Damage to the ciliary body in contusion is much more difficult to diagnose since it is usually accompanied by hemorrhage into the anterior chamber or vitreous body. However, ruptures of the ciliary body, cyclodialysis, and splitting of the ciliary body have been described, which leads to recession of the angle of the anterior chamber and subsequently to secondary post-contusion glaucoma. All of the listed changes, which occur as a result of mechanical trauma, are visible during gonioscopy. Gonioscopy allows us to detect damage not only to the ciliary body strip but also to other zones of the angle of the anterior chamber. In contusion, ruptures of trabeculae, blood in the Schlemm's canal, and small iridodialysis (Fig. 40) are found.

Literature data and our many years of clinical experience indicate that blunt trauma quite often damages the lens.

Pathology of the lens is expressed, firstly, in a violation of the transparency of its substance and, secondly, in a change in position.

Cataracts as a result of contusion can vary in intensity - from partial to complete.



Fig. 40. **Changes in the angle of the anterior chamber in contusion:**
a — recession of the angle of the anterior chamber; b — hemorrhage of the identification zones; c — rupture of the trabeculae and recession of the angle

There is also a variety of opacities in localization: most often, anterior and posterior subcapsular and cortical cataracts are observed; there can be nuclear and perinuclear. Opacities in the form of a rosette, sector-shaped, point-shaped are possible. Contusion cataracts are often subject to reverse development, but among them, stationary or progressive ones occur in a significant percentage.

In severe contusions, ruptures of the lens capsule with swelling of its substance and the release of lens masses into the anterior chamber have been described.

The change in the position of the lens can be twofold: subluxation, or subluxation, and complete dislocation, or luxation. A similar situation occurs due to a rupture of the ligament of Zinn. Subluxation is clinically manifested by the following symptoms: phacodonesis, and then iridodonesis, often visible only biomicroscopically; then, in the light of a slit lamp, a change in the position of the biomicroscopic section of the lens can be determined; sometimes the equator of the lens is visible, the depth of the anterior chamber becomes uneven. Typically, with significant subluxation, a vitreous hernia is observed, which can progress as the lens is further displaced; this situation is some-

times accompanied by an increase in intraocular pressure.

As clinical experience shows, signs of initial lens subluxation are often not diagnosed. Examination of this category of patients requires persistence and special care during biomicroscopy since only with a certain movement of the eyeball can a slight phacodonesis be noticed.

Subluxation of the lens can cause monocular diplopia, as well as other visual disturbances, since the eye becomes nearsighted and astigmatism appears. Since subluxation of the lens can eventually cause complete dislocation, as well as lead to an increase in intraocular pressure, the use of mydriatics should be excluded and strict control over the state of ophthalmotonus should be ensured.

Dislocation of the lens with a complete rupture of the zinc ligament is possible in three directions: into the anterior chamber, the vitreous body (which is most often observed) and under the conjunctiva.

Displacement of the lens into the anterior chamber is easily diagnosed: the lens in the chamber has the classic appearance of an oil drop; however, often the lens only partially enters the anterior chamber. An obligatory symptom of such a clinical situation is an acute increase in intraocular pressure, which requires immediate surgical intervention - removal of the displaced lens.

The fate of the lens and the eye as a whole may vary. Usually, over time, the lens becomes somewhat cloudy, wrinkled, and sometimes swollen or calcified. It may float freely in the vitreous body or become fixed somewhere in the lower part of the eyeball. There are known cases when a luxated lens does not cause any complications for many years. However, some patients develop phacogenic iridocyclitis due to the toxic effect of the lens protein on the uveal tissue during the lysis of the capsule and, in connection with this, hypertension. Increased intraocular pressure is also possible due to mechanical irritation of the ciliary body processes by the mobile lens. Attacks of increased pressure in the latter case are sometimes stopped by changing the position of the head. In addition, a lens luxated into the vitreous body is very dangerous: retinal detachment may occur. Since the question of removing the lens from the vitreous body is debatable and in each specific case should be decided individually, which will be discussed further, patients with such a clinical situa-

tion should be referred to the dispensary service group.

The last variant of lens dislocation is its displacement under the conjunctiva, which usually occurs with severe contusion accompanied by a rupture of the sclera. The lens is easily identified under the conjunctiva as a rounded formation. The diagnosis is undoubted and the tactics are clear - there is a violation of the integrity of the sclera, requiring revision and treatment of the wound with removal of the lens. In addition to the serious lens changes described above, contusion may also cause transient pigment deposits on the lens capsule that do not affect visual function. These appear in the form of the well-known Fossius ring – an imprint of the pigment border of the pupil on the anterior lens capsule – and the more rarely observed posterior ring, which consists of pigment deposits on the posterior capsule of the lens when it comes into contact with the ciliary body processes. (Fig. 41).

Contusion injury of the vitreous body is characterized by hemorrhage from the vessels of the ciliary body, retina, or choroid itself. In cases where blood saturates the entire volume of the vitreous body, this condition should be called hemophthalmos.



Fig. 41. **Pigment deposits on the posterior capsule of the lens**

With partial hemorrhage into the vitreous body, the pink reflex from the fundus and some object vision are preserved to a certain extent. The reverse development of hemophthalmos and partial hemorrhage into the vitreous body occurs slowly, often leaving significant opacity, leading to the formation of adhesions with subsequent tractional detachment of the retina. Hemorrhages in the posterior parts of the vitreous body, parietal and in the retrolental space are especially unfavorable in terms of prognosis.

The retina is very vulnerable to blunt trauma to the eyeball. The most typical symptom of contusion is Berlin's retinal opacification, localized in the center, along the periphery of the fundus, or along the course of large retinal vessels.

Depending on its intensity, it leads to varying degrees of vision loss. Traceless reverse development of retinal opacity occurs after 4-6 days. However, in elderly individuals, areas of retinal dystrophy in the form of pigment accumulation or depigmentation zones are found in the central parts of the fundus at the site of Berlin's opacity.

Retinal hemorrhages, which are also characteristic of contusion, like Berlin's opacity, are the result of significant disturbances in microcirculation in the posterior part of the eyeball. Histological and electrophysiological studies indicate pronounced hemodynamic shifts in the vascular pool, as well as an increase in the permeability of the vascular wall during contusion in the entire vascular system of the eyeball.

One of the most severe damages to the retina is its rupture. Usually, it is a hole-like defect in the area of the macula lutea, but there are variants when the rupture has the form of an oval and is located eccentrically. As a rule, the latter is observed when the blow is at an angle relative to the plane of the retina. Ruptures are dangerous in terms of the occurrence of retinal detachment, but sometimes they are blocked due to the gradual formation of a chorioretinal scar against the background of hemorrhages in this area.

Contusion of the eyeball may also be complicated by detachment of the retina from the ora serrata. The most vulnerable are the upper section, the upper-inner and the lower-outer squares. In everyday practice, one should remember the possibility of retinal dialysis, since they lead to retinal detachment. If the upper detachment manifests itself as retinal detachment with subjective symptoms quite early, then the lower detachments are "silent" for a long time. For their diagnosis, careful ophthalmoscopy with maximum mydriasis or, even better, biomicrocycloscopy is needed. In our clinical practice, there is a rule that all patients with contusion of the eyeball, upon discharge from the hospital, in addition to gonioscopy, undergo an examination of the periphery of the fundus using a three-mirror lens—this ensures early diagnosis, as well as prevention of contusion retinal detachment.

In the choroid, ruptures also form as a result of blunt trauma. They have the appearance of a crescent, a yellowish tint, and are located on the temporal side of the disc, in the area of the macula lutea, or along the periphery. Sometimes the rupture is closed by hemor-

rhage (usually retinal, not choroidal), which may subsequently lead to pigmentation of the rupture zone. Choroidal ruptures in the macular area with extensive hemorrhage into the retina ultimately result in a sharp decrease in vision due to gross cicatricial and dystrophic changes, which should be taken into account when determining the prognosis.

It is known that the classic version of contusion, unlike penetrating injury, occurs without disruption of the integrity of the fibrous capsule of the eye. Nevertheless, in approximately 6% of cases of severe blunt trauma, rupture of the sclera occurs. The most vulnerable in terms of rupture is the area of Schlemm's canal (in the upper and inner segment), as well as the area under the rectus muscles, where the sclera is thinned.

In classical cases, diagnosis is straightforward: the scleral rupture reveals fallen membranes and the contents of the eyeball. However, sometimes the scleral rupture is covered by intact conjunctiva, making diagnosis more difficult. In these cases, the following clinical signs should be taken into account: local conjunctival edema and subconjunctival hemorrhage, deep hypotension, shallow anterior chamber in the case of a scleral rupture in the Schlemm's canal, and deep chamber in the case of a scleral rupture in the posterior region. However, diagnosis of scleral rupture can sometimes be difficult, and this should always be kept in mind by the ophthalmologist providing assistance to the victim. When a scleral rupture is detected, one cannot be sure that this rupture is the only one; double and multiple scleral injuries are possible. An absolute sign of a ruptured sclera is the lens falling out under the conjunctiva.

The prognosis for contusion with rupture of the sclera is not very favorable. Our study of eyes enucleated due to contusion shows that in the overwhelming majority of cases, the eyes were removed where the contusion was complicated by rupture of the fibrous capsule of the eye.

Contusion injuries of the optic nerve are very multi-profile both in the level of damage and in the nature of clinical manifestations and outcomes. Changes in the optic nerve head associated with vasomotor disorders should be considered reversible; clinically this is manifested by hyperemia of the disk, mild peripapillary edema of the retina. In addition, the vascular reaction to blunt trauma can manifest itself in the form of a clinical picture of obstruction of the vessels feeding

the optic nerve, with a decrease in central vision and visual field impairment. In prognostic terms, as our clinical observations show, these cases can be quite favorable, partial or even complete restoration of visual functions is possible.

Contusion damage to the optic nerve also manifests itself in the form of compression of the trunk by hemorrhage into the intermembranous space and orbit or damage by a bone fragment in the optic nerve canal. In severe contusions, partial ruptures of the optic nerve or its detachment from the scleral ring are described. As a result of such damage (depending on the degree), partial or complete loss of visual functions occurs with the clinical picture of optic nerve atrophy.

In practical work, determining the level and nature of damage to the optic nerve causes great difficulties. X-ray examination of the optic nerve canal according to Reze does not always resolve the issue. Sometimes only dynamic observation allows for a more precise diagnosis.

A distinctive feature of blunt trauma to the eyeball is the diversity of ophthalmotonic reactions and long-term instability of ophthalmotonus. Moreover, as shown by clinical and experimental studies presented in the literature, such fluctuations in intraocular pressure are possible not only in the injured eye but also in the healthy eye due to the presence of the oculo-ocular reflex. It is also necessary to note the fact that ophthalmotonus fluctuations are possible during the period of apparent clinical recovery. Therefore, during dispensary observation of individuals with contusion of the eyeball, the possibility of such manifestations should be taken into account. This is a feature of blunt trauma, which distinguishes it from penetrating injury, in which, however, a violation of the regulation of intraocular pressure is also possible.

Most researchers distinguish several (2-3) periods of ophthalmotonus changes in contusion. The first phase of reactive hypertension is characterized by an increase in intraocular pressure (Po~29 mm Hg), which persists for 1-2 days. Then comes a period of relative hypotension (Po~9-10 mm Hg), lasting 1-2 months. However, against the background of hypotension, moments of increased intraocular pressure are possible, especially in cases where there is subluxation or complete dislocation of the lens.

The increase in pressure during contusive dislocation of the lens sometimes occurs very quickly and

requires surgical intervention. We have repeatedly seen this in the clinic. Therefore, special monitoring of the state of the ophthalmotonus and the position of the lens is necessary in people where the contusion is accompanied by its displacement.

We believe that during the first one or two months after contusion, the diagnosis of post-contusion glaucoma should probably not be made, since this period is one of the phases of unstable ophthalmotonus. After two months, three different variants of the state of intraocular pressure are possible: its normalization, in isolated cases the development of persistent deep hypotension, and, in approximately 11-12%, secondary post-contusion glaucoma.

In conclusion of the description of the clinical picture of blunt trauma to the eyeball, we consider it necessary to reflect some of the most typical manifestations of indirect contusion of the eye, which occurs with facial trauma, body concussion. In general, severe contusions, when serious damage to the skull, skeletal system or vital organs comes to the fore, eye symptoms remain unnoticed. At the same time, the consulting ophthalmologist should keep in mind the possibility of subluxation or dislocation of the lens into the vitreous body (often in both eyes), retinal hemorrhages, and retinal detachment in such patients. In the absence of a visible clinical picture, changes in the angle of the anterior chamber cannot be excluded.

Morphological studies by I.I.Cherkasova (1978) confirmed traumatic deformation of the anterior chamber angle in indirect contusion of the eye. Therefore, in addition to traditional ophthalmological examination methods, gonioscopy is necessary for all patients with indirect contusion of the eye. In this case, as in cases of direct contusion, anatomical abnormalities in various zones of the angle and its recession can be detected. These changes serve as a prerequisite for the development of secondary post-contusion glaucoma, which can be prevented and interpreted only on the basis of timely and thorough gonioscopy.

Chapter 3

COMPLICATIONS OF THE WOUND PROCESS AND CONTUSION OF THE EYEBALL

Complications of penetrating wounds and contusions of the eyeball are described in one chapter

since, despite the difference in the origin and pathogenesis of these two types of mechanical trauma, they have a number of common features. Firstly, penetrating wounds of the eyeball are often accompanied by an element of contusion, complicating the course of the process both in the early post-traumatic period and in the long term. Secondly, contusion of the eyeball with rupture of the sclera actually acquires the features of a penetrating wound.

There are still some points that allow us to combine the complications of mechanical trauma in the eyeball. In particular, clinicians know that post-traumatic glaucoma after both penetrating wounds and contusions has much in common in its clinical course.

This also applies to retinal detachment, cataracts, and hemophthalmos. Although they cannot be considered absolutely identical in any case (this would be incorrect from the point of view of the nature of the complications indicated), nevertheless, there are common, analogous guidelines in treatment tactics, and in the literature glaucoma, retinal detachment, and cataract in these two types of trauma are often designated the same way, as secondary post-traumatic glaucoma, traumatic retinal detachment, etc.

Traumatic iridocyclitis, according to literature, complicates the course of penetrating wounds of the eyeball in 60% of cases. Clinically, iridocyclitis can proceed easily and completely resolve two weeks after the injury. In severe forms, it can drag on for 1-2 months, periodically recur, gradually leading to deterioration of visual functions. Sometimes this process becomes protracted (over several years), which causes the death of the damaged eye or the development of sympathetic ophthalmia.

Iridocyclitis after penetrating wounds can proceed in several variants. The first is to be truly infectious, which is the result of the introduction of infection into the eye cavity. Due to the active use of modern broad-spectrum antibiotics for the prevention of intraocular infection, as well as the entire range of organizational and therapeutic measures, the percentage of infectious purulent iridocyclitis has now decreased more than twofold, and according to our pathohistological studies, a true infectious process occurs in 5% of cases.

The clinical picture of traumatic iridocyclitis does not present any particular features in comparison with iridocyclitis of another origin. In the serous-fibrinous nature of the process, which is observed

most often, the typical symptoms are pain syndrome (pain in the eye, corresponding to the half of the head, during palpation of the eyeball), precipitates on the posterior surface of the cornea, posterior synechiae, exudate and fibrin threads in the anterior chamber, hypotension; exudate effusion into the vitreous body is possible. In the case of a purulent process in the anterior chamber - hypopyon. Intraocular pressure may tend to increase due to posterior synechiae, swelling of the lens, retention in the filtration apparatus of the angle of the anterior chamber.

A severe complication of penetrating wounds of the eyeball is endophthalmitis. It is characterized by purulent inflammation of the retina with the release of exudate into the vitreous body.

There are assumptions based on morphological studies that not only iridocyclitis but also clinically diagnosed endophthalmitis, is associated with reactive-reparative processes due to the organization of crushed tissues of the uveal tract, lens and hemorrhages. Classic endophthalmitis is an irreversible process in which, due to the involvement of inflammation and purulent melting of the retina, visual acuity is zero or uncertain light perception. Let us recall that in traumatic iridocyclitis with effusion into the vitreous body, normal vision or light perception with a correct projection of light is preserved, and iridocyclitis, as a result of active therapy, can have a favorable outcome.

Clinically, endophthalmitis is characterized, in addition to the complete loss of vision, which has already been mentioned, by increased pain in the eye, swelling of the eyelids and chemosis of the conjunctiva, absence of a reflex from the fundus; otherwise, the symptoms of iridocyclitis or purulent keratitis and scleritis are aggravated, which are the trigger for the progression of the process and its transition to endophthalmitis.

The most serious purulent complication of penetrating injury of the eyeball is considered to be panophthalmitis. In this case, all membranes of the eyeball are involved in the purulent inflammation; edema and infiltration of the eyelids covering the eye slit rapidly increase; exophthalmos appears. Along with a severe local process, phenomena of general intoxication are observed, body temperature rises. In the case of panophthalmitis, as a rule, it is not possible to save the eye. All therapeutic measures should be aimed at pre-

venting the generalization of infection and prophylaxis of meningitis.

The most common (30%) causative agent of intraocular infection is staphylococcus, which is resistant to penicillin in almost 70% of cases and to streptomycin in 50%. Laboratories of many clinics indicate the high activity of monomycin (up to 90%) and semisynthetic penicillins (75%) - ampicillin, methicillin and oxacillin against the causative agent of purulent endophthalmitis - staphylococcus. However, it is often impossible to detect the causative agent in an obviously purulent process (up to 50% of cases).

Treatment of purulent inflammations of penetrating wounds of the eyeball should be comprehensive. First of all, active use of antibiotics is necessary. The choice of drug depends on the sensitivity of the isolated microbial flora to it. In its absence, it is advisable to use broad-spectrum antibiotics, the most active in relation to modern flora. The doses of antibiotics are largely determined by the route of administration, which in turn is dictated by the clinical manifestations of the process (iridocyclitis, endophthalmitis, or panophthalmitis). It is known that intramuscular and even intravenous administration of antibiotics does not provide the necessary concentration of the drug in the tissues of the eye. Therefore, in recent years, antibiotics have been administered under the conjunctiva for iridocyclitis, and the anterior chamber is washed with their solutions. In cases where the process does not have positive dynamics, i.e. endophthalmitis is possible, it is advisable to begin retro, parabulbar, or even intravitreal administration of antibiotics early.

In endophthalmitis, it is necessary to administer antibiotics directly into the vitreous body, while maintaining subconjunctival injections.

'There is a method of prolonged washing of the vitreous body using a cannula with the simultaneous administration of antibacterial agents. Panophthalmitis requires more active general antibiotic therapy.

At present, in cases of severe purulent processes in the eye, it is proposed to use intra-arterial administration of antibiotics by prolonged perfusion, which allows creating a concentration of the drug approximately 100 times greater than with the intravenous method of administration.

The doses of the most commonly used antibiotics in the clinic for various methods of local admin-

istration are indicated in the chapter on organizing emergency care and treatment measures for mechanical injuries to the eyeball.

While generally adhering to the above-mentioned methods of antibiotic administration, we prefer to retain traditional methods in the case of purulent infection - intramuscular and intravenous. In doing so, we take into account the possibility of mutual enhancement of the action of the drugs.

The following antibiotics are used for intramuscular and intravenous administration: Tetraolean – 100 mg or 250 mg, 2-3 times daily; Gentamicin – 40-80 mg intramuscularly, 3 times daily for 7-10 days; and Ceporin – 0.5-1.0 g intramuscularly, 2-3 times daily. There are recommendations to combine local treatment of purulent complications with intravenous drip administration of cocktails containing, in addition to broad-spectrum antibiotics, cocarboxylase and vitamins.

In addition to antibiotic therapy, most clinicians use sulfanilamide drugs, which not only have an antibacterial effect, but also enhance the effect of antibiotics. These primarily include the widely used sulfadimethoxine (therapeutic dose 0.5 g twice a day for a week; 1st dose - 1.0 g).

Traditional and justified for intraocular infection is the intravenous administration of urotropin; it increases the permeability of the hemato-ocular barrier for sulfonamides and antibiotics, thus ensuring their sufficient concentration in the tissues of the eye.

Taking into account the fact that penetrating injury of the eyeball changes the immunological reactivity of the organism, in case of purulent infection it should be considered appropriate to prescribe active desensitizing therapy, especially since there is data on the role of sensitization to staphylococcus in the pathogenesis of posttraumatic uveitis. Calcium preparations, diphenhydramine, and suprastin are usually used as desensitizing agents. No one currently doubts the need to use corticosteroids (in combination with antibiotics) that have an immunosuppressive effect. Cortisone is prescribed locally in the form of a 1% or 0.5% suspension, dexazone or dexamethasone solution. These drugs in a dose of 0.3-0.5 ml are used for subconjunctival injections, steam and retrobulbar administration. Very small amounts of corticosteroids are administered intravitreally, and there are recommendations to limit them to one drop.

Special attention should be paid to the treatment of traumatic, aseptic and phacogenic iridocyclitis, which lasts for a long time, gives relapses and ends in practical blindness, subatrophy of the eyeball, and in rare cases, sympathetic ophthalmia.

Taking into account the pathogenetic mechanism of these forms of iridocyclitis, where autoimmune reactions have a predominant influence on the course of the process, a system of combined therapy based on local and general administration of immunosuppressive agents has been developed in modern ophthalmotraumatology. It is carried out taking into account the clinical picture of the disease and is aimed at reducing the permeability of the uveal tract vessels, exudation, lymphocytic infiltration and proliferation, as well as hyperreactivity of the body (L.T.Arkhipova, N.S.Zaitseva, R.A.Gundorova, 1979).

The guidelines of the aforementioned authors provide detailed dosages and regimens for the administration of corticosteroids and other agents, in particular desensitizing agents (butadiene, diphenhydramine, suprastin, calcium preparations, ascorbic acid, etc.). In cases where traumatic iridocyclitis is supported by the presence of remnants of lens masses, poorly absorbed blood elements, and adhesions, the question of surgical treatment should be raised. In the absence of an effect from complex therapy, including the use of corticosteroids not only locally but also orally, in the case of practical blindness and progression of subatrophy of the eyeball, the question of enucleation of the damaged eye is decided.

Pathogenetically, the most formidable complication of penetrating injury to the eyeball, sympathetic inflammation, is closely associated with traumatic iridocyclitis. It is known that this term refers to an intact eye that becomes ill in response to traumatic iridocyclitis that has arisen as a complication of the wound process of the damaged eye. Sympathetic inflammation in the injured eye is morphologically characterized by cellular infiltration of the entire vascular tract with the presence of giant and epithelioid cells. Although it is possible to distinguish sympathetic iridocyclitis from traumatic non-sympathetic iridocyclitis histologically, it is almost impossible to do so clinically; this is the complexity of the problem.

The second unresolved issue is the pathogenesis of sympathetic inflammation. Previously existing theories, such as bacterial, viral, etc., cannot be considered valid at present. There are now more and

more supporters of the autoimmune nature of sympathetic ophthalmia, based on modern clinical, morphological and immunological studies, as well as the observed therapeutic effect of treatment with corticosteroids.

Fortunately, this disease is rare - 0.4-1.8% of all penetrating wounds of the eyeball. According to the data of the pathohistological department of the Moscow Ophthalmological Clinical Hospital, for the period from 1968 to the present, only isolated cases of sympathetic inflammation have been observed, which amounted to about 0.5% of the total number of enucleations after penetrating wounds of the eyeball. It is known that sympathetic inflammation does not develop earlier than two weeks after the injury. However, late periods of its occurrence are indicated up to 50 years.

Although it has not yet been possible to determine the reliable clinical signs of sympathetic inflammation, it should be borne in mind that sympathization most often develops with wounds that damage the iris, ciliary body, and lens. Traumatic sympathetic iridocyclitis is usually sluggish in nature and is accompanied by hypotension. In cases where the wound is limited to the cornea and occurs without signs of inflammation, the danger of sympathization is practically reduced to zero.

Clinically, several forms of sympathetic inflammation are distinguished. The most favorable in terms of course and prognosis is serous or sero-fibrinous iridocyclitis; its symptoms are clear from the name and have practically no differences from similar iridocyclitis of other etiologies.

Plastic iridocyclitis is more severe. Now, due to the active use of corticosteroids, this form is less common than sero-fibrinous. It is plastic iridocyclitis that causes secondary glaucoma due to possible adhesion and overgrowth of the pupil.

There are also mixed forms, in which neuroretinitis is observed. It has no specific clinical features but is distinguished by the fact that it undergoes rapid regression after enucleation of the injured eye. Literary data from recent years indicate frequent involvement of the optic nerve disc.

As the process progresses, neuroretinitis may develop with a clinical picture of focal choroiditis against the background of iridocyclitis and neuroretinitis.

Complications of severe forms of sympathetic inflammation, especially those incorrectly treated with corticosteroids, include exudative retinal detachment, cataracts, and secondary glaucoma leading to atrophy of the eyeball.

Treatment of sympathetic ophthalmia is a complex but not hopeless task. The effectiveness of treatment measures increased significantly when the choice of therapy began to be approached from the point of view of the modern theory of the origin of sympathetic inflammation as an autoimmune disease.

As the process progresses, panuveoneuroretinitis may develop with a clinical picture of focal choroiditis against the background of iridocyclitis and neuroretinitis.

When starting treatment for sympathetic ophthalmia, it is necessary to decide whether enucleation of the damaged eye is necessary. A blind or unpromising eye in terms of vision must be removed.

Moreover, early enucleation, as a rule, provides better results in the treatment of sympathetic ophthalmia. In cases where residual vision is preserved in the injured eye, the issue is decided individually, taking into account the immunological background of the body.

Prevention of sympathetic ophthalmia is ensured by timely, no later than two weeks from the moment of injury, enucleation of the damaged eye. One of the frequent complications of penetrating wounds and contusions of the eye is clouding of the lens.

Complications of severe forms of sympathetic inflammation, especially those improperly treated with corticosteroids, include exudative retinal detachment, cataracts, and secondary glaucoma leading to atrophy of the eyeball.

Along with prednisolone, potassium, calcium, and ascorbic acid preparations are prescribed in average therapeutic doses. In severe forms of sympathetic ophthalmia, cytostatics are recommended, in particular cyclophosphamide. Antibiotics are prescribed as indicated, local therapy with mydriatics, cortisone, and active desensitizing therapy are performed.

According to the literature, traumatic cataract occurs in almost 50% of all mechanical injuries to the eyeball.

Depending on the type of injury, the nature of the object caused damage and many other completely understandable reasons; damage to the lens has many clinical variants.

According to localization, local and diffuse traumatic cataracts are distinguished. They can be stationary and progressive. There are traumatic cataracts with damage to the lens bag and prolapse of the lens masses into the anterior chamber, as well as without disruption of the capsule. A number of cataracts are characterized by an increase in intraocular pressure, alt-

hough this is not an obligatory sign. A semi-resorbed lens gives a picture of a membranous cataract. Cataracts with metallosis of the eye are unique. Sometimes traumatic cataracts are combined with subluxation of the lens.

Such a variety of forms of traumatic cataracts creates some difficulties in the ophthalmologist's tactics, choice of treatment method and determination of the timing of surgical intervention. There are no uniform guidelines, and theoretically, this is hardly possible. The issue is largely resolved individually, including taking into account the patient's age, his profession, and the vision of the other eye.

In cases where trauma causes extensive rupture of the lens capsule and lens masses fall into the anterior chamber and tend to swell, phacogenic iridocyclitis develops as a response to the toxic and antigenic action of the lens protein. It is usually complicated by the symptoms of hypertension. Sometimes the process is not limited to the anterior part of the uveal tract and, along with phacogenic iridocyclitis, phacogenic endophthalmitis may occur.

Based on literature data (R.A.Gundorova, 1975) and our own clinical experience, we believe that the most optimal time for paracentesis is two weeks after the injury, when the traumatic corneal scar has been formed to a certain extent, and all the masses of the lens are in a state of swelling and, as a result, are easily removed. FOR paracentesis, it is better to use the limbal approach with cutting out a conjunctival flap. The masses are removed by washing them out or by aspiration. In cataracts that are local and stationary in dynamics, such as in the situation of microperforation of the lens capsule and tamponade of the hole with a pigment sheet of the iris, high visual functions are often preserved. These cataracts do not require active actions of the surgeon, and here dispensary observation of the patient is necessary.

Certain difficulties are caused by the removal of complete semiresorbed and membranous cataracts. These cataracts are usually operated on after a long time has passed since the injury. Therefore, before starting surgery, it is necessary to evaluate the functional capabilities of the damaged eye, the condition of the fundus (conduct electroretinography, ultrasound echography; determine the critical flicker fusion frequency).

To remove stationary traumatic cataracts, cryoextraction is used, which has become traditional, i.e.,

intracapsular extraction is performed. In complicated situations, the lens can be removed with a loop or tweezers. Phacoemulsification has proven itself in the clinic, especially in young people. In case of membranous cataracts, capsulotomy, capsulectomy, transciliary extraction with a vitreous stripper (V.V.Arkhangelsky, 1979), or a laser is used for these purposes. To avoid pupil displacement in the postoperative period as a result of vitreous prolapse, an extrapupillary approach can be used to remove traumatic cataracts. For this purpose, an iridotomy is performed concentrically to the limbus, followed by fixation of the iris incision with 2-3 microsutures.

If, however, during the removal of the lens through the pupil, the vitreous falls out into the anterior chamber, it is advisable to perform maximum excision of the vitreous substance and reposition the pupil. The fall out of the liquefied vitreous is especially typical during the extraction of complicated cataracts associated with metallosis of the eye. In case of cataracts against the background of chalcosis or siderosis, unithiol, vitamins, and stimulants (see below) are recommended in the complex treatment of the process along with surgery.

During the operation for traumatic cataracts, it is necessary to dissect the anterior and posterior synechiae, adhesions, perform partial vitrectomy, and perform iridoplasty, i.e., in fact, perform complex reconstructive surgery. Recently, for medical and professional reasons, implantation of an intraocular lens has been recommended.

To restore the required shape and position of the pupil, an argon laser is used (corepraxia).

A complication of penetrating injuries is metallosing of the eye. It occurs when a metal foreign body remains in the eye cavity for a long time. An iron-containing foreign body leads to the development of siderosis, a copper-containing one - chalcosis.

This complication is not common, but given the high percentage of intraocular foreign bodies in general (according to literature, they are found in industrial injuries in 50% of all penetrating injuries and in 17% of household injuries), metallosing cannot be considered a very rare situation.

Practical ophthalmologists should be familiar with metallosis of the eye for two reasons. First, metallosis may be an accidental finding indicating the presence of an intraocular foreign body. "There are cases in the clinic when patients

seek help for cataracts typical of siderosis, not knowing that they had a penetrating injury to the eyeball. In such a situation, the question of removing the lens and conservative treatment should be decided taking into account the stage of siderosis. Secondly, in modern ophthalmic traumatology, there is a rule according to which intraocular foreign bodies of difficult-to-reach localization should be left in the eye if the degree of risk during their removal is high, and the foreign body is removed at the cost of loss of vision and even the eye. A metallic foreign body left inside the eye can be the cause of metallosis. At a certain stage of its development, there are absolute indications for the removal of the foreign body, despite all the complexity and danger of the operation; nevertheless, this is necessary, since the further presence of the foreign body in the eye will undoubtedly lead to its death.

The clinical picture of siderosis is characterized by yellowish-brown coloration of the cornea, iris, and increased exogenous pigmentation in the angle of the anterior chamber. The siderotic cataract is absolutely typical. Biomicroscopically, its initial signs are yellowish-brown inclusions under the anterior capsule of the lens, which are histologically assessed as capsular epithelium cells imbibed with iron salts.

Then the inclusions increase in size, creating a plaque-like appearance under the anterior capsule at the level of the pupillary margin. The center and posterior sections of the lens are intact. Destruction is observed in the vitreous body, and a dystrophic process is observed in the fundus, resembling the ophthalmoscopic picture of tapetoretinal abiotrophy.

However, the earliest manifestations of siderosis, namely, damage to the retina, can only be confirmed by electrophysiological studies. This information becomes especially valuable in the process of dynamic observation of patients with an opaque lens. Histochemical studies have also made it possible to detect iron ions in the membranes of the eyeball during the long-term presence of a foreign body in the orbit, near the posterior pole of the eye (V.A.Butyukova, 1977).

There is no specific pattern between the time of siderosis manifestation and the time of foreign body presence in the eye. However, almost half of patients develop siderosis 1-2 years after the injury. An iron-containing foreign body localized in the anterior chamber

more often gives the clinical picture of sclerotic damage to the lens, iris, and angle of the anterior chamber. A foreign body at the posterior pole of the eye causes changes in the retina earlier.

Chalcosis of the eye is characterized by damage by copper salts to the same parts of the main apple as in siderosis. Along with greenish-bluish uneven coloring of the cornea, iris, hyperpigmentation of the angle of the anterior chamber and coarse floating opacities of the liquefied vitreous body, a very peculiar clouding of the lens is observed. The cataract has the appearance of a sunflower. This is a clouding in the form of a ring with radial stripes. When examined with a slit lamp, it is determined under the anterior capsule of the lens and has a gray-blue and yellowish color. In the retina in the central parts of the fundus, foci with a metallic sheen are occasionally ophthalmoscoped.

Based on clinical manifestations and electroretinographic data, R.A.Gundorova proposed a clinical classification of eye metallosis, which can serve as a guide when choosing indications for surgical intervention on the eyeball with an intraocular chemically active foreign body. Four stages are distinguished: latent, initial, developed and advanced metallosis. Having extensive experience in treating patients with metallosis, the author believes that it is always necessary to strive to remove the intraocular metallic foreign body. In exceptional cases, when the risk of eye death is extremely high when removing the foreign body, surgery can be avoided in the first stage of metallosis, while in the second stage, when changes appear on the electroretinogram, removal of the foreign body is necessary despite the existing danger.

Surgery is indicated for all patients with stage III metallosis; surgical treatment is ineffective at stage IV.

In inoperable cases, the issue of conservative treatment is acute. Of the many drugs, mainly related to heavy metal antidotes, Unitnol deserves attention. The course of treatment combines intramuscular administration of a 5% solution of Unitnol with subconjunctival injections. Its positive detoxifying effect is noted not only clinically, but also electrophysiologically. Unitnol is used for both siderosis and chalcosis. In addition, in chalcosis, ionization with the opposite sign is carried out to remove and dissolve copper salts.

Prevention of metallosis is the timely removal of metallic intra-

ocular foreign bodies. Recently, a method has been developed for neutralizing the chemical activity of unremoved metallic fragments located in the membranes at the posterior pole of the eye. It is based on the formation of a cicatricial barrier around foreign bodies using photocoagulation of the inner membranes and diathermocoagulation of the sclera (A.A.Malayev, 1979), which isolates them from the surrounding structures. A serious complication of mechanical trauma to the eyeball is an increase in intraocular pressure. Posttraumatic glaucoma occurs on average with a frequency of 6% of the total number of eye injuries and makes up 30-50% in relation to the group of secondary glaucomas.

The cause may be either a penetrating injury or a contusion of the eyeball, and most researchers find that penetrating injury more often causes a persistent increase in pressure (25%) than a contusion of the eyeball (12-17%).

The diversity of anatomical and physiological changes that result from mechanical trauma to the eye causes certain difficulties in creating a unified classification, elucidating pathogenetic mechanisms, and in treatment tactics for post-traumatic glaucoma. In the situation of post-traumatic increase in intraocular pressure, it is probably necessary to keep in mind not glaucoma, but glaucoma, thus ensuring a differentiated approach to each of the forms.

It is known that eye damage causes certain hydrodynamic shifts and changes in ophthalmotonus. In penetrating wounds, hypotension, which usually occurs after the injury, persists for one month in the case of corneal and scleral wounds and one and a half months in the case of limbal wounds. Hypotension is the result of hemodynamic disorders in the ciliary body, leading to a decrease in the production of intraocular fluid. In a certain percentage of cases, an increase in intraocular pressure is possible in the early post-traumatic period.

Contusion of the eyeball is characterized by instability and diversity of ophthalmotonic reactions over a long period of time (this is discussed in detail in the corresponding section).

After approximately two months from the time of blunt trauma, intraocular pressure tends to stabilize.

In most cases, it normalizes, although hydrodynamic shifts are possible against the background of normotension. In isolated cases, persistent deep hypotension occurs as a complication (pressure with a

5.0 g weight is 8-9 mm Hg) with the appearance of myopia up to 3.0 D and edema of the optic nerve disc. This condition is unfavorable in terms of prognosis. Active therapy (stimulants, drugs that improve blood supply to the eyeball, physiotherapy procedures, and local atropine) does not give the desired effect. However, as already mentioned, post-contusion secondary glaucoma develops in 11-17% of patients.

The pathogenesis of increased intraocular pressure after mechanical trauma is varied. Glaucoma as a result of penetrating injury is most often associated with extensive cicatricial changes in the anterior part of the eyeball, disrupting the communication of the anterior and posterior chambers, as well as the outflow of intraocular fluid in the drainage zone of the angle.

In a small percentage of cases, increased pressure occurs with a long-term presence of a chemically active foreign body in the eye, entailing dystrophic changes in the angle of the anterior chamber.

In the case of contusion of the eyeball, secondary glaucoma often occurs against the background of anatomical changes in the chamber angle: rupture of trabeculae, hemorrhages, angle recession.

In both types of injury, i.e. both with the penetrating wound of the eyeball and with its contusion, the increase in intraocular pressure can be caused by pathology of the lens. Several variants of this pathology are observed in the clinic.

Firstly, there may be a dislocation of the lens, which leads to phacotopic glaucoma. When the lens is dislocated into the anterior chamber due to blunt trauma, glaucoma has a retention character. Hypersecretion and mixed forms of phacotopic glaucoma are usually observed with subluxation of the lens, which occurs both with a penetrating injury and with contusion (more often). Displacement of the lens into the vitreous body is complicated by an increase in intraocular pressure due to phacotoxic cyclitis or mechanical irritation of the ciliary body.

Secondly, posttraumatic glaucoma occurs when the lens masses swell and enter the anterior chamber. Here, there is a mixed nature of hypertension—mechanical closure of the angle and the toxic effect of the lens masses on the eye tissues, in particular on the ciliary body, which leads to hyperproduction of fluid; this glaucoma is called traumatic. Swelling of a traumatic cataract (without opening the cap-

sule) and the resulting closure of the anterior chamber angle causes the third variant of glaucoma associated with lens pathology. This is phacomorphic glaucoma. It occurs more often in contusion than in penetrating eye injury. The last variant—phacolytic glaucoma—is the result of the resorption of a traumatic cataract. The last two forms are discussed in detail in the section on biomicroscopy of the eye in relation to the senile cortical cataract.

It is necessary to remember one more factor that has a leading role in the development of secondary post-traumatic glaucoma. This is the neurovascular component of the pathogenetic link; it is believed that the cause of glaucoma also affects the neuroreceptor apparatus of the eye, which regulates the level of intraocular pressure.

Secondary posttraumatic glaucoma is characterized by a unique clinical course. In terms of age, the group of people with posttraumatic glaucoma is significantly younger than patients with primary glaucoma. This makes the problem more socially significant since it mainly affects the working contingent.

Secondary glaucoma after trauma often occurs against the background of cicatricial changes in the cornea, cataracts, retinal detachment. In this connection, low central vision is observed. The field of vision does not have the typical character for glaucoma; excavation of the optic nerve disc develops at an advanced stage of the process. All this complicates timely diagnosis.

Posttraumatic glaucoma occurs mostly according to the retention type. According to F.N.Nazirov (1972), retention occurs in 92.8% of patients, while the coefficient of ease of outflow is 3-4 times lower than normal. Hypersecretion of aqueous humor is observed much less frequently (7.2%). There is also a violation of the correlation between the level of inflow and outflow of fluid in the eye - the coefficient of ease of outflow remains constantly at a low level during the day, and the minute volume of chamber moisture increases sharply in the evening hours.

This creates a rise in intraocular pressure in the evening, and not in the morning, which usually occurs with primary glaucoma. The practitioner should remember the reverse type of daily curve in secondary glaucoma (71%) associated with trauma, and provide maximum hypotensive therapy in the evening hours. In this case, the combined nature of hypertension

and the large proportion of the hypersecretory factor should be taken into account. Drugs that suppress the secretion of intraocular fluid (adrenaline and its analogues) are recommended. The reverse type of daily curve should be kept in mind during dispensary observation of this group of people, monitoring intraocular pressure not only in the morning but also in the second half of the day.

Treatment of secondary posttraumatic glaucoma should be carried out taking into account possible pathogenetic links, the level of intraocular pressure, as well as the presence of concomitant changes in the eye caused by trauma and requiring correction.

Posttraumatic glaucoma occurs with uncompensated intraocular pressure in 50%. Most researchers believe that treatment should begin with a conservative approach, namely, with the use of a combination of miotics and mydriatics that prevent the formation of posterior synechiae. Adrenaline group drugs are indicated, as mentioned above, as well as dehydrating and diuretic agents (fonurit, diacarb). The hypotensive effect of drug therapy occurs in 15% of patients, the rest require surgical treatment.

Opinions on the timing and forms of surgical treatment of post-traumatic glaucoma are quite contradictory. In contusion glaucoma, most clinicians are inclined to believe that there is no need to rush with surgical treatment since surgical intervention can additionally cause hemo- and hydrodynamic disturbances, characteristic of contusion in general. Contusion "does not like" early surgery, it is necessary only in emergency situations: dislocation of the lens into the anterior chamber; revision of the sclera and treatment of the scleral wound; hyphema, which does not resolve for a long time and leads to imbibition of the cornea with blood and hypertension.

In glaucoma caused by a penetrating injury to the eyeball, in the conditions of modern microsurgery, it is justified to use early surgical intervention. It is not traumatic and at the same time, with compensation of intraocular pressure (up to 75%), it prevents the development of advanced forms of glaucoma, ensuring the preservation of visual function.

Given the pathogenesis of post-traumatic glaucomas, combined microsurgical operations that affect both the outflow of aqueous humor and its formation are advisable. At present, sinus trabeculectomy in various modifications, presclerectomy, cyclodialysis, sub-

scleral sclerencleisis, as well as cryoapplication of the ciliary body and traditional cyclodiathermy have proven themselves in the clinic.

The question of removing the lens, reconstruction of the anterior part of the eyeball in post-traumatic glaucoma is decided depending on the indications and, of course, in each specific case strictly individually, which generally characterizes ophthalmic surgery in case of eye trauma.

Traumatic retinal detachment occurs as a complication of mechanical eye injury, according to various authors, with a frequency of 0.9 to 39%, averaging 7-11%. Most often, it is caused by contusion of the eyeball (63.1%), followed by penetrating wounds (31.6%), with scleral wounds and wounds with an intraocular foreign body predominating as the primary cause. A certain percentage of retinal detachments is associated with indirect contusion during a head injury or fall (5.3%) (G.P.Smolyatnova, 1977). Most domestic and foreign authors give approximately the same percentage distribution of the frequency of etiologic factors.

The pathogenetic mechanism of retinal detachment development is largely determined by the nature of the injury. After penetrating wounds of the eyeball and contusions complicated by hemophthalmos, retinal detachment is of a traction nature. The entry of a foreign body into the eye cavity poses a risk for the formation of detachment both at the time of injury (retinal rupture) and when it is removed by diascleral means.

Metallosis is a factor predisposing to detachment due to necrotic defects in the retina around the foreign body when it is localized in the retina.

Mostly, retinal dialysis occurs in the upper section, upper-inner, or lower-outer segments; perforating retinal breaks are usually located in the area of the macula lutea - the counterattack zone. This localization should be taken into account when examining the fundus under conditions of maximum mydriasis, without which diagnostic errors are sometimes made.

The timing of the formation of traumatic retinal detachment is very variable and depends on many factors. It is detected in the period from several days after the injury to several years. But, in general, detachment forms earlier in case of contusion (after 4-6 months), and in case of penetrating injury of the eyeball, the most threatening period for its occurrence falls on the period from 6 months to a year.

The clinical picture of retinal detachment after eye trauma has no specific features that distinguish it from idiopathic detachment. In transparent optical media, diagnosis is not difficult. The presence of cataracts and vitreous opacity complicate the search for retinal detachment and especially its breaks. A sharp decrease in vision, loss of the visual field and hypotension indicate possible retinal detachment. However, it should be noted that according to E.O.Sakhonova (1977), hypertension is detected in 18% of patients with posttraumatic retinal detachment, usually occurring in the evening hours and changing to normal or hypotension in the morning. For comparison, we note that idiopathic retinal detachment is accompanied by hypertension in only 4% of cases. Currently, ultrasound examination has become of great help in diagnosing retinal detachments in opaque optical media.

However, in the presence of gross changes in the vitreous body, echography is not always consistent; it is difficult to differentiate preretinal adhesions and retinal detachment. A final judgment requires a comprehensive assessment of the electrophysiological study data, clinical picture, and sometimes used entoptic phenomena, such as mechanophosphene and autoophthalmoscopy.

In the treatment of posttraumatic retinal detachments, the guidelines currently developed for primary detachments are generally followed. To select a surgical intervention method, it is advisable to examine the fundus dynamically - before and after four to five days of bed rest with a binocular bandage. This allows one to determine the category of retinal detachment (M.M.Krasnov, 1966) and choose the optimal surgical treatment option.

Category I retinal detachments (mobile, with good adhesion in the rupture zone) are rare after trauma. In the presence of such a favorable option, laser, photocoagulation of the retina around the rupture, cryopexy and local scleral buckling are successfully used, as indicated by modern literature. Category II and III retinal detachments are more often observed in the clinic. In category II, the retina is only partially adjoined, in the rupture zone, after bed rest, there are tractions from the vitreous body.

The most acceptable surgical option at the present stage in such cases is scleroplastic operations (intra- and episcleral buckling, with the possible strengthening of the buckle with a circular suture ac-

cording to Arruga). Autologous cartilage, brefobone, but most often silicone rubber, which does not cause a reaction from the eye tissues and is easily modeled, are used as a buckle. Traditional diathermocoagulation of the sclera is used to form a chorioretinal adhesion, and cryopexy is used in case of repeated operations, thin sclera and large changes in the vitreous body; in addition, laser and photocoagulation are used according to indications. Puncture of the subretinal space should be done only when absolutely necessary while avoiding hypotension. Ophthalmoscopic control should be constantly carried out during the operation.

In category III retinal detachments, the most severe and prognostically unfavorable, the retina appears rigid, unable to straighten and adhere. In the vitreous body, gross destruction and adhesions with great traction force are determined. In addition to scleroplastic operations, creating adhesive inflammation between the membranes, and often scleral puncture, surgery necessarily involves dissection of adhesions, excision of the altered vitreous body and its replacement with analogues.

The method of introducing gases into the vitreous body is becoming increasingly widespread. In domestic practice, the inert gas sulfur hexafluoride has been proposed, tested and successfully used in the clinic (V.I.Kushnarev, 1979). Introduced into the vitreous body during surgery, it doubles its volume during the first day, creating internal compression necessary for straightening the rigid retina. Then, by the end of the week, the gas is completely absorbed, without having a toxic effect on the tissues of the eye.

Analysis of the outcomes of surgical treatment of traumatic retinal detachments using modern combined surgery, which is presented in the literature of recent years, allows us to make positive conclusions. In general, the anatomical outcomes are as follows: complete adhesion of the detached retina occurs in 50-80% of cases, 22% remain without effect. The functional outcomes of these operations are somewhat worse than the anatomical ones; only 50-75% of patients report an increase in visual acuity and an expansion of the visual field. At the same time, it should be noted that the course of retinal detachments after trauma is assessed as less severe compared to the course of idiopathic detachments. This is explained by the fact that the hemodynamics of the vascular tract in eyes with traumatic

detachment is not significantly reduced. Our own clinical experience allows us to agree with this assumption and recommend active surgical tactics in relation to patients with traumatic retinal detachment.

Chapter 4

EMERGENCY CARE AND TREATMENT FOR MECHANICAL INJURIES OF THE EYEBALL

Organization of emergency care, use of the most effective methods of diagnosis and treatment are important areas in the modern problem of eye trauma. First of all, this concerns penetrating wounds and contusions of the eyeball as the most common types of damage to the visual organ.

Their outcome largely depends on the timing of medical care and its quality. Organizational measures are important in providing timely and qualified care. They should ensure its required level at all stages - from the first pre-hospital to specialized inpatient care. Organizational measures should be built taking into account the conditions and characteristics of the region of the country, production, etc., but in any case, care must be highly qualified and carried out at the current level of development of medical science. Only such an approach will ensure a decrease in the percentage of post-trauma ethical complications, which is still quite high. According to E.N.Vilshapsky (1979), about 10% of patients are discharged from the hospital practically blind, and in 5.7% enucleation is performed due to eye trauma.

A new organizational form of emergency care for injuries to the visual organ in recent years has been the creation of trauma centers with a clear distinction between the tasks of each stage of care for the victim - at the pre-hospital, medical, ophthalmological (but without a surgical component) level, in the conditions of a district and city eye hospital, etc.

Trauma centers have been created on the basis of large eye research institutes (for example, the Ukrainian Republican Center - in the Odessa Research Institute of Eye Diseases, in the RSFSR the role of the center is assigned to the Helmholtz Moscow Research Institute of Eye Diseases), as well as eye departments of regional hospitals. One of the first (1973) to be created was the trauma center in the eye clinic of the Saratov Medical Insti-

tute, headed by Professor A.F.Kornilova. The experience of this center was widely reflected in the press (1977, 1979).

Traumatology centers have a specialized traumatology department of the hospital with an operating block, which is equipped with surgical microscopes (including some centers with television installations), a photo or laser coagulator, a diagnostic ultrasound device, an electromagnet and, of course, a set of microsurgical instruments, suture material, microneedles, as well as modern antibiotics necessary for the prevention of intraocular infection.

The tasks of traumatological centers are multidisciplinary. This is primarily the provision of emergency care, as well as the examination and treatment of patients with eye trauma.

Next comes the medical examination and rehabilitation of people who have suffered damage to the visual organ. The role of trauma centers in the training of ophthalmological personnel is important, as well as in carrying out large-scale organizational and methodological work, including preventive measures.

Traumatology centers have developed methodological recommendations for ophthalmologists, which provide for the volume and type of treatment measures at all stages of providing medical care to patients with penetrating wounds.

The methodological recommendations emphasize the prevention of purulent infection from the first minutes after injury, determine the type of transportation of patients with penetrating wounds to the trauma center (lying down with a binocular bandage, ambulance transport), and indicate the rules for preparing accompanying documentation (passport data, conditions of injury, treatment measures).

All patients with penetrating corneal wounds for surgical treatment, with scleral wounds complicated by membrane prolapse, patients with intraocular foreign bodies (magnetic and amagnetic of any localization) are referred to the trauma center.

In a large city with an extensive network of eye hospitals and ophthalmological care provided on a zoning basis, patients with penetrating wounds of the eyeball, as well as moderate and severe contusions, receive emergency care (and hospitalization), as a rule, at the place of initial treatment. In the evening and at night, ophthalmological institutions are allocated for these purposes, operating permanently or on a rotating schedule,

which have not only an ophthalmic surgeon on duty but also an extensive operating room and X-ray service.

Thus, at present, the opinion has developed in ophthalmology that patients with severe injuries should be sent to a trauma center, bypassing all possible stages of providing assistance, since only in the center highly qualified specialists, with sufficient equipment and facilities, will be able to provide assistance at the proper level.

Patients who require inpatient treatment but without active surgery can be treated in specialized eye hospitals such as regional and large city hospitals. Patients with mild injuries can be supervised at their place of residence. Thus, we are talking about a differentiated approach to determining the level of a medical institution depending on the severity of the injury, the qualifications of the staff, and the equipment of the department and operating room. In this case, the leading factor in providing care is the factor of its quality, and not the factor of time, which was previously assigned a leading role.

Penetrating wounds of the eyeball. As stated above, specialized emergency care for victims is provided in a hospital, so all patients with penetrating wounds of the eyeball are subject to mandatory hospitalization.

An essential point in the work of an ophthalmologist is the preparation of medical documentation. The outpatient card and medical history must reflect the conditions and time of injury, as well as the time of the patient's admission to the hospital. If there are signs of alcohol intoxication, they should be reflected in the medical history; this will subsequently serve as a reason for refusing to issue a sick leave certificate to the employee and issuing Form No. 54 instead. In the event of a late request for medical assistance, when there is no correspondence between the specified period of injury and the clinical characteristics of the wound, a note should be made in the sick leave certificate for the information of the administration of the enterprise paying for the sick leave certificate.

The treatment of penetrating wounds of the eyeball is complex and consists of both conservative and surgical components. Conservative treatment has the following objectives: infection prevention, activation of resorption processes, desensitization of the body, and stimulation of regeneration processes of damaged eye tissues. The prevention of purulent infection in penetrating wounds should

be carried out in all cases without exception, treating each wound as obviously infected.

It is advisable to begin by taking a culture to determine the nature of the microbial flora and its sensitivity to the most commonly used antibiotics. The culture is taken from the conjunctival cavity, from the wound area, in cases of surgical treatment, if possible, the fluid of the anterior chamber and the vitreous body are sent for culture; culture is made from the prolapsed membranes subject to excision, and from the foreign body. It is further advisable to use the express diagnostics method, used, in particular, in the Moscow Ophthalmological Clinical Hospital. This method allows determining the sensitivity of the microbial flora to antibiotics on the 2nd-3rd day, with the flora character being clarified after 5-7 days.

There is no absolute parallelism between the course of the posttraumatic period and the nature of the microflora. According to numerous studies published in the literature, in almost half of the patients (35-50%) with developed intraocular infection, the flora was not isolated at all.

Sometimes, heterogeneous flora is obtained from cultures from different parts of the eyeball. Unfortunately, prevention of viral infection, which should undoubtedly be included in the complex of so-called "reanimation" measures (in the figurative expression of R.A.Gundorova, 1977), carried out in case of penetrating wounds of the eyeball, has not yet been studied or established.

To prevent intraocular infection, broad-spectrum antibiotics are used, to which modern flora is sensitive (see the chapter "Complications of the wound process and contusions of the eyeball").

The most recognized method of administering antibiotics for prophylactic purposes, creating the necessary concentration in the tissues of the eye, is subconjunctival.

If surgical treatment is performed, irrigation of the wound, prolapsed membranes, and also washing of the anterior chamber with antibiotic solutions in appropriate concentrations, sometimes their introduction into the vitreous body, are indicated. Currently, monomycin, semi-synthetic penicillins - oxacillin, methicillin, as well as gentamicin, produced by the domestic industry, are widely used.

In addition to the named antibiotics, penicillin, streptomycin, as well as the less common furagin, solafur, etc. are still traditionally used.

The introduction of antibiotics under the conjunctiva for the purpose of preventing purulent complications should be carried out for 5 days, which is explained by the possible incubation period of the infection.

Antibacterial therapy is combined with intravenous administration of urotropin solution in usual therapeutic doses. Also offered are agents that increase the phagocytic capacity of the body - vitamin B12 and pentoxyl.

An important point in the conservative treatment of penetrating wounds of the eyeball is the implementation of desensitizing therapy aimed at normalizing the body's response to injury. In addition to the well-known and widely used in the clinic calcium, diphenhydramine, suprastin, pipolfen, corticosteroid drugs have been used in ophthalmology for many years. These include cortisone, dexamethasone, dexazone. Among the group of immunosuppressants, they have the most pronounced therapeutic effect. In addition to antiallergic activity, the named glucocorticoids have a strong anti-inflammatory effect. They inhibit the development of connective tissue and reduce capillary permeability.

In penetrating wounds of the eyeball, corticosteroids are now actively used, from the first day after the injury. Previous statements that the administration of corticosteroids should be postponed for 4-7 days due to their inhibition of the wound scarring process do not always have supporters at present. Early use of cortisone and dexazone promotes the formation of a more delicate scar (this has been proven clinically and histologically), and some prolongation of the terms of its formation is not of fundamental importance in the conditions of modern microsurgery, which ensures proper sealing of the cavity of the eyeball.

Cortisone (dexazone, dexamethasone) is usually administered subconjunctivally simultaneously with antibiotics, which are prescribed for the purpose of preventing purulent infection. Cortisone is used in the form of a 0.5-1% suspension in a dose of 0.2-0.5 ml. For extensive wounds with signs of intraocular infection, 0.1 ml of dexazone or dexamethasone solution is injected into the vitreous body (along with antibiotics).

Table. **Doses of antibiotics for topical use (1000 units correspond to 1 mg)**

Preparation	Under the conjunctiva	Into the vitreous body (in 0.1 ml of physiological solution)
Monomycin	10-25 thousand units	1-2 thousand units
Gentamicin	20-40 mg	2-5 mg
Oxacillin	50 thousand units	2-5 thousand units
Ceporine	50 thousand units	2-5 thousand units
Polymyxin	25-50 thousand units	

The injection site depends on the location of the wound or the position of the foreign body. Instillations of 1% suspension of cortisone, hydrocortisone or dexamethasone are prescribed for the entire period of active treatment of the patient in the hospital and then on an outpatient basis. Penetrating wounds of the eyeball are often (on average, according to the literature, in 15%) accompanied by hemorrhagic syndrome: hyphema, hemorrhage into the vitreous body and the eye membranes.

Without dwelling on the details of the clinic, classification and features of the course of eye hemorrhages in penetrating trauma, which is covered in detail in the literature, in particular by P.I.Lebekhov (1974), we note that if hyphema, as a rule, ends with the absorption of blood, then hemorrhage into the vitreous body can cause loss of vision and retinal detachment. Treatment of hemorrhages involves complex multidisciplinary therapy, which, in addition to the conservative aspect, also includes a surgical aspect (removal of the hyphema and operations on the vitreous body with the removal of blood clots from it and replacement of the substance with a saline solution).

In case of hyphema, the patient should be provided with rest (to prevent relapses) and an elevated position of the head in bed. Traditionally, well-known osmotherapeutic agents are used in the clinic - such as calcium chloride, sodium chloride, sodium iodide (10% solutions intravenously), 40% glucose solution intravenously.

Chymotrypsin is widely used as an absorbent in the form of intramuscular injections of 5-30 mg (20 per course). Chymotrypsin injections in a dilution of 1:1000 or

1:500 of 0.3-0.5 ml (10-15 per course) are also made under the conjunctiva.

Fibrinolysin has proven itself in the clinic. It is administered subconjunctivally in a dose of 300-500 units, no more than 10 injections per course.

Papain, an enzyme of plant origin, is recommended for these purposes. 1-2 mg of the drug diluted in 0.3 ml of physiological solution is prescribed under the conjunctiva.

The vitreous body has a mild effect on eye hemorrhages (2.0 ml intramuscularly in the amount of 20 injections per course). The active drug is lidase, but it should be used with caution since lidase increases the permeability of the vascular wall, and in the case of fresh hemorrhages it is not recommended. Forms of application of lidase: intramuscularly 64 units, per course of 15-20 injections; under the conjunctiva 8-16 units in the amount of 5-10 injections.

Autohemotherapy and physiotherapy have an undoubted therapeutic effect on hyphema: electrophoresis with the above-mentioned drugs (calcium chloride, chymotrypsin, papain, iodine preparations, vitreous body).

In addition, ultrasound therapy is used; phonophoresis with medicinal substances of resorptive action has proven itself especially effective.

The use of miotics and mydriatics in hyphema should be selective, depending on the level of intraocular pressure, the presence of signs of iridocyclitis, the condition of the pupil, etc. In the absence of the desired effect from conservative therapy for 1-2 weeks, when further presence of blood in the anterior chamber is fraught with such complications as increased intraocular pressure, imbibition of the cornea with blood, the question of evacuation of the hyphema should be raised. But in each case it is necessary to approach this individually, taking into account not only the possible positive but also the negative impact of early surgery on the course of the post-traumatic period.

Treatment of hemorrhages in the vitreous body depends on the amount of blood spilled and the duration of hemophthalmos. In general, therapy should be multidisciplinary and long-term, since the processes of absorption in the vitreous body are extremely slow.

Therapeutic agents used to treat hemorrhages in the vitreous body are basically the same as those used to treat hyphemas. These are osmotherapeutic drugs, enzymes, and angioprotectors.

However, as experience in the clinic and information from modern literature show, the greatest preference is given to such drugs as dicynone, fibrinolysis, heparin, and papain.

To a certain extent, this was facilitated by clinical studies conducted by G.L.Starkov and co-authors (1977), as well as the study of tissue factors of blood coagulation and fibrinolysis in traumatic hemophthalmos (A.D.Romashchenko, 1978, 1979). The data of A.D.Romashchenko indicate that in order to accelerate the processes of blood absorption in the vitreous body, it is advisable to include direct-acting anticoagulants and fibrinolysin activators in the complex of therapeutic agents.

Treatment of traumatic hemophthalmos with Dicynone consists of subconjunctival, para- or retrobulbar injections of the drug at 0.5 ml in combination with intramuscular administration of it at a dose of 1.5 ml and taking tablets (1 tablet 3 times a day). The course is designed for one month.

Fibrinolysis is used in the same dose and form as in the treatment of hyphema.

Heparin can be used both retrobulbarly at 500-750 units (in the amount of 10-15 injections), and in the form of electrophoresis.

Papain is especially valuable in hemophthalmos with a torpid course and slow resorption of blood. It is administered under the conjunctiva at 1-2 mg in 0.3 ml of physiological solution (once every 2-3 days, for a course of 10-12 injections; repeated courses are carried out after 2-3 months). Recently, electrophoresis with papain has been used, in particular endonasal.

Ophthalmological literature states the fact that up to 80% of patients with traumatic hemophthalmos lose their sight as a result. Therefore, the efforts of specialists aimed at developing various methods of surgical treatment of this process are quite natural. Blood poured into the vitreous body is not indifferent to the tissues of the eye, and the process of formation of connective tissue begins early and causes severe complications. Based on this, there are proposals for early removal of blood from the eye cavity, 3-7 days after the injury (E.G.Rapis, 1979).

One of the tasks of conservative treatment of penetrating wounds of the eyeball is the stimulation of regeneration processes. This therapeutic profile provides for the improvement of metabolic

processes and hemodynamics both in the eye and in the entire body.

For this purpose, vitamins of group B (injection courses in usual therapeutic doses) and vitamin A are useful. Biogenic stimulants, which simultaneously have a resorption effect, are widely used: aloe extract, vitreous body, and fibs. Blood plasma transfusions, gamma globulin, and rheopolyglucin are used to activate metabolic processes. Microcirculation is normalized by nicotinic acid, the intake of which improves the blood supply to the ciliary body due to its vasodilatory and disaggregating effect. Cocarboxylase and riboflavin mononucleotide belong to the agents that affect tissue metabolic processes. In their biological action, they are close to both vitamins and enzymes.

Cocarboxylase is administered intramuscularly at 50-100 mg, for a course of 20-30 injections, and a 1% solution of riboflavin mononucleotide at 1 ml in the amount of 15 injections. Subconjunctival injections of riboflavin mononucleotide (1% solution at 0.2-0.5 ml) are possible.

Recently, there have been reports in the literature on the positive effect of magnetophores on penetrating wounds of the eyeball (M.V.Zaykova, 1978; G.G.Kalmetyev, 1978, 1979). Magnetotherapy normalizes metabolic processes, has a stimulating effect on regeneration, especially of corneal wounds, and has anti-inflammatory and analgesic properties. In case of penetrating wounds of the eyeball and contusions with rupture of the sclera, one should remember about tetanus prophylaxis. It should be carried out either using antitetanus serum or (in the vaccinated group of people) by introducing tetanus toxoid under the skin.

Treatment of contusions of the eyeball should be based on the multidisciplinary pathogenesis and polymorphic clinical picture of this type of injury. All victims with severe contusions and even moderate contusions should be hospitalized according to the same principle as patients with penetrating wounds, i.e. in a large city - at the place of primary treatment; in districts and rural areas, patients with severe injuries, including those requiring surgical treatment, are most appropriately sent to a trauma center, where highly qualified diagnostic and therapeutic care will be provided. Patients with mild contusions of the eyeball are usually treated on an outpatient basis.

Treatment should begin with ensuring the victim's rest, prescrib-

ing painkillers and sedatives. This is necessary due to the severe pain syndrome and the body's general reaction to blunt trauma to the eye, which is an extensive reflexogenic zone.

The patient is recommended to stay in bed in the hospital, and the position of the head should be chosen taking into account the presence of blood in the vitreous body and the hypophemia (in the latter case, elevated). Analgin is usually used as an analgesic, and valerian and minor tranquilizers (trioxazine, tazepam, etc.) are used as sedatives.

The condition of deep vasopathy with increased permeability of the vascular wall justifies the use of therapy that strengthens the vascular wall, dehydration and resorption as basic treatment measures. In modern pharmacotherapy of eye contusion, especially in cases with hemorrhagic syndrome, Dicynone is used (orally, intramuscularly, and subconjunctivally in the doses indicated in the section on the treatment of penetrating wounds), along with rutin tablets, ascorbic acid, and calcium preparations in standard dosages. A 40% glucose solution administered intravenously at 10-20 ml, a 25% solution of magnesium sulfate (intramuscularly at 10 ml) have a dehydrating effect.

The literature notes the beneficial effect of glycerin when taken orally, as well as diacarb (0.25) and hypothiazide (25-50 mg) for three days.

Of the resorbable agents for contusions, such drugs as chymotrypsin, vitreous body, and autohemotherapy are used in the clinic. It is better to use the named agents in the first week after the injury in the form of intramuscular injections, limiting their subconjunctival administration and excluding physiotherapy. In the second week, resorbable therapy can be activated, increasing the number of administered drugs. In addition, it is possible to use chymotrypsin and fibrinolysin in the form of subconjunctival injections (all doses are indicated in the first section of this chapter).

Further, by the end of the second - beginning of the third week after the injury, it is advisable to include physiotherapy - electrophoresis with chymotrypsin, vitreous body, calcium chloride, as well as ultrasound therapy. Active resorption agents such as lidase (intramuscularly, under the conjunctiva, or in the form of electrophoresis - doses see above), as well as

papain, can be switched to only by the end of the first month after the injury.

Such careful administration of drugs, limitation of local procedures is aimed at not aggravating the pronounced vascular reaction characteristic of contusion, and not causing repeated hyphema, hemophthalmos, or hemorrhage in the membranes of the eye.

Particular attention should be paid to the issue of normalization of ophthalmotonus in blunt trauma. The variety of ophthalmotonic reactions in the post-contusion period and alternation of hypotension and hypertension require constant attention from the attending physician and timely correction of the intraocular pressure level. In the case of hypertension, it is recommended to use general action agents that normalize pressure and reduce the secretion of aqueous humor. These include the well-known ophthalmologist's tablet preparations of diacarb, furosemide, and glycerol. An old but rightfully deserved remedy is leeches on the temple. The use of miotics to reduce intraocular pressure should be limited in the first week after injury due to possible relapse of hyphema.

In general, miotics, medicinal drugs, especially such strong ones as atropine and scopolamine, as well as resorbing agents - dionine, which in increasing concentrations from 1 to 6-8% still sometimes finds a place in the treatment of contusions, should be used at the beginning of the postcoitus period with great caution, and even better - should be completely excluded. As shown by the in-depth study of G.A.Petropavlovskaya (1960, 1975), G.M.Shelngovskaya (1963) and others, the named drugs in conditions of deep vasopathy cause complications in the form of repeated hemorrhages in the eye cavity and an increase in intraocular pressure. The use of strong miotics to create miosis in an attempt to correct traumatic mydriasis or to relieve hypertension sometimes leads to severe iritis and the formation of posterior sneezes.

Therefore, if pupil dilation is urgently needed, it is preferable to use a 2% solution of ephedrine, a 1% solution of phenylephrine, or adrenaline 1:1000, as they act more mildly and for a shorter duration.

Recently, more and more statements have appeared in the literature in favor of using corticosteroids in the treatment of contusions, bearing in mind that they reduce the permeability of biologi-

cal membranes, and, therefore, in conditions of edema and hemorrhage, they are quite justified.

At the same time, the inflammatory reaction of the eye tissues to injury is reduced. However, it is known that corticosteroids can cause an increase in intraocular pressure, and there is evidence that they slow down the resorption of hyphema. At the same time, clinical practice shows that subconjunctival injections of cortisone, and even better dexazone, their use in the form of drops, provide a positive therapeutic effect without causing any visible complications.

The presented information is based on the analysis of literature data, as well as on our own clinical experience. However, the presented materials are only a guideline for a practicing ophthalmologist. In the case of a very complex symptom complex of mechanical eye trauma, an individual approach is needed - treatment not of the disease, but of the patient.

In addition, in the case of penetrating wounds and eye contusion, it is probably impossible to limit oneself to "instant" treatment. An important moment in a good outcome of eye trauma is active monitoring of the victims, i.e., medical examination. It allows for the timely detection of complications in the post-traumatic period, corrective treatment, preservation, and, if possible, the improvement of visual functions.

Chapter 5

TOXIC-CHEMICAL DAMAGE TO THE ORGAN OF VISION IN TIRE PRODUCTION

Occupational eye diseases, like diseases of other organs and systems, are rarely strictly specific in their clinical picture. Occupational hazards usually have a multifaceted effect: they cause general shifts in the body with various changes in individual organs and systems. In some cases, eye damage is an early or leading sign of intoxication. When analyzing literature data on occupational eye diseases, it is noteworthy that the leading place is occupied by works devoted to the study of damage to the organ of vision caused by salts of heavy metals.

As is known, it is not so much the metal itself that is toxic as its compounds used in industry: white lead, lead carbonate, lead dioxide, lead chromate, lead oxide, tetraethyl lead, as well as lead salts that are easily soluble in organic liquids

(tetraethyl lead, etc.). Poisoning most often occurs as a result of lead absorption in the form of vapors or dust through the respiratory tract. From the lungs, lead enters the blood. Tetraethyl lead can also penetrate the skin, causing general poisoning.

There are cases of damage to the organ of vision as a result of the toxic effect of lead gasoline. The appearance of various eye symptoms in cases of lead poisoning depends on changes occurring in the central nervous system, blood vessels, and the nerve elements of the retina and the optic nerve.

As for the pathology of the optic nerve in chronic lead intoxication, it manifests itself as a uniform narrowing of the visual field without scotomas; less commonly, extensive central scotoma is encountered with normal visual field boundaries.

Of interest are the facts of the violation of the regulation of intraocular pressure in lead poisoning.

It is believed that the occurrence of glaucoma is associated with the violation of the activity of the neuroreflex apparatus regulating ophthalmotonus, which occurs under the influence of a vasotropic poison, which is lead.

Poisoning with mercury and its compounds (calomel, mercury nitrate, corrosive sublimate) can occur in workers engaged in the production of thermometers, barometers, X-ray tubes, electric lamps, mercury rectifiers, in chemical and physical laboratories, in the pharmaceutical industry, in mines, etc.

Data on changes in the organ of vision in people exposed to chronic mercury intoxication are sparse. There is a decrease in the sensitivity of the cornea, a concentric narrowing of the field of vision for white and chromatic colors, a distortion of the boundaries of the color field of vision, an increase in the blind spot, a violation of light sensitivity, and a change in the optic nerve discs in the form of a blurring of their boundaries.

Mercury deposits in the lens are observed in workers in mercury shops with long service (10-20 years). An ophthalmologist should be aware of poisonings that can occur among miners exposed to dust in manganese ore mines, as well as in the metallurgical industry when adding manganese to steel since this creates large concentrations of manganese vapor in the air of the shops.

With prolonged exposure to high concentrations of manganese vapors or dust, a complex of neurological phenomena develops that

resembles Parkinson's syndrome, trophic disorders, and blood changes. Convergence disorders, nystagmus, infrequent blinking, uneven pupils, and narrowing of the visual field are observed in the eyes.

Industrial poisons with general toxic action include benzene, obtained during dry distillation of coal or during contact-catalytic decomposition of oil. Benzene, as well as toluene and xylene, are good solvents for rubber, paints, varnishes, fats and other substances. Benzene plays an important role in the production of aniline dyes, phenol, picric acid, in the manufacture of artificial leather, and in the rubber industry.

From the point of view of possible professional poisoning, benzene derivatives are very dangerous, in particular its nitro compounds (mono-, di-, trinitrobenzenes) and amino compounds, primarily aniline. Workers in aniline dye production may have changes in the anterior part of the eye in the form of chronic blepharitis, conjunctivitis, impaired lacrimation, changes in the boundaries of the field of vision for white and chromatic colors, as well as decreased sensitivity of the cornea.

In their practical work, many doctors encounter conjunctivitis. Trinitrotoluene has a specific effect on the visual organ, which penetrates the body through the skin, respiratory organs, and partly the gastrointestinal tract.

With prolonged exposure to trinitrotoluene, cataracts may develop. It is possible that nitrotoluene directly affects the lens, entering the eye through its anterior section.

It is also believed that in the mechanism of formation of such cataracts, a certain role belongs to the disruption of metabolic processes in the lens, which depends on the state of the eye vessels and is also associated with the general toxic effect of nitrotoluene.

The degree of visual acuity reduction is directly related to the intensity of lens opacity.

One of the most common industrial gases and one of the most powerful toxic substances is carbon monoxide, which is formed as a result of incomplete combustion of coal and other organic products with insufficient air. Carbon monoxide poisoning is possible even with an insignificant content of it in the air. With carbon monoxide intoxication, there may be a significant decrease in corneal sensitivity.

Acute and chronic poisoning can occur under the influence of such intermediate products of oil

refining as hydrogen sulfide, hydrocarbons and other fractions of petroleum gases. An ophthalmologist, especially one connected with industrial production, is interested in knowing about the toxic effect of hydrogen sulfide and hydrocarbons on the eye.

Ophthalmological symptoms in this type of intoxication are characterized mainly by changes in the anterior segment of the eye in the form of catarrhal irritation of the conjunctiva, decreased sensitivity of the cornea, and the appearance of small superficial infiltrates in it. The degree of expression of changes depends on the length of service and duration of contact with the above substances. Changes in the optic nerve are described in the form of hyperemia and blanching of the disc. This is accompanied by a narrowing of the peripheral boundaries of the visual field. Spasms of retinal vessels are also possible.

An interesting fact is the rather frequent occurrence of conjunctivitis and keratoconjunctivitis in workers in the spinning shops of viscose and sulfate-cellulose production, which is also associated with the harmful effects of hydrogen sulfide and dimethyl sulfate.

Changes in the eyes are expressed in photophobia, conjunctival hyperemia, decreased sensitivity of the cornea, and punctate superficial keratitis. Sometimes paralysis of the external muscles of the eye and nystagmus occur. The most typical is the appearance of a central scotoma, which can be accompanied by a narrowing of the boundaries of the field of vision. Another type of intoxication is possible in workers in the chemical industry, developing as a result of chronic poisoning with methyl alcohol vapors (methanol).

In this case, changes in the fundus of the eye are observed in the form of hyperemia of the optic nerve discs, optic neuritis with edema, retrobulbar neuritis, and anemia of the optic nerve discs. The process is accompanied by the appearance of central scotomas both with normal visual field boundaries and in combination with the narrowing of its boundaries.

Among common occupational diseases, a large place is occupied by lung diseases caused by inhalation of mineral dust. Their most common form is silicosis, which occurs as a result of contact with quartz dust.

There is little evidence of eye damage from exposure to mineral dust. Severe irritation of the mucous membrane of the eye by mica dust contained in the air of indus-

trial premises is possible. Workers at a refractory plant where chemicals such as coal and quartz are used show a sharp drop in corneal sensitivity, especially after 3-4 years of work.

Chemical fertilizers are becoming increasingly important in increasing crop yields. Among them, pesticides produced by the chemical industry - organochlorine and organophosphorus pesticides - occupy an important place. Preparations of these same groups are also widely used in anti-epidemic measures.

At present, the clinical picture of acute and chronic intoxications developing with separate exposure to chlorine and organophosphorus pesticides has been well studied.

Visual impairments are revealed in workers at chemical plants who have been exposed to aliphatic alcohols for a long time (10-15 years) when they are present in the air of industrial premises in quantities significantly lower than the maximum permissible concentrations.

The toxic neurotropic effect of furfural, which along with tetraethyl lead is widely used in the oil refining industry, is known. When exposed to furfural and ethyl liquid, a decrease in corneal sensitivity and a transient disruption of intraocular pressure regulation are observed.

Synthetic substances are finding ever wider applications in various fields of industry and technology.

At present, information is appearing about the harmful effects of substances used in the production of synthetic rubber (at high concentrations) on the organ of vision. It can be said with certainty that various toxic-chemical substances in vaporous or liquid form (vapors of propyl, butyl, ethyl alcohol, vapors of many acids and alkalis) cause irritation of the eyelids and the mucous membrane of the eyes. The changes are mainly localized in the eye slit. They are of the nature of "short-lived" painful sensations and seem to signal air pollution with harmful gases. Some researchers also cite data on a number of other harmful chemical substances used in various industries that affect the organ of vision. These include dinitrobenzene, salicylic acid, chromic acid, and acetone. The combined action of these substances' causes, against the background of spasms of the retinal vessels, a transient blanching of the optic nerve disc.

It is especially necessary to dwell on the complex impact of chemical production factors on the

organ of vision during tire manufacturing since such productions occupy a large volume in the country's industry. Meanwhile, the issue of the impact of harmful factors of tire production on the organ of vision has been little studied.

Sanitary and hygienic characteristics of working conditions. Industrial hazards. Tire factories produce pneumatic automobile tubes and rubber tires, the manufacture of which takes place in preparatory, auto-tarring, calendering, assembly and vulcanization shops. The technological process of tire manufacturing consists of the preparation of ingredients for production, rubber plasticization, preparation of rubber mixtures, pastes, adhesives, emulsions and lubricants, manufacture of tire parts, assembly, formation and vulcanization of them, manufacture of auto-tubes and bypass lines. Each of these stages is an independent technological process.

Tyre production requires the use of various chemicals and takes place in different microclimatic conditions in the presence of noise. These factors are more pronounced in the preparatory and vulcanization shops. The main professions are sorters-packers, loaders, unpackers, cutters-rollers, operators, rubber mixer operators, weighers of rubber, soot and bulk ingredients, duty and repair fitters, lubricators, vulcanizers, cutters, packers.

The work of sorters, stackers, loaders, and unpackers in the raw material preparation shop is associated with sorting, stacking, and carrying materials arriving at the plant: rolls of cord, rubber, soot, and chemical ingredients. This group of workers works under significant physical strain and is constantly exposed to dust, containing chemicals.

The work of a rubber cutter, roller, rubber, soot, and bulk ingredient hanger is associated with intense attention, noise, exposure to talc dust, and physical strain. Rollers involved in the preparation of rubber mixtures on mixing rollers and loading of raw materials are also exposed to high temperatures, sulfur dust, and carbon monoxide.

The work of a loader of carbon black, rubber and chemical ingredients is performed indoors in an atmosphere of high dustiness of these substances and is associated with physical exertion.

Rubber mixer operators are busy loading rubber, carbon black and ingredients in accordance with technological regulations. Their work is associated with physical

exertion, the influence of dust and carbon monoxide.

Analysis of external meteorological factors showed that climatic conditions are characterized by elevated air temperature, high relative humidity and high air mobility (during windy periods). Under these conditions, the microclimate of workplaces is characterized by elevated air temperature not only due to external meteorological factors, but also as a result of heated surfaces, equipment, devices, and installations that are not yet sufficiently insulated.

The production process in warehouses is characterized by a large number of dust-forming moments, as a result of which there is a high level of air pollution with talc, talc dust and other chemical ingredients.

The air in the cutter's workplace is polluted with talc dust and soot penetrating from the adjacent room.

The soot is delivered to the warehouse by trucks in paper bags, unloaded by loaders and stored, which is also a source of air pollution with soot. The preparation of rubber mixtures is carried out in a rubber mixer - a mechanized unit. The composition of the rubber mixtures includes pastes - a mixture of an accelerator with one of the softeners.

All professions in the preparatory shop are characterized by exposure to talc dust and soot. In addition, there is dust contamination of the air in all areas of the preparatory shop due to hydrocarbons and carbon monoxide, as well as dust contamination of the air due to chemical ingredients used in smaller quantities.

The main air pollution by vaporous hydrocarbons is observed in the paste production area (due to accelerators and softeners) and in the rubber compound production area. Carbon monoxide is also released here. These vapors are also formed during the rolling of the rubber compound. More significant concentrations of hydrocarbons and carbon monoxide are observed in the area of preparation of adhesives, lubricants and suspensions.

In the inner tube and vulcanization shops, the release of hydrocarbons is associated with the use of glue diluted in gasoline. In the inner tube shop, vaporous hydrocarbons and nitrogen oxides are released.

In the vulcanization and calender shops, air pollution is associated with the presence of an increased concentration of carbon monoxide

vapors, especially at high temperatures and air humidity.

As can be seen from the information provided, the process of manufacturing tires and inner tubes takes place in conditions of dustiness and air pollution with dust, vaporous hydrocarbons and carbon monoxide. The thermal factor also has a certain effect on the body.

Labor processes are associated with the use of physical effort, require significant neuro-emotional stress and occur in conditions of intense noise. All these factors have a complex effect on the body, cause a number of functional changes and are reflected in morbidity.

The conducted studies of some physical shifts in the body of workers showed that after work, mainly under the influence of physical exertion and partly under the influence of noise, and in summer also high air temperature, an increase in pulse rate is noted, in some workers after a shift, blood pressure increases.

Physical strain during carrying, re-laying tube sleeves, and lifting tires lead to changes in the strength and endurance of the hand muscles. This leads to a decrease in work capacity by the end of the working day. A decrease in work capacity indicators after work was observed in most workers (both men and women), especially in the summer.

Thus, the study of sanitary and hygienic working conditions of workers at a tire plant shows that in each shop the worker experiences the influence of a complex of production factors in various combinations, including toxic factors. They are most pronounced in the preparatory, vulcanization, calendering shops and in the raw material preparation shop.

Ophthalmological service. In accordance with current requirements, the eye room of the medical and sanitary part of the enterprise must be equipped with the necessary equipment and tools. There should be a table with side lighting, an ophthalmoscope with a set of magnifying glasses, a binocular head-mounted magnifying glass, a table for examining visual acuity, a table for examining color vision, a perimeter, a Maklakov tonometer, a slit lamp, a gonioscope, skiascopy rulers, a set of hairs for examining corneal sensitivity, a Kravkov-Vishnevsky camera, i.e., virtually all the equipment for a high-quality examination of a patient that an eye clinic in any outpatient clinic has.

Examination of workers by an ophthalmologist should be carried

out according to a certain scheme, including determination of visual acuity without correction and with correction, perimetry for white, blue, red, green colors, determination of light sensitivity, sensitivity of the cornea, examination of intraocular pressure, which in the order of this list should take the last place. In addition to the functional examination with a certain periodicity, it is necessary to carefully examine the eyelids, conjunctiva, anterior segment of the eyeball, optical media and fundus. Since now almost all eye offices are equipped with slit lamps, we strongly advise doctors to use biomicroscopy and gonioscopy methods when examining the contingent of workers in the chemical industry. The ophthalmologist of the enterprise is required to master the technique of diffuse, direct focal and diaphanoscopic illumination.

When examining the cornea, its sensitivity is determined at the same time. Biomicroscopy of the nerve trunks provides very valuable information for assessing the trophism of the cornea.

When examining the iris, it is necessary to note possible signs of tissue dystrophy. Particular attention is paid to biomicroscopy of the lens in search of cataractous changes. Possible signs of vitreous destruction are taken into account. Finally, during ophthalmoscopy (bio-micro-ophthalmoscopy), carried out with sufficient mydriasis, the doctor pays attention to the condition of the optic nerve disc (color, boundaries, level of location in relation to surrounding tissues), the retina and choroid.

The vascular bundle of the retina is especially highlighted during examination.

The data from the examination are recorded in the corresponding registration card, which facilitates subsequent dynamic monitoring of the worker's condition.

Clinical manifestations of toxic-chemical effects on the organ of vision. The results of the ophthalmological studies presented below are based on an analysis of the condition of the organ of vision in 1,281 workers at the tire plant.

Half of those working at the plant are 21 to 30 years old (54.3%), and one -quarter of all workers are 31 to 40 years old (25.6%). It is noteworthy that the proportion of young people is insignificant, and only 8.7% of those working under 20 years old.

At the same time, the older workers were concentrated mainly in departments where chemical factors act to a lesser extent - in the electric power and transport

shops, the design and engineering department, the technical control department and the economic department.

Of the workers examined, almost three-quarters were men (891 patients) and only one-quarter were women (390 patients), which indirectly indicates the difficult working conditions at this enterprise. Half of the workers had two to five years of work experience at the plant. Depending on the degree of contact with chemical ingredients, the entire contingent of workers was divided into two groups.

The first group included workers from the calendering, preparatory and vulcanization shops, as well as the raw material preparation shop, where there is a more significant impact on the body of toxic substances and periodically there are concentrations of chemical ingredients that exceed the maximum permissible concentration (MPC).

The second group included workers from other plant divisions. These individuals also had constant or periodic contact with chemical ingredients, however, maximum permissible concentrations (MPC) were not exceeded at their workplaces.

During an external examination of the appendages and anterior segment of the eyes of tire plant workers, changes in the eyelids, conjunctiva and cornea in the form of blepharitis, chronic conjunctivitis, blepharoconjunctivitis, and corneal opacity were detected in a third of cases.

It is noteworthy that in the presence of the above changes, complaints of painful sensations from the eyes are usually not noted. This is the case even with corneal damage. The reason for seeking medical help is usually cosmetic changes (redness of the eyelids and conjunctiva, foamy discharge, etc.). We have suggested that the discrepancy between the objective changes in the outer part of the eye and complaints may be explained by the anesthetic effect of a complex of chemical ingredients constantly present in the atmosphere of the tire plant workshops.

The revealed changes in the outer part of the eye in tire plant workers should be assessed as specific, caused by the action of toxic-chemical factors. This is supported by data on the frequency of changes in the external part of the eye in plant divisions with concentrations of chemical ingredients that exceed and do not exceed the MAC.

In workers of hazardous workshops, a direct dependence of changes in the external part of the

eye on the length of service at the enterprise has also been determined.

The clinical picture of the detected changes in the eyes of workers of workshops with an increased concentration of chemical ingredients is distinguished by a number of features.

In the absence of typical complaints of burning, itching, a feeling of a foreign body in the conjunctival cavity, scanty mucopurulent discharge is detected during the examination.

Biomicroscopy of the eyelids shows blood vessels passing from the conjunctiva to the intercostal space of the eyelids, retention cysts of the sweat glands of Moll. A ring of hyperemia is found at the base of the eyelashes. The expansion of the intermarginal space, which has an oily surface, is clearly recorded.

In patients with conjunctivitis, significant thickening of the conjunctiva of the eyelids is noted, which has a cloudy yellowish appearance. In the area of the cartilage of the eyelids, slightly protruding meibomian glands are outlined in the form of bead-shaped columns. The conjunctiva above the cartilage is hyperplastic, rough, its shine is lost.

Very often, punctate hemorrhages are detected on the conjunctiva of the eyelids. The lacrimal caruncle, as a rule, is edematous and hyperemic, sometimes hair growth is noted on it.

The indicated changes are more pronounced in the lower eyelid (Fig. 42).

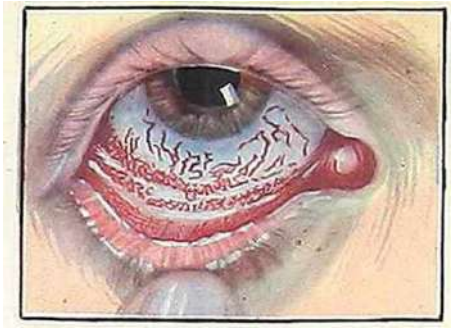

Fig. 42. **Toxic chemical blepharoconjunctivitis**

The limbal area is widened (more at 3 and 9 o'clock), the marginal looped network of vessels is strengthened.

In the area of the palpebral fissure on the nasal and temporal sides, the conjunctiva is thickened, its transparency is reduced. Sometimes formations of the pinguecula type are differentiated here, protruding 2-3 mm above the level of the sclera and resembling a tumor-like growth.

Some workers had conjunctival pigmentation in the form of brownish spots. A thorough biomicroscopic examination revealed

the localization of dust-like pigment in the superficial layers of the conjunctiva. There was no vascular halo around the pigment or change in the course of the conjunctival vessels.

Significant pathological changes are determined in the vascular network of the conjunctiva. To assess these changes, a biomicroscopic examination in colorless light should be used, which makes it possible to analyze the symptoms detected at the microcirculatory level. Typical is the compaction of the vascular wall, tortuosity (corkscrew-like) of the course of not only small branches, but also medium, and in some cases, large vessels. The lumen of the vessels is uneven. Often, dilations and aneurysms of the trunks are detected, having different appearances: punctate, club-shaped, spindle-shaped. The presence of small petechial hemorrhages, scattered over the entire surface of the conjunctiva of the sclera in the area of the eye slit, but especially often encountered in the perilimbal zone, attracts attention.

Along with the intensification of the vascular pattern in the marginal looped network, branches are revealed that encircle the cornea in a circle. This is especially clearly expressed in the meridians 2-5 and 7-11 o'clock in the palisade zone. Anastomoses are visible between such ring vessels. In the zone of terminal capillaries, there are branches that penetrate into the transparent tissue of the cornea. Granular blood flow is observed in the vessels of the conjunctiva of the sclera, indicating the presence of local hemocoagulation disorders.

In some cases, tortuous cords with a thin wall filled with a transparent, colorless liquid were detected. The appearance of such elements is not typical for aqueous veins, so we assessed them as lymphatic vessels, which are usually not found in the norm.

The described changes on the part of the conjunctiva are quite common, with the addition of unfavorable meteorological factors - more than half of those working in tire production.

Long-term observations with analysis of symptoms of damage to the adnexa of the eye in workers of a tire plant led to the need to develop differential diagnostics of conjunctivitis of occupational toxic origin with conjunctivitis of viral and bacterial nature. The basis of differential diagnostics was clinical features of conjunctival damage, supported by the results of laboratory (bacteriological and cytological) studies taking into account anamnestic data. The revealed clinical

features of viral conjunctival damage fit mainly into three clinical forms described earlier in our country and abroad: acute epidemic adenoviral keratoconjunctivitis, acute epidemic hemorrhagic conjunctivitis and pharyngoconjunctival fever.

The most severe clinical picture was characterized by epidemic viral keratoconjunctivitis, which often develops in the colder season, during periods of changing air temperature, increased humidity, and during periods of strong winds.

As for conjunctivitis caused by professional factors, i.e. the influence of various chemical reagents, its clinical picture differs from the above-described forms by the following elements. Professional conjunctivitis does not have a mass (epidemic) character when it occurs. As a rule, both eyes are affected. In this case, blepharitis phenomena always occur. Hyperemia of the skin of the eyelids and madarosis are observed. The conjunctiva is hyperemic, loosened and edematous, but it lacks follicular elements, so typical of epidemic conjunctivitis. Regional lymphatic glands are intact. Superficial infiltrates appear in the cornea; however, they are unstable and quickly resolve under the influence of nonspecific treatment.

Despite the fact that conjunctivitis of occupational toxic origin resembles conjunctivitis of bacterial etiology in its clinical picture, it is not accompanied by copious discharge from the conjunctival cavity. Patients often complain of general malaise, weakness, and headache. When appropriate measures are taken with temporary removal of the patient from the work area (in combination with symptomatic local treatment), all these phenomena gradually disappear without a trace, which once again confirms the occupational nature of the disease.

As already indicated, the presence of exogenous keratitis was established in individual cases during the inspection of factory workers. It usually develops against the background of blepharoconjunctivitis. Changes in the cornea are of a bilateral nature and are found in people who have worked in workshops with increased content of chemical ingredients for 5 years or more.

Opacities of the cornea were found both in the peripheral and in the central sections and had an irregular or rounded shape. In some cases, they merged and acquired a kind of geographical map. Under

oscillatory illumination, the turbidity was opalescent at times.

Fluorescence staining was low-intensity, non-permanent and did not cover the entire area of turbidity. It had a place only in separate sections.

Biomicroscopic examination in the optical section (optical prism) revealed a very superior arrangement of the mottling (Fig. 43).

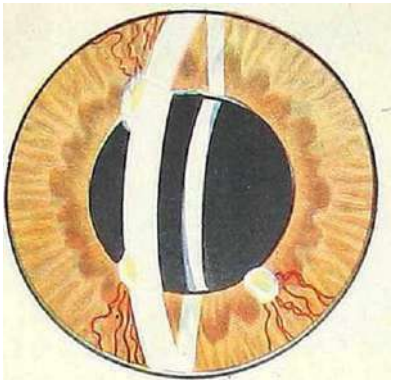

Fig. 43. **Exogenous keratitis**

At the same time, folds of the Bowman's membrane were found. In the transmitted light, edema of the epithelium and branches of surface vessels localized under the epithelium were clearly visible. Granular inclusions of gray-white color and weakly contoured dark interlayers were noted in the stroma of the cornea under the areas of surface opacities - watery cracks, indicating the presence of edema of the stroma of the cornea. Changes in the endothelium of the cornea were not noted in one case. Point deposits of pigment were visible on the posterior surface of the cornea.

It is noteworthy that decreased corneal sensitivity was also observed in workers in other plant departments. It was noted in 33.9-43.4% of all those examined in the assembly, tube, tire repair, mechanical repair, and electrical power shops, whose workers, due to the specific conditions of their work, only periodically participate in the main production cycle and have contact with chemical hazards. At the same time, in such departments as the transport shop, plant laboratory, and economic department, whose workers are significantly less exposed to chemical intoxication, decreased corneal sensitivity was observed in only 16.4% of those examined, that is, 2-3 times less often than in the main plant shops.

The factor of the decreased sensitivity of eye tissues plays a major role in the implementation of pathological changes in the eyelids, conjunctiva and cornea, which were discussed above. The most severe clinical forms of manifestation of blepharoconjunctivitis, the development of pinguecula, pterygium, and keratitis were found in

workers with complete anesthesia of the cornea.

The obtained facts give grounds to believe that decreased corneal sensitivity is an early and reliable sign of the toxic effects of chemical hazards on the visual organ in tire production workers. Moreover, decreased sensitivity increases depending on the length of service in the workshops, where, in particular, the content of chemical ingredients in the air does not exceed the maximum permissible concentration.

Thus, it can be said with confidence that a change in corneal sensitivity is an obligatory symptom of damage to the anterior part of the eye. It precedes the development of diseases of the eyelids, conjunctiva and cornea, and its appearance depends on both the concentration of toxic substances in the plant workshops and the duration of contact with them.

When examining the iris, the ophthalmologist should focus on assessing the width of the pupil, its direct and sympathetic reaction to light, convergence and accommodation. Special attention during biomicroscopy should be paid to the condition of the pupillary belt and pigment border, which is highly sensitive to various toxic phenomena and is often the first to react to a damaging agent. The nature and extent of changes in the iris revealed during biomicroscopy are associated with both the length of service in tire production and the quantitative content of chemical ingredients in the air of the workshops. This is confirmed by our own research.

In 51% of cases, areas of depigmentation in the pigment rim of the pupil and loss, usually characteristic of velvetiness, were noted. Trabeculae in the region of the pupil and ciliary belts were covered with densely dispersed, dark and yellowish-brown pigment. Sometimes, there were lumps of pigment that looked like grains of pepper. In some cases, dark-brown large foci were visible, scattered throughout the iris, between which finely dispersed pigment was localized (Fig. 44).

A mesodermal layer of the iris was thickened. In addition, there were peculiar cases with the presence of atrophy of the stroma in the form of slits and round holes, through which a red reflex of the fundus could be seen during the examination in passing light (Fig. 45).

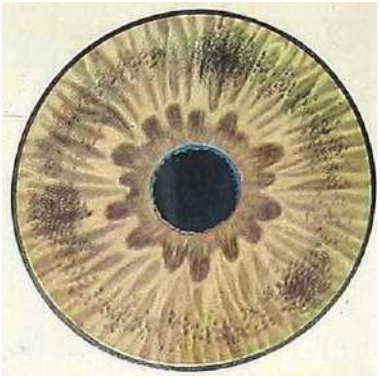

Fig. 44. **Toxic (destructive) changes in the pigment border of the pupil of the iris in a 37-year-old female worker (11 years of experience in the vulcanization shop)**

The observation of pronounced changes in the iris of the described type made it necessary to differentiate them from similar dystrophic disorders observed in primary glaucoma, as well as in the rare form of secondary glaucoma, which develops in essential mesodermal dystrophy of the iris.

In contrast to the discoloration of the pigment rim that occurs in primary glaucoma, the changes in the toxic effects of tire production were bilateral, and quite symmetrical and had the same degree of expression.

The typical symptom of disintegration of the pigmented rim, with its transformation into a colorless structure, similar in appearance to ash, was not observed. The totality of the specified changes is included in the picture of toxic iris damage under the influence of complex chemical factors of tire production.

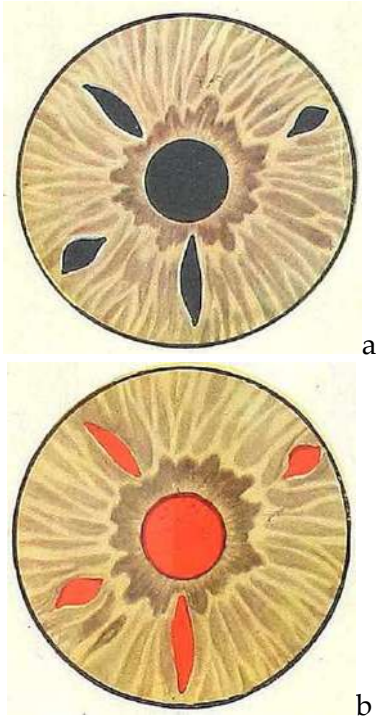

Fig. 45. **Dystrophic changes in the stroma of the iris in a 32-year-old female worker (10 years of work experience in the preparatory shop of a tire plant): a - focal illumination; b - transmitted light**

In the differential diagnosis of changes in the stroma of the iris with changes observed in mesodermal dystrophy of an essential nature, the bilateral lesion was

studied, as well as the normal position and shape of the pupillary opening in our observations.

As for the condition of the crystal, even the most careful biomicroscopy did not reveal any specific changes in it that could be related to the toxic effects of tire production. In some individuals, the presence of posterior polar cataracts was observed. In the region of the posterior pole of the lens in the optical section, a dense disk of opacification was seen adjacent to the posterior capsule. Visual acuity was kept equal to 1.0. The typical type of revealed changes and the absence of a decrease in visual acuity indicated a congenital cataract.

In some persons who worked in workshops where the content of chemical ingredients did not exceed the MPC, club-shaped radial opacities, located concentrically on the surface of the adult nucleus of the lens and having a light gray color, were determined. Observation of these individuals for two years did not reveal the progression of the specified opacities. According to the form and nature of the course, this pathology was attributed by us to presenile coronary cataracts, especially since the age of the workers was approaching 50 years.

The same applies to homogeneous diffuse clouding of gray color in the nucleus of the lens with a sharp border of separation from the transparent cortical substance. These signs made it possible to diagnose primary senile nuclear cataracts.

The insignificant number of observed changes in the lens, the congenital nature of the changes in young people and the typical picture of age-related cataracts in the rest of the workers give reason to believe that the noted pathology is not the result of the impact of occupational hazards.

Biomicroscopy of the vitreous body meets significant methodological difficulties and difficulties in interpreting the detected changes.

Apparently, the fact that the picture of toxic lesions of the vitreous body is not sufficiently studied is related to this. Therefore, we were forced to focus on the analysis of this issue.

Sharp fragmentation of the trabecular structures of the vitreous body, liquefaction of the gel and the presence of optically empty cavities were noted during phentoscopy. There were areas of increased opalescence, filamentous destruction of the stroma was often determined. These changes were

observed in people with myopic refraction and were accompanied by the presence of a temporal cone and a retinal tear.

Weak expression of the anterior membrane, splitting and fragmentation of the stroma, as well as thickening and coarsening of the plates of the vitreous body were noted quite often. Often, an increased number of dot inclusions of dark color was found in it. It is hardly possible to associate these changes with the toxic influence of chemical factors since the picture of the vitreous body is highly variable even in healthy individuals.

In the modern literature, dedicated to the study of the action of pro-thinking harmful substances on the organ of vision, certain attention is paid to the picture of the fundus. At the same time, the authors point to an enlarged caliber of retinal blood vessels. Such information is clearly insufficient. However, this circumstance cannot be blamed on the authors, since a more thorough examination, in particular, the use of calibrometers in mass examinations of the eye fundus for the purpose of diagnosing vessel damage, is unavailable.

During the examination of 1045 workers of the plant, we noted both signs of weak expansion of retinal vessels and signs of narrowing, especially in people older than 35 years. However, there was no reason to consider these changes as deviations from the norm and to associate them with the influence of chemical production factors.

In addition to the already noted myopic changes, no other deviations were found on the fundus, except for three persons (22, 26 years old and 31 years old) with partial pallor of the optic nerve disc.

During consultation with a neuropathologist, it was established that in two cases there was post-influenza atrophy of the optic nerve, and in one case, the atrophy was associated with an optochiasmatic arachnoiditis that had been transferred in the past.

Thus, the changes in the lens, vitreous body, and fundus revealed in some of the examined patients could not be considered as a consequence of the specific influence of tire production conditions on the organ of vision.

Functional changes. According to our observations, the majority of tire production workers, who are shown corrective glasses, do not wear them. In some cases, this is due to the dustiness of the premises, which leads to contamination of glasses and makes it difficult to perform work. In other cases (for

harmful operations), correction is not used due to the use of safety glasses.

In these conditions, it seems expedient to investigate the uncorrected visual acuity of factory workers.

By surveying the control group of workers, in comparison with those working in various workshops of the tire industry, it was not possible to reveal any influence of harmful chemicals on the visual acuity of the tire plant workers.

As for the state of peripheral vision, concentric narrowing of the field was revealed in almost a third of the workers of the tire factory, in comparison with the control group of people who worked at another enterprise, where the production values of a toxic-chemical nature were absent.

It definitely depended on the level of concentration of chemical ingredients in individual workshops. The establishment of these facts led to the necessity of transferring workers, in particular from the vulcanization and calender workshops, to other spheres of activity, not related to the action of chemical factors.

Changes in the field of vision persisted for 6-7 months, and then its boundaries were restored to normal.

These data allow us to consider that the chemical factors of tire production can have a limited influence on the state of the field of vision, the narrowing of the borders of which, however, has a functional character.

In comparison with the control group, the workers of the tire plant had a decrease in tempo adaptation of a functional character much more often. The fact that the frequency of the decrease in pace adaptation among those working in workshops where the content of chemical ingredients exceeded and did not exceed the MPC was approximately the same indicates that this decrease was associated with the impact of toxic factors common to all production units of the plant.

Based on the data from the literature about the influence of chronic intoxication on the state of ophthalmotonus and the possibility of developing glaucoma as a result of this, we found it expedient to investigate the intraocular pressure in tire factory workers.

Studies have shown that the conditions of tire production do not affect the state of intraocular pressure. However, in two workers aged 47 and 52 years with more than 10 years of work experience, an increase in intraocular pressure was detected, with further diagno-

sis of the initial glaucomatous process in the hospital and taking the patients under dispensary observation. One worker was diagnosed with suspected glaucoma.

Characteristic changes of the iris in the form of destruction of the pigment rim of the pupil and dispersion of pigment were observed in half of the examined workers, mainly in workshops with a high concentration of chemical ingredients. The degree of these changes increased with the increase in work experience. Their clinic is included in the map of toxic damage to the iris under the influence of a complex of chemical substances in tire production.

Changes in the lens, vitreous body and fundus were revealed in some of the examined patients. However, these changes cannot be seen as the result of a specific influence on the conditions of tire production on the organ of vision.

The obtained data allow us to consider that the chemical factors of tire production can have a certain influence on the condition of the field of vision, the narrowing of which, however, has a functional character.

As for ophthalmotonus, it was not possible to establish a negative impact of harmful factors of tire production on its level. Experimental studies. Having established certain clinical facts, naturally, each ophthalmologist strives to make rational conclusions of a therapeutic and especially preventive plan in order to prevent the identified changes. These conclusions should be based on more in-depth studies that reveal the pathogenesis of the detected clinical symptoms.

In the specialized literature, there are no works covering histomicroscopic and histochemical changes in the internal organs and the organ of vision under the influence of chemical hazards of tire production. This served as the basis for conducting special experimental studies. The experiment was conducted on rabbits, and the cages, which were installed in various workshops of the tire plant (preparatory, auto-tube, vulcanization, calender, medical unit of the plant).

Changes in the internal organs of experimental animals were characterized by dystrophic and hemodynamic disorders, the severity of which depended on the duration of exposure to toxic factors. Apparently, in the pathogenesis of the identified deviations, not only the phenomenon of contact exposure to chemical reagents played a role, but also the process of their resorption with subsequent dystrophic

changes in the parenchymatous organs (kidneys, liver).

During systematic and long-term observation of experimental animals, a sharp hyperemia of the conjunctiva of the eyelids and the eyeball was noted. The cornea lost its shine and looked edematous. The sensitivity of the cornea was sharply reduced. Biomicroscopically, changes in the perilimbal network were determined in the form of tortuosity, unevenness of the caliber of the vessels with their ampullar expansion, and isolated point hemorrhages in the perilimbal parts of the conjunctiva. In the lens, opacities of varying sizes were visible under lateral illumination. The fundus revealed dilation of the retinal veins and small point hemorrhages.

The following changes were revealed during the morphological examination. In the conjunctiva, the pronounced proliferation of epithelial cells with the formation of papillae was noted. Lymphoid infiltration was detected in the proper conjunctival tissue (Fig. 46a). The presence of dilated and full-blooded conjunctival vessels was noteworthy (Fig. 46b).

Argyrophilic stromal fibers had the appearance of a fine network of intertwined elements. When studying the qualitative distribution of RNA and DNA, it was found that in the cells of the conjunctival epithelium with pronounced edema and dystrophic changes, DNA gives a weak stain, and RNA is difficult to distinguish.

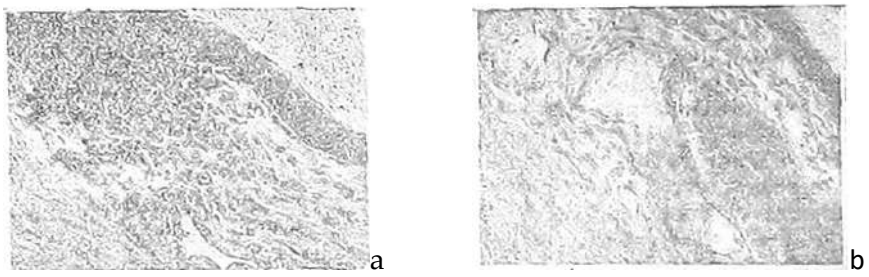

Fig. 46. **Pathohistological changes in the conjunctiva of the eyeball under the influence of harmful factors of tire production (experiment); a - lymphoid infiltration of tissue; b - vasodilation. Hematoxylin and eosin staining, magnification X400**

When staining for glycogen, according to Shabadash, the formation of large agglutinated grains against the background of small

diffusely distributed granules was observed in the conjunctival epithelium. In the proper conjunctival tissue, when stained according to Daniel and Pierce, diffuse accumulation of amino acids was observed. In the altered areas of the proper tissue, as well as around the dilated vessels, in contrast to the control animals, a decrease in the intensity of metachromasia staining was observed.

In the corneal epithelium, glycogen accumulation was noted when stained according to Shabadash.

The angle of the anterior chamber did not present any special changes. The corneo-muscular trabeculae and lacunae between the processes of the iris were well expressed.

Numerous full-blooded vessels were found in the stroma of the iris. Histiocytic stromal cells accumulated mainly near the vessels. The walls of the latter had a structure characteristic of the iris with sharply thickened adhesion. A small accumulation of amino acids was noted around the vessels.

The vessels of the ciliary body were dilated, full-blooded, and sometimes, had a looped appearance, the basal membranes appeared slightly thickened. The epithelial structures of the ciliary body were not changed.

In the choroidea, significant dilation and a plethora of vessels were noted. In some rabbits, there were hemorrhages in the choroid, mainly on the periphery. The blood saturated the entire tissue of the choroidea, causing its pronounced thickening.

In the reaction for nucleic acids, good preservation of DNA was noted in the nuclei of cells of all retinal layers.

The content of nucleic acids (mainly DNA) in the nuclei of epithelial cells was uneven. There was a focal decrease in staining intensity.

Thus, during the pathohistological and histochemical examination of the eyes of experimental animals, significant changes were revealed in the tissues of the conjunctiva and the outer part of the eye. They were expressed in edema and vacuolization of proliferated epithelial cells, lymphoid infiltration of the conjunctival tissue itself, dilation of its vessels, thickening and uneven impregnation of argyrophilic fibers.

Corneal changes were manifested by the ingrowth of individual vessels from the periphery, the disintegration of fragmented argyrophilic fibers, the accumulation of

glycogen and corneal epithelium, and metachromasia. The uveal tract was characterized by dilation and a plethora of vessels, as well as hemorrhages into the choroid. In the retina, in addition to vascular changes, vacuolization of tissues in the nerve fiber layer and pericellular edema of ganglion cells were observed.

It can be considered that changes in the conjunctiva and the outer part of the eyeball are associated with the direct combined effect of factors of eye production, while changes in other structures of the eye are a manifestation of the general influence of these factors on the body of experimental animals.

System of measures to prevent damage to the visual organ in tire production. Analyzing all of the above from the standpoint of the relationship between the presented clinical facts and experimental research data, we can assess the identified changes in some tissue structures of the eye as specific, caused by the action of toxic-chemical factors. In workers in hazardous workshops, changes in the external part of the eye increased with increasing length of service. The clinical picture of the identified symptoms of intoxication, with an increase in the concentration of chemical ingredients in the workplace, was distinguished by a number of features.

Despite the visible inflammatory nature of the process, there was no pain syndrome, which is probably due to the anesthetic effect of hydrocarbon vapors (although the effect of other tire production factors on the cornea cannot be ruled out). In our opinion, this also explains the decrease in corneal sensitivity (in 41.7%), up to its complete anesthesia (in 3.4%).

The presented data give grounds to believe that decreased sensitivity of the cornea is an early and reliable sign of the toxic effects of chemicals on the organ of vision in tire production workers. Biomicroscopy revealed unevenness of the caliber of conjunctival vessels, the presence of aneurysms, newly formed vessels in the limbus area not only with inflammation of the outer part of the eye but also where there was none. In addition, keratosis of the conjunctiva was noted in the area of the eye slits. Biomicroscopy revealed destruction of the pigment border of the pupil and dispersion of pigment over the entire surface of the iris, atrophy of the mesodermal tissue in the form of cracks, round holes. The surface of the iris acquired a dirty brown color. The changes in the lens, vit-

reous body and fundus revealed in a number of cases cannot be linked to the direct action of chemical factors. Isolated cases of cataracts were either congenital (polar cataract) or senile (coronal, nuclear cataract).

In the vitreous body, there was destruction of the stroma. In the fundus, there was both narrowing and dilation of the vessels. No specific changes in the fundus indicating intoxication were found. No decrease in visual acuity depending on professional factors was observed. However, an increase in the frequency of narrowing of the visual field to white and to colors was reliably established. A decrease in dark adaptation in workers in workshops with concentrations of chemical ingredients exceeding and not exceeding the MAC, with a very small difference in the frequency of cases, indicates the impact of toxic factors common to all production units of the plant. Changes in tempo adaptation were unstable. When workers were transferred to areas where the effects of the above factors were absent, light sensitivity indicators were restored to normal.

Only three workers at the tire factory showed increased intraocular pressure (see above), with a diagnosis of glaucomatous processes in two cases.

By comparing the results of histochemical and morphological changes in eye tissues with clinical manifestations of intoxication of the visual organ by tire production products, it is possible to approach an understanding of the pathogenesis of these changes. The resulting basis made it possible to develop a very important problem of preventing toxic-chemical eye damage in tire production.

The system of these measures includes recommendations for improving the industrial process itself from a hygienic standpoint, the working conditions of workers, as well as recommendations for a special ophthalmological profile.

In particular, in order to exclude direct contact of workers with chemicals and the formation of dust from chemical ingredients in the workplace of tire production, it is necessary:

a) mechanize and automate loading and unloading operations in the preparatory shop;

b) weigh out chemical ingredients according to recipes, distribute them among rubber mixers and load them into the apparatus using mechanical methods only;

c) clean synthetic and natural rubber packages from talc before

using them in production in an isolated chamber without access for workers;

d) design and equip exhaust and supply ventilation systems in the preparatory and vulcanization shops in such a way as to eliminate the formation of counter-currents of high-speed air that create swirls of suspended and settled dust in the workplaces and equipment.

Liquid ingredients must be supplied to process equipment only through sealed pipelines. Equipment must not be loaded with reagents, especially strong liquid substances (caustic soda, acids), using improvised containers. This creates conditions for them to splash and cause damage to the skin and eyes of workers.

It is necessary to completely mechanize the preparation of lubricants, adhesives, suspensions, i.e. processes in which there is a possibility of workers being exposed to harmful chemicals.

In workplaces where harmful chemical substances (alkalis, acids) may come into contact with workers, it is necessary to install hydrants for quickly washing these substances off the skin and eyes, as well as first aid kits with a set of medications for providing first aid to the victim. It is necessary to oblige workers who have contact with harmful chemical substances during the production process to use personal protective equipment (glasses).

In the preparatory and calender shops, the lighting of workplaces should be brought up to sanitary standards.

Medical workers of the health center and the medical and sanitary part of the enterprise are required to carry out daily monitoring of the condition of workplaces, compliance with safety rules when using harmful chemicals, and train those responsible for sanitary posts in methods of first aid to victims.

Persons with eye diseases must be placed under medical observation.

Periodic examinations of workers in workshops with increased levels of toxic chemical ingredients should be carried out once every 6 months, and in other workshops - once every 12 months.

To prevent the development of persistent eye damage, it is necessary to carry out timely transfer of workers from the area with increased concentrations of chemical ingredients to other divisions of the tire plant.

In summer, it is necessary to ensure an uninterrupted supply of carbonated salted water to workers. To improve working condi-

tions, it is necessary to rationally place equipment and implement measures to maintain a normal microclimate in the workplace, but limit noise and vibration.

It is necessary to systematically conduct lectures and talks with workers on the prevention of eye damage in production and classes with the plant's mid-level medical personnel on topics related to the prevention and first aid for possible occupational eye damage. It should be noted that all the above-proposed preventive recommendations in tire production have been fully implemented.

Chapter 6

TOXIC-CHEMICAL DAMAGE TO THE ORGAN OF VISION IN IODINE PRODUCTION

Thanks to well-thought-out preventive measures carried out in our country, occupational eye diseases have significantly decreased. However, despite this, the problem of occupational pathology cannot be considered completely solved. At present, the study of the chronic effect on the body, including the organ of vision, of low iodine concentrations in various production conditions is acquiring great importance.

It should be said that the nature of occupational lesions of the organ of vision in workers in iodine production has not yet been sufficiently studied.

At present, we do not have fundamental studies indicating the possibility of damage to the organs and systems of the worker's body during the process of iodine preparation. However, some aspects of the effect of iodine on workers in this production have been studied.

The main harmful substance at the hearth plant is, naturally, iodine vapors, but along with this, air pollution by sulfuric acid, alkali, and sulfur dioxide vapors occurs to a significant extent.

Hygienists note that workers become accustomed to iodine when its content in the air of workrooms is less than 0.01 mg/m^3. When this concentration is exceeded, adaptation to iodine is not observed even among workers with a long work experience (more than 25 years).

Persons working in conditions of increased concentrations of iodine vapors showed disturbances in basic metabolism, functional changes in the myocardium in the form of sinus bradycardia and sinus tachycardia, as well as a decrease in blood pressure.

Various changes in the eyes are described. In particular, under the influence of iodine and chlorine vapors, lacrimation, conjunctival irritation, and changes in refraction are observed. However, the issue of the effect of iodine on the visual organ has received almost no coverage in the ophthalmological literature in a comprehensive approach. There are no data on changes in the eyes during long-term contact with this industrial poison, and the morphological and histochemical aspects of the problem have not been studied. From the above, it becomes obvious how important and relevant are the tasks associated with professional hazards that arise in persons engaged in iodine production. Knowledge of this issue can help to clarify some aspects of the mechanism of the effect of iodine vapors on the visual organ, which in turn is of great importance in developing preventive measures.

As has already been said above, in relation to tire production, the role of an ophthalmologist is not only to state the fact of eye disease associated with the influence of occupational hazards. He must know the production process itself, be familiar with the sanitary and hygienic working conditions, the concentration of chemical ingredients in various workshops. All this helps to understand the pathogenesis of emerging eye diseases and outline rational measures for their prevention. Sanitary and hygienic characteristics of working conditions. Occupational hazards. As is known, iodine is widely used in various fields of medicine, in some areas of chemistry as a raw material for the production of synthetic materials and reagents, in agriculture as a means of stimulating growth and increasing the yield of agricultural crops.

In our country, much attention is paid to the production of iodine, new code factories are being built and old ones are being reconstructed. Much attention is paid to equipping them with more modern technology. Working conditions at these factories are also being improved. The main raw material for obtaining iodine is iodine-containing groundwater extracted together with oil during the operation of oil wells. Iodine-containing oilfield water, purified at the plant from sludge, oil and other impurities using centrifugal pumps, enters pressure tanks for iodine oxidation. It is acidified with technical sulfuric acid and oxidized with sodium nitrite.

After this, the water flows by gravity into the adsorbers onto ac-

tivated carbon previously poured into the apparatus for the separation of free iodine. Carbon with iodine adsorbed on it, i.e. iodine carbon, is transferred to desorbers, where the iodine is washed off the carbon using caustic soda and live steam. The iodine-saturated solution is collected from the desorbers in special collectors, from where it is pumped through carbon and clay filters into a crystallizer, where iodine is separated as crystalline sediment using sodium nitrite. The sediment is washed with water, pressed into tiles and sent for purification from organic and mineral impurities by distillation in sublimators. Then this iodine is unloaded from the apparatus and packed in glass containers. Thus, the production process of obtaining iodine is associated with the use of a number of chemicals, including aggressive and potent ones: sulfuric and hydrochloric acids, caustic soda and sodium nitrite. In addition, there are other unfavorable factors at the iodine plant: indoor air pollution by steam and gas emissions of the above chemicals and coal dust, temperature factors, manual labor with the use of physical exertion. All these elements, but in different combinations, are found in all production areas of the iodine plant. It should be noted that the continuity of the technological process determines the constancy of these factors. The air is especially polluted by iodine vapors, acids and alkalis.

The process of iodine production goes through several stages. First of all, iodine-containing water is pumped out of oil wells.

In oil fields, workers perform various jobs associated with physical exertion and are exposed to hydrocarbons. When performing repair work, workers come into contact with liquid oil and its vapors. After cleaning and settling, oil field water is pumped from the pool to the mixers, where the oxidation process takes place.

In the iodide oxidation section, operators prepare acid solutions and pour them into acid measuring tanks. Here, contact with sulfuric acid and sodium nitrite is inevitable. Preparation of working solutions and pumping them into measuring tanks create conditions for the evaporation of acids and their contamination of the air of a given production area in a concentration exceeding the maximum permissible level. The discharge of acid from the measuring tank into open mixers promotes its evaporation and pollution of the air of workplaces. The meteorological conditions at this production site

are almost the same as at the oilfield water preparation site.

Oxidation of iodine-containing oilfield water is carried out with sulfuric acid to isolate molecular iodine iodides, which are then pumped under pressure into adsorbers.

In the adsorption section, the apparatus is filled with activated carbon and filled with water. Filling dry carbon into the adsorbers is accompanied by dust emission. The process of adsorption and unloading of iodine coal from open apparatuses creates conditions for iodine evaporation and air pollution. Loaders and adsorber operators work in the adsorption section. The work of both groups of workers takes place in conditions of air pollution with iodine, dust and the presence of unfavorable meteorological factors. The iodine coal formed in the adsorbers is unloaded into desorbers.

In the desorption shop, iodine adsorbed on activated carbon is washed off with caustic soda and live steam in a special container - a desorber. Iodine, which is washed off the coal, forms a mother liquor.

The technical conditions provide for the process to be carried out with the hatches closed, but control over the quality and completeness of the flush, regulation of the process mode, supply of the reagent and steam, and sampling are carried out with the participation of the operator and with the tank hatch open.

The iodine and alkali vapors released in this process pollute the air. The heat and water vapor emitted from the apparatus increase the humidity and temperature of the room. This also has an adverse effect on the well-being of the workers.

The iodine-saturated mother solution is collected in iodine collectors, filtered and pumped into a crystallizer. Here, iodine crystallizes using sodium nitrite or, more often, potassium chlorate.

As a result, crystalline iodine precipitates and evaporates intensely into the air through the hatches of the apparatus, which manifests itself as a violet cloud spreading throughout the entire compartment. This contributes to an increase in the concentration of iodine in the air. Crystallization of iodine is accompanied by constant mixing of the mother liquor, and the sediment is washed out from the bottom of the apparatus using a water jet. In this case, there is a risk of exposure of iodine crystals, splashes of mother liquor and iodine vapors to exposed parts of the skin and eyes.

Subsequently, iodine is pressed. For this, crystalline iodine is washed from sludge, inorganic and organic impurities. Iodine is washed out on the screen of the filter with a water jet. Then the iodine is collected in metal forms and transferred to a press to squeeze it out of the water. Pressing the iodine promotes its significant evaporation into the air. Therefore, in the area of pressing crystalline iodine and in the area of its crystallization, the operators work in gas masks. This area is considered difficult, since the work is associated with the effects of iodine vapors, requires physical effort, great attention and nervous tension.

Subsequently, the technical iodine squeezed out of water is purified from organic and mineral impurities in sublimation apparatuses by the sublimation method. The sublimation and unloading processes are often accompanied by an intensive release of iodine into the air. In this area, thermal radiation also has a certain effect, which contributes to an even more intensive release of iodine vapor into the air.

After these procedures, the finished product — crystalline iodine — is packaged. The premises of this section are undoubtedly contaminated with iodine vapors and dust. The concentration of iodine here is quite high.

The presence of crystalline iodine in the air of the room can contribute to its entry into the respiratory tract and eyes. In view of this, all work in this section is carried out in gas masks.

In the reactive coal section, the spent coal after two or three desorptions is dumped into a dump, and then transferred to the reactivity section, where it is calcined in special furnaces at a high temperature. Before this, the coal is sifted through a sieve, then poured into the furnace hopper, which causes dustiness in the air. In this case, the service personnel can be exposed not only to the dust factor but also to thermal radiation.

The above indicates that working conditions at the code plant are associated with the use of a number of chemical reagents (sulfuric acid, chlorine, alkalis, sulfur dioxide), which are necessary for obtaining iodine. The process of producing iodine from oilfield waters is associated with the possibility of air pollution with iodine vapors, steam gas, and chemical emissions. Moreover, high concentrations of iodine are found in all shops. Work at the hearth plant is also associated with physical stress, and in a number of areas, with exposure to a thermal

factor. Therefore, it is of great practical interest to study the effect of iodine vapors on the visual organ of workers in various production areas of the hearth plant, and to identify early and developing signs of intoxication.

The ophthalmological service at the plant follows standard organizational procedures, with no notable distinguishing features. The eye room of the medical unit is equipped in accordance with the existing equipment list (see information applicable to the eye room of the medical unit of the tire production), which allows for a complete ophthalmological examination of the eye and its adnexa, and a study of the functions of the visual organ.

During observation of the condition of the organ of vision in 198 workers of the hearth plant, a number of specific clinical features were revealed. They consisted of the fact that in some cases, phenomena of edema of the eyelids and conjunctiva spontaneously developed, which spontaneously disappeared after a few days without the use of any treatment. In all cases of detected eye damage, sharp changes in blood vessels were noted, which manifested themselves in their expansion and unevenness of caliber.

More than half of the examined workers of the main workshops of the Hearth Production complained of itching in the eyes, photophobia, and lacrimation, reddening of the eyelids and conjunctiva, and a feeling of a foreign body behind the eyelids. During the examination, a very peculiar picture was observed. During periods of remission, thickening of the edges of the eyelids, hyperemia, and sparse growth of eyelashes with scales at the base were noted.

The anterior and especially the posterior edge of the intermarginal space of the eyelids were smoothed. In the outer corners of the eyelids, as a rule, there were cracks and areas of skin maceration (Fig. 47).

The conjunctiva of the eyelids was cloudy and swollen. The pattern of the meibomian glands was not visible. In the area of the upper and lower transitional folds, the conjunctiva appeared thickened, with separate areas of edema.

The conjunctiva of the sclera was cloudy. In the area of the palpebral fissure, it was often degeneratively changed; increased vascularization was noted at the limbus, especially from above. On the cornea, punctate or rather significant erosions were often determined, stained with fluorescein (Fig. 48).

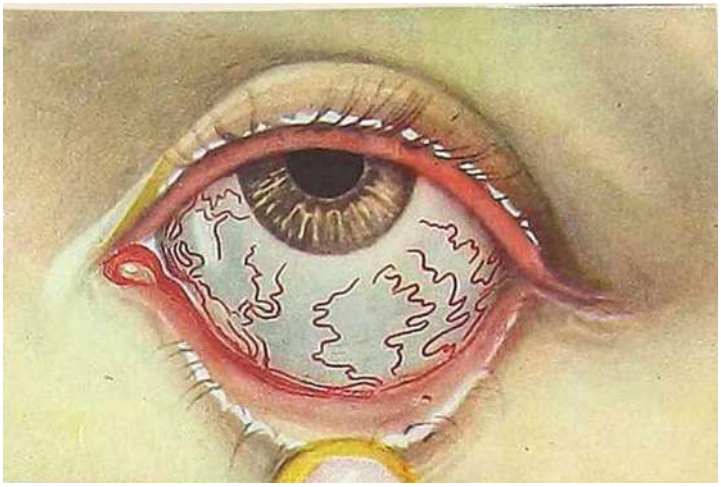

Fig. 47. **Toxicochemical blepharoconjunctivitis (period of remission)**

Most often, these erosions were located on the paracentral areas of the cornea. Sometimes, epithelial defects had a triangular shape, located within the eye slit.

During examination in the period of edema, the eyelids were sharply thickened and hyperemic. The conjunctiva of the transitional folds protruded in the form of ridges, moderate chemosis of the conjunctiva of the sclera was noted. Small hemorrhages were found over the entire surface of the conjunctiva (Fig. 49).

As a rule, the phenomenon of edema, as stated above spontaneously disappeared within one or two days. It was not possible to note the connection between the development of edema and the direct effect of iodine vapor on the eye in all cases.

The described changes in the adnexa and the anterior part of the eye took place in iodine production in 51.01% of cases. Mathematical analysis of the frequency of lesions of the anterior segment of the eye showed high reliability of differences both between individuals who had constant and periodic contact with iodine, and between the control group and workers of the plant departments directly involved in the iodine production process.

Of particular importance in the characterization of the changes identified is the biomicroscopy method, which made it possible to detail the symptoms detected.

Biomicroscopic examination of the eyes was complicated by severe photophobia, which in some cases led to the need for the instillation of a 0.5% solution of dicaine.

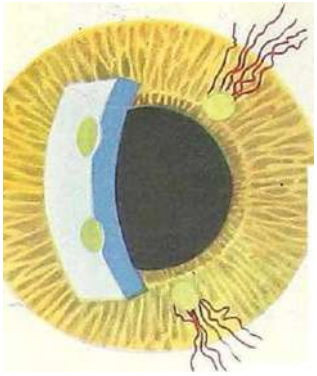

Fig. 48. **Exogenous keratitisy**

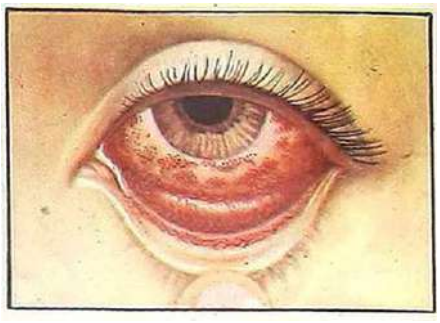

Fig. 49. **Toxicochemical blepharoconjunctivitis (period exacerbation)**

When examining the eyelids, attention was drawn to the fact that their surface was shiny and had a "greasy" appearance. In the intermarginal space at the base of the eyelashes, the enlarged openings of the sebaceous glands protruded.

It was quite specific that the branches of blood vessels from the skin side crossed over to the smoothed anterior edge of the niter-marginal space and branched out in it.

The conjunctiva of the eyelids, transitional folds and sclera was cloudy, thickened and loose. In the area of transitional folds, hemorrhages in the form of smears were often noted. Biomicroscopic examination in a thin optical section attracted attention to the pronounced unevenness of the epithelial layer of the conjunctiva. The most significant changes were in the blood vessels of the conjunctiva. When examined in red-free light, the number of vessels in the conjunctiva of the eyelids and sclera, especially in the area of the palpebral fissure, was increased. As a rule, the conjunctival vessels were dilated, had an uneven caliber, were tortuous, and were located so superficially that the epithelium above them was slightly raised. Changes in the deep vessels were expressed to a lesser degree. On the conjunctiva of the upper and lower eyelids in the area of the cartilages, along with an increase in the number of vertical branches, the development of vessels with a horizontal direction was observed.

In the conjunctiva of the sclera, loop-shaped, large and medium-caliber vessels formed a rough network, especially pronounced in the perilimbal region. Quite often, one could see how the vessels in the area of the upper limbus formed loops that passed subepithelially into the transparent cornea 2-3 mm from the limbus and tangentially to it.

In some cases, these vessels did not divide into branches, but in most cases, their branching and development of anastomoses were observed. Along with the above changes, workers with over 5 years of work experience had yellowish areas with unclear contours in the conjunctiva of the sclera 1.5–2 mm above the limbus. The epithelium above them was edematous. With sufficient magnification of the slit lamp microscope, lumps of pigment with sharp iodine-colored edges resembling iodine crystals were determined in the center of the spots (Fig. 50).

In workers who had contact with iodine vapor, the upper sections of the limbus were dilated. The normal radial striation of the limbus was absent. The main features during examination were: powerful superficial vascularization of the limbus, decreased transparency and acquisition of a brownish tint. Capillary loops in the form of elongated and short "forks" in the limbus area were located mainly superficially.

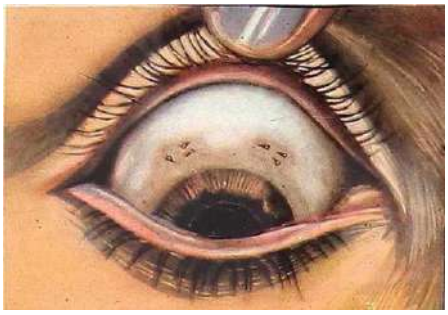

Fig. 50. **Iodine deposition in the conjunctiva of the eyeball**

In persons working in the iodine sublimation and adsorption workshops, changes similar to those described were present not only in the region of the upper limbus but extended to its lateral and lower sections. In accordance with the changes in the limbus, areas of epithelial edema were noted in the upper segment of the cornea. This was manifested in the loss of the mirror-like surface of the cornea and the presence of small vacuoles of bizarre shape. At the same time, erosions were determined, clearly visible after staining the cornea with fluorescein.

Bowman's membrane in the area of edematous epithelium was, as a rule, thickened, sometimes folds of this membrane were noted.

In the superficial layers of the cornea, small gray infiltrates were visible in the optical section. In the middle and deep layers of the stroma, inflammatory and destructive changes were not noted, except for the presence of aqueous cracks indicating the spread of edematous fluid here.

When examining with high magnification, in isolated cases, areas of edema of the corneal endothelium were observed, the cells of which in transmitted light had the appearance of rounded formations. Sometimes, grains of sprayed pigment were found on the back surface of the cornea.

It should be noted that with constant exposure to iodine vapors, sometimes in increased concentrations, extensive corneal erosions of triangular and discoid shape (see above) were revealed to be located paracentrally during biomicroscopy. Naturally, these changes could also be detected using the lateral focal illumination method. During a repeat examination after 24 hours, complete epithelialization of the erosions was noted, and delicate cloud-like opacities remained at the site of the lesion for several days. The nature of the noted corneal changes indicates a superficial localization of the process, closely associated with conjunctival damage.

Apparently, the development of such exogenous keratitis was based on the action of iodine vapors, possibly combined with intoxication with vapors of sulfur compounds, nitrogen oxides and alkalis.

As for corneal sensitivity, its decrease and even complete absence (corneal anesthesia) in iodine production is detected in 52.5% of workers. In workers whose activities were associated with a constant presence in an atmosphere with iodine vapor content exceeding the MAC, impaired corneal sensitivity was observed in 71.5%.

The detected decrease in corneal sensitivity was persistent, and repeated examinations yielded results close to the data of the initial examination.

The decrease in corneal sensitivity in workers in the workshops who had periodic contact with iodine vapors was less significant. In repeated studies, sensitivity improved, although it did not reach the norm. This improvement indicated weaker intoxication of workers in the group of periodic contact with iodine vapors.

In plant workers who, due to the nature of their work, did not have direct exposure to iodine va-

pors, a decrease in corneal sensitivity was noted in 11.6%.

The fact of decreased corneal sensitivity depending on the length of service at the iodine plant turned out to be quite reliable. Thus, among workers with one year of service, decreased sensitivity was noted in approximately half of all cases, and with 2-5 years of service, in two-thirds of workers. With more than 5 years of service in iodine production, there was almost always a decrease in corneal sensitivity. The absence of changes in corneal sensitivity in these workers was extremely rare.

It can be assumed that working at the plant for 5 years or more, due to chronic iodine vapor intoxication, constantly leads to a violation of corneal sensitivity.

Thus, the workers of the hearth plant were found to have a specific symptom complex in the form of chronic edema of the eyelids, conjunctiva and cornea, the appearance of corneal erosion, increased superficial vascular network of the anterior segment of the eye, the formation of code pigmentation, apparently with subconjunctival deposits of iodine crystals on the upper limbus, as well as decreased corneal sensitivity. The severity of these symptoms is directly dependent on the degree of iodine vapor intoxication in the work areas and the length of service at the plant.

When examining workers at an iodine plant, great attention should be paid to the iris, determining the color, pattern, and relief of its stroma and looking for specific symptoms, which will be discussed below. Based on our experience, we should recommend examining the pupils especially carefully, since workers at the iodine plant have a sluggish reaction to light, and in some cases, a state of mydriasis. All this indicates that iodine vapors, apparently exerting a general toxic effect, affect the hypothalamic sympathetic center of the pupil, which causes its dilation.

An examination of the iris, which was carried out according to generally accepted methods, must necessarily include an element of biomicroscopy. Among the existing examination methods, preference should be given to examining the structures of the iris in a sliding beam.

In workers exposed to both constant and periodic iodine vapors, sometimes in elevated concentrations, bilateral specific changes were detected in half of the cases.

When examining the mesodermal layers, especially with the

use of a sliding beam (both in the pupillary and ciliary belts), superficial iodine-colored plaques were found. These plaques had the appearance of spots of various shapes and sizes, ranging from a point to 1-2 mm in diameter. Their boundaries were unclear. The central part of such foci looked denser. Biomicroscopy with high magnification showed that the spots consisted of small granules, which, under oscillatory illumination, gave point reflexes, indicating their crystalline nature. Taking into account the color of the deposits and the characteristic features of light reflection, it was possible to identify with great certainty the indicated formations with deposits of crystalline iodine.

No symptoms of inflammation of the iris were observed. The aqueous humor was optically neutral. We also failed to note the pronounced dystrophy of the ectodermal leaf of the iris that was so often observed in tire factory workers. Significant depigmentation of the pupillary border was not detected in any case, but moderate pigment dispersion in the form of small grains on the surface of the iris was noted, and in some cases on the posterior surface of the cornea. Dystrophy of the mesodermal leaf was more pronounced, which was expressed mainly in the region of the ciliary belt, by the formation of cracks and disruption of the usual pattern of the iris.

As a rule, the indicated changes were observed in individuals who had intensive contact with iodine vapors and had more than 5 years of industrial experience. The following observations can be cited as an illustration of this.

***Worker L.*, 47 years old, iodine extraction operator. Work experience 21 years. The edges of the eyelids of both eyes are edematous. The conjunctiva is swollen, cloudy. The pattern of conjunctival vessels is enhanced. The limbal area is widened, grayish-yellowish in color. There is subepithelial ingrowth of conjunctival vessels into the cornea. Biomicroscopy shows several dots of black pigment on the posterior surface of the cornea. The pigment border of the pupil is preserved. Atrophic zones are found in both the pupillary and ciliary belts of the iris. Dark areas resembling iodine spots are scattered over the entire surface of the iris (Fig. 51).**

***Employee A.*, 36 years old, laboratory manager. 10 years of experience in the chemical industry, 1.5 years at a hearth plant. Pronounced edema of the eyelids and conjunctiva of both eyes. No changes in the limbus or cornea. The anterior chamber is of**

normal depth. The iris pattern is clear, the relief is not disturbed. Iodine is sprayed over the entire surface of the iris in the form of small dark-brown, crystalline dots.

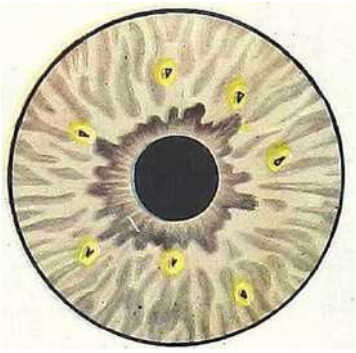

Fig. 51. **Iodine deposition on the iris of a 47-year-old female worker (Work experience as an iodine extraction operator – 21 years)**

The above observations prove that changes in the form of deposits of peculiar iodine spots are determined on the iris, especially when using the biomicroscopic method of examination. The indicated iodine deposits are a specific symptom of intoxication of the eye with iodine vapors, which is definitely connected with the conditions of iodine production and the length of service at the plant.

When examining the lens, vitreous body and fundus, changes were found in 10.1%. The peculiarity of the symptoms identified and their different frequency among workers in different divisions of the plant were noteworthy. It has long been known that cataracts develop under the influence of chronic industrial iodine intoxication. Opacities of the lens have also been described with constant contact with trinitrotoluene, chemical products of aluminum production. In several workers of the iodine plant, we observed changes in the lens during biomicroscopy, which had the following features. Under the posterior capsule, mainly in the posterior cortical layers of the lens, a zone of small, grayish smoky opacities of varying sizes was noted, merging with each other in places. These opacities were most often located in the paracentral areas of the lens. In the optical section, they had the appearance of layered and crumbly elements.

When examined in a mirror field, a colored iridescence was noted in the region of the posterior pole of the lens.

Dynamic observation over 5-7 years allowed us to note the slow spread of these opacities both to the center and to the equator of the lens.

The absence of any changes in the vascular tract, retina, normal intraocular pressure and the above-described picture of lens damage allowed us to classify this type of

cataract as complicated, associated with general intoxication of the body.

Two workers with bilateral complicated cataracts had constant contact with high concentrations of iodine.

Of them, one woman, 32 years old, had worked in the iodine sublimation shop for 7.5 years. The second was a man, 35 years old, who had worked in the technical iodine shop for 12 years.

Among our other two patients, there was a woman over 30 years old, who had worked at the raw material base for 10 years, and the second was a woman, 35 years old, an employee of the plant laboratory, with 10 years of work experience. Along with the action of iodine vapors, they were exposed to intoxication with nitrogen oxides, sulfates, hydrogen sulfide, sulfuric and hydrochloric acids. It was impossible to exclude the influence of these ingredients on the formation of cataracts.

Some workers were found to have unilateral gross changes in the vitreous body. All these individuals complained of a fog before their eyes. Biomicroscopy revealed liquefaction of the intravitreal mass, formation of coarse membranes that moved during examination, and golden-colored inclusions. Given the nature of the biomicroscopic picture, it was impossible to exclude a connection between the noted opacities and hemorrhages into the vitreous body. During observation over three years, gradual resorption of the opacities was noted.

The influence of iodine production factors on the condition of the vitreous body can be judged from the fact that all four workers had constant contact with elevated concentrations of iodine (iodine sublimation shop, technical iodine, raw material base), with 10-12 years of work experience at the enterprise.

In 4 people complaining of decreased vision and a "net" before the eyes, small yellowish foci with unclear boundaries were found by ophthalmoscopy in the area of the macula lutea, with a deposit of a brownish pigment in the center of each of them, which was similar in color to iodine. In 2 of these 4 people, inclusions of the same pigment were observed between the foci. No pronounced changes in the vessels in the macular area were noted. When examining with a campimeter, relative central scotoma was determined in all 4.

It should be noted that such specific changes in the fundus were detected only in people who had

constant contact with increased concentrations of iodine ions, with a work experience of more than 5 years.

Among the workers in the control group, no changes in the lens, vitreous body, or fundus described above were noted.

The information provided gives grounds to believe that the workers at the iodine plant have a variety of lesions of the posterior part of the eye in the form of complicated cataracts, opacities of the vitreous body, retinal angiopathy, and macular dystrophy, which to a certain extent may be associated with the effects of elevated concentrations of iodine vapor. Functional changes. Determination of visual acuity is known to be one of the main ophthalmological tests that allow us to judge the state of the visual analyzer.

Of course, the change in this indicator can only be interpreted taking into account the process that causes the decrease in visual acuity. Therefore, when checking visual acuity using Sivtsev's tables, we took into account only those cases where its decrease was not associated with the refractive factor, and with optical correction, the vision did not improve. Visual acuity equal to 1.0 was taken as the norm.

When examining 49 workers whose contact with iodine vapors was constant, a decrease in corrected visual acuity was noted in 27 patients.

In 3 patients, the decreased vision was associated with the development of pterygium, in 8 - with corneal opacity, in 3 - with the development of complicated cataracts, in 2 - with vitreous opacity, in 4 - with macular dystrophy, in 7 - apparently with the development of retinal angiopathy.

Of the 80 workers whose contact with iodine vapors was periodic, a unilateral decrease in corrected visual acuity was detected in 13 people. The causes of decreased visual acuity were: in 2 people - pterygium, in 5 - corneal opacity, in 2 - complicated cataract, in 2 - vitreous opacity. In 2 people, we were unable to associate decreased visual acuity with any organic process in the eye.

In the control group of 69 people, the decrease in visual acuity in five cases was associated with refractive amblyopia. As can be seen, the relative number of workers who showed a decrease in corrected visual acuity depends on the working conditions.

Among the persons who worked in semi-closed premises and were exposed to iodine vapors,

as well as nitrogen oxides, sulfuric acid and alkalis throughout the working time, visual acuity was reduced in 55.1%; among workers who had periodic contact with iodine vapors - in 16.2% and in the control group - in 7.2%. A test of the significance of these differences using the Pearson criterion showed a statistically significant relationship between working conditions and a decrease in visual acuity.

From this, we can make a reasoned conclusion that a decrease in visual acuity is definitely associated with intoxication of plant workers with iodine vapors.

In accordance with the program, the visual field of all workers at the hearth plant was examined for white and chromatic colors. Of the workers in the group that had constant contact with iodine vapor, the visual field boundaries were determined for 41 patients. Narrowing of the visual field boundaries for white, sometimes within 20-25°, was detected in 14 patients, i.e., in 34.1% of cases.

When determining the visual field with colored objects, the most significant narrowing of the boundaries was detected for red. There were cases of distortion of the visual field boundaries for colors, consisting of the fact that the boundaries for red were narrower than for green.

Among the examined patients, 7 had retinal agnopathy, 4 patients had macular dystrophy, and 2 had a glaucomatous process.

It should be noted that 13 of the 14 workers with visual field narrowing had more than 10 years of work experience in production. This indicates the possible influence of iodine vapor intoxication on the state of the visual field boundaries in workers in this group.

Of the workers who had periodic contact with iodine vapor, the visual field was examined in 75 people. Narrowing of the visual field was detected in 12 workers, i.e. 16.0%.

At the same time, relatively more often than in the first group, concentric narrowing for white color up to 20-25° with simultaneous narrowing for colors, especially for red, was encountered. In the presence of narrowing of the visual field, opacities of the vitreous body were detected in 2 people, glaucoma was diagnosed in 1. In the remaining 9 people, no deviations from the norm in the condition of the eyes were detected.

The narrowing of the visual field in these individuals could be explained by the influence of gen-

eral intoxication associated with industrial working conditions. This is also indicated by the fact that in 10 workers the period of work in production was six, ten or more years.

Of the 69 patients in the control group, a narrowing of the field of vision for white within 10-15° was noted only in 2, accounting workers. No pathology was noted in the fundus.

Thus, the number of people with a narrowing of the field of vision definitely depended on the working conditions. In workshops with constant intoxication with iodine vapors, a violation of the boundaries of the field of vision was noted in 34.1%; in workshops where intoxication was periodic - in 16.0%, in patients in the control group - in 2.9%.

The data presented give grounds to believe that the narrowing of the field of vision is a consequence of intoxication of the body with chemical factors of code production, and primarily with iodine vapors.

Changes in light sensitivity are one of the most subtle indicators of the state of the central nervous system and the organ of vision. In chemical industries, disorders of tempo adaptation associated with general intoxication of the body with chemicals are very often noted.

We conducted studies of tempo adaptation on the Kravkov-Vishnevsky device in 198 workers of the iodine plant.

In the workers of the divisions included in the group where iodine vapors acted on the organism during the entire working day, the time of tempo adaptation exceeding 50 seconds under the conditions of conducting repeated 3-4 studies was revealed in 27 patients. In 17 of these 27 patients, we were able to obtain a curve of hourly tempo adaptation on the ADM adaptometer. In 7 workers who worked in the iodine sublimation and iodine crystallization shops, a violation of light sensitivity was revealed, and the readings of these people were outside the normal zone. In the remaining 10 people, the decrease in tempo adaptation was expressed less significantly and corresponded to the level of the lower limit of the norm. These results indicate a significant violation of dark adaptation in the workers of the group that was exposed to iodine during the entire work shift.

Of the 80 individuals who had periodic contact with iodine vapor, changes in the state of dark adaptation on the Kravkov-Vishnevsky

device were noted in 33 workers. As with the individuals in the previous group, the prolongation of the dark adaptation time was persistent.

When studying the hourly dark adaptation curve on the ADM adaptometer in 15 people who had impaired light sensitivity, it was found that the curve level in 9 workers was below the norm and in 6 people it corresponded to the lower limit of the norm. These data indicate significant impairment of dark adaptation.

In the control group, among 69 people, persistent impairment of dark adaptation on the Kravkov-Vishnevsky device was determined only in 2 people. Among them, one employee, 47 years old, was an accountant, and the second, 45 years old, worked in the plant's medical center. The condition of their visual organs was within normal limits. When questioned, they denied contact with the harmful substances of chemical production, but it was impossible to completely exclude the effect of toxic factors: both workers were periodically in the atmosphere of the plant's shops before the examination.

Thus, the number of persons with impaired light sensitivity in the group of workers who had constant contact with iodine was 55.1%, in the group of workers periodically exposed to iodine intoxication - 41.2% and in the control group - 2.9%. Among all 198 examined plant workers, impaired dark adaptation was noted in 62 persons, i.e. 31.3%. The change in light sensitivity in a third of the plant workers, which was of a persistent nature, indicates a significant impact of industrial intoxication on the body of the workers of the hearth plant.

Intraocular pressure was measured once a year in 169 workers of the hearth plant for 3 years. In addition, an ophthalmological examination was conducted to identify clinical signs of glaucoma. Persons with suspected glaucoma were under dispensary observation.

Among the 49 workers who were constantly exposed to elevated iodine concentrations, intraocular pressure disorders were detected in 2 people. One of them, a 49-year-old man, worked in the iodine sublimation shop for one year. In one eye, he was found to have an increase in intraocular pressure to 28 mm Hg. After a long examination, this worker was diagnosed with an initial glaucomatous process. The second was a 44-year-old woman who had worked in the iodine crystallization shop for 15 years. She had an increase in intra-

ocular pressure in the right eye to 29 mm Hg and in the left to 31 mm Hg. In a hospital setting, she was diagnosed with initially stabilized glaucoma. In both cases, we had no basis to establish a relationship between the development of glaucoma and the effects of industrial chemical hazards.

Among 80 individuals who periodically came into contact with iodine production products, one worker, 44 years old, with seventeen years of experience working at the raw material base, was diagnosed with early glaucoma in both eyes. During the three-year observation of 69 workers in the control group, none of them showed an increase in intraocular pressure.

It should be noted that, despite the fact that the intraocular pressure of all those examined did not exceed the normal range, the average value of it in 49 individuals who had constant contact with iodine vapors was higher than in the rest of the plant workers and amounted to 19.7+0.09 mm Hg.

In workers who periodically came into contact with iodine vapors and in individuals in the control group, the average level of intraocular pressure was 18.3 ±0.06 mm Hg.

Experimental studies. All of the above served as a reason for special studies using histomicroscopic and histochemical analysis methods, the main purpose of which was to identify possible changes in the internal organs and tissues of the eye during chronic iodine intoxication in order to verify and explain the obtained clinical data, as well as to explain some aspects of the pathogenesis of the identified changes.

To solve the tasks set, chronic experiments were conducted on rabbits, which were placed in special lattice cages and left in natural conditions of various working rooms of the hearth plant. Observation of the experimental animals for several months revealed the following clinical manifestations of intoxication in iodine production: hyperemia and thickening of the edges of the eyelids, thinning of the eyelashes, hyperemia of the conjunctiva of the eyelids and the eyeball, especially pronounced in the area of the transitional folds and the inner corner of the eye.

Along with this, the presence of iodine deposits in the form of a narrow thin border along the edge of the eyelids attracted attention. Iodine spots were often observed on the third eyelid as well.

In most observations, eroded areas of varying shape, size and location were found on the cornea. In a number of cases, changes were

also observed in the lens. For example, in two rabbits, the opacity of the lens was observed in the form of individual dots and gray islands. In a number of rabbits, significant dilation of the retinal vessels was detected during examination.

Morphologically, most animals showed proliferation of epithelial cells, edema, and cellular infiltration of the stroma in the conjunctiva with a large number of different-sized, dilated, injected vessels. Some of the vessels contained homogeneous protein exudate. The endothelium of the vessels was swollen, peeling in places, and the stromal tissue was edematous. Small-point hemorrhages and homogeneous masses of exudate were visible between the connective tissue fibers.

When staining for argyrophilic fibers, argyrophilic granularity of various sizes and shapes, sometimes coarse, was found in the epithelial cells of the conjunctiva; in most cases, compaction of argyrophilic fibers was noted in the stroma. The argyrophilic membrane of the vessels is loosened, smoothed, and torn in places.

In these same cases, a large amount of DNA was detected both in proliferating epithelial cells and in stromal cells, and cytoplasmic RNA was detected in the form of granules of varying sizes and weak staining.

Along with this, there was a violation of the distribution and concentration of glycogen and ascorbic acid.

In the cornea, the epithelial cells were unevenly thinned. Swelling and vacuolization of their cytoplasm were often observed. In the basal cells, there was perinuclear edema. Bowman's membrane was not expressed. In the limbus region, newly formed vessels were detected, often sharply dilated, usually with flattened endothelium.

The connective tissue fibers of the corneal stroma were in a state of swelling and edema. Between them, gaps filled with liquid were differentiated.

There were few stromal cells (Fig. 52). Descemet's membrane was swollen. The endothelial layer had several rows in some places.

Histochemical examination revealed a decrease in the amount of glycogen in the areas of edema. The uniformity of distribution of ascorbic acid was disrupted.

The amount of DNA in the nuclei of the epithelial cells of the upper layers of the cornea was reduced to nothing, and RNA was detected only in single cells. In the

cells of the corneal epithelium, the number of argyrophilic grains was reduced; they either weakly or strongly absorbed silver. The tortuosity of the collagen fibers was disrupted; grains and cracks were visible along their course and between them.



Fig. 52. **Pathohistological changes in the cornea under the influence of harmful factors of hearth production (experiment): stromal edema, fluid accumulation between fibrils. Hematoxylin and eosin staining, magnification - x400**

In the iris, vascular reaction and stromal edema predominated in most cases. Attention was drawn to a sharp increase in the number of small vessels, proliferation and swelling of the endothelium, often with perivascular edema.

The pigment epithelium was often found to be loosened with a low melanin content. The connective tissue stroma of the iris was edematous, loosened, and in places weakly infiltrated with lymphocytic and histiocytic cells. The muscle fibers of the sphincter of the pupil were in a state of homogenization.

The amount of RNA was reduced. In some cases, adhesions were noted between the iris, cornea and lens.

Quite polymorphic changes were observed in the ciliary body. Against the background of unevenly expressed edema, a large number of different-sized vessels with thinned, loosened walls lined with swollen endothelium were revealed.

In some cases, round-cell infiltrates simulating cyclitis were found in the stroma. Changes in pigment cells were of interest. Their proliferation and dystrophic phenomena in the form of vacuolization and depigmentation were especially noticeable. Proliferative changes were also noted in the non-pigmented epithelium. There was little DNA in the endothelial cells of the dilated vessels of the ciliary body. The amount of DNA was increased in the nuclei of the non-pigmented epithelium of the ciliary processes, especially in the areas of their proliferation.

The vascular tunic itself was full-blooded and, as a result, sharp-

ly thickened. Swelling, proliferation and exfoliation of the vascular endothelium were noted. In some cases, cellular infiltration of the tissue and foci of hemorrhage between the vascular layers were detected. In the capillary layer, along the course of the dilated vessels, thin, delicate, smooth argyrophilic fibers with varying intensity of silver absorption are visible.

When staining for nucleic acids, RNA was weakly detected in cellular elements compared to DNA. In dystrophically altered endothelial cells, a sharp decrease in RNA was determined histochemically, and the reaction to DNA gave a very pale stain. The changes found in the layers of the retina were of an unequal nature. The outer layers were the most sensitive. Proliferation, vacuolization, and other dystrophic changes in the pigment epithelium were observed.

Particularly pronounced destructive, dystrophic changes were revealed in the layer of rods and cones in the form of loosening, edema, disintegration of elements with the formation of cavities of various shapes and sizes (Fig. 53). In some cases, it was possible to observe an accumulation of structureless protein mass in the layer of rods and cones, as a result of which this layer was thickened. Changes in the layer of ganglion cells were polymorphic. Proliferation, swelling, vacuolization of some cells, pericellular edema were noted. The layer of nerve fibers was unevenly thickened due to edema, the vessels were dilated, full-blooded, their walls were thinned, torn, with foci of hemorrhage. Often the retina was exfoliated due to the exudate accumulated under it.

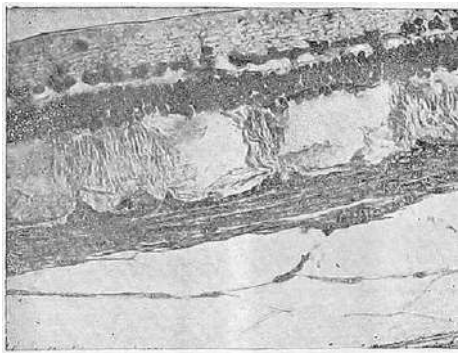

Fig. 53. **Pathohistological changes in the retina under the influence of harmful factors of code production (experiment). Dystrophy of the neuroepithelium. Hematoxylin-eosin staining, magnification - X300**

As for the changes in the optic nerve, dilation and plethora of the central vessels were observed, and sometimes hemorrhages into the nervous tissue occurred. Around the vessels, a picture of perivascular edema was found. Changes in the lens were reduced to edema of its cortex, swelling, with the pres-

ence of granular cloudy masses. A lot of DNA was detected in the proliferating epithelial cells of the lens bag, but RNA was not detected.

Thus, a comprehensive study of the eyes of experimental animals exposed to chemical hazards in a hearth production facility revealed certain changes in all membranes and structures of the eye.

The most pronounced changes were found in the retina, especially in its light-sensitive layer.

Next in frequency of damage are the conjunctiva and cornea (see above).

Histomorphological changes most often concern vascular disorders in the form of an increase in the number of different-sized, sometimes dilated, deformed, newly formed vessels with edema and cellular infiltration around them.

Vascular reactions in the form of an increase in the number of reserve vessels, their dilation, deformation, with the presence of hemorrhages were noted in the vascular tract of a large number of animals. Different degrees of morphological shifts in the argyrophilic membrane of the vessels contributed to the violation of the permeability of the vascular walls. The similarity of changes in the small vessels of the retina, the processes of the ciliary body and the vessels of other parts of the eye is noteworthy. This gives reason to believe that the identified changes are not local in nature, but represent one of the manifestations of damage to the entire animal's organism as a result of chemical intoxication.

Histochemical studies lead to the conclusion that the chemical action of iodine vapors disrupts oxidation-reduction processes in tissues and changes all types of metabolism to one degree or another. Histochemical studies indicate that in the tissues of various membranes of the eye, there is a decrease in glycogen and ascorbic acid. The content of DNA and RNA decreases, with a violation of a certain ratio.

This becomes clear if we take into account that chronic poisoning with iodine vapors is characterized by a violation of metabolic processes.

Consequently, the changes found are a particular manifestation of general changes in the body. This is also proven by the morphological studies of some internal organs of animals.

Comparison of clinical symptoms with histomicroscopic changes shows their certain unequal significance. Clinically, more significant manifestations of iodine intoxication were expressed in the eye-

lids, conjunctiva, cornea, iris, while in morphological research, changes affected all membranes of the eye, with predominant damage to the retina and vascular tract.

For pedagogical reasons, we offer students a summary of what has been said, so that after this we can make a logical transition to measures for preventing damage to the organ of vision in hearth production.

When examining the organ of vision in workers in various iodine production shops, changes were found in various parts of the eyeball.

Analysis of the condition of the accessory apparatus and the anterior part of the eye showed that pathological changes in workers in especially hazardous shops (iodine sublimation, iodine crystallization, technical iodine shop and adsorption shop) are more common than in workers in other production departments. Among the pathological forms, the primacy belongs to chronic blepharitis, conjunctivitis, blepharoconjunctivitis.

As for pterygium and pinguecula in contrast to the tire factory, they are relatively rare in hearth production and mainly in people with a long work experience.

Corneal lesions often have the character of epithelial defects or cloud-like opacities, which are mainly located in the paracentral sections.

The greatest number of cases with lesions of the adnexa and anterior segment of the eye occur in people aged 31-40 years, with work experience from 6 to 10 years.

Consequently, changes in these anatomical structures occur as a result of long-term exposure to occupational hazards. Among the factors that have a harmful effect on the eyes in the hearth factory, it is necessary to point out the impact of iodine vapors, vapors of organic and sulfur compounds, nitrogen oxides and alkalis. This gives us the right to believe that the above changes arise as a result of long-term chronic intoxication with a complex of chemical compounds.

As a result of such influence, corneal sensitivity is often impaired. It should be noted that the greatest number of cases with decreased corneal sensitivity occur among workers in particularly hazardous workshops, while in people who are in conditions of increased iodine vapor content intermittently (acid stations, raw material bases, repair and mechanical and repair and construction workshops), this percentage is significantly lower.

A certain dependence was revealed between the frequency of corneal sensitivity disorders and the length of service. Moreover, in the same individuals, with an increase in length of service, there was a noticeable decrease in tactile sensitivity of the cornea. A decrease in corneal sensitivity is noted in the first 6-10 years of work in production, and in subsequent years this symptomatology is expressed somewhat less. In the group of people with experience (over 15 years), we could note stability, or even some decrease in the number of cases with a decrease in corneal sensitivity.

Such a phenomenon, apparently, should be considered in terms of a certain adaptation of the nerve endings of the cornea to the effects of harmful iodine vapors. The difference in corneal sensitivity with the control group is quite significant. This is explained by the high sensitivity of the corneal nervous system to toxic substances and early disruptions of its neurotrophic functions from exposure to even small concentrations of occupational hazards.

Peculiar specific changes in the form of deposits of iodine-colored elements in the conjunctiva of the eyeball above the upper limbus, as well as the appearance of dark brown areas with crystalline glittering inclusions in the iris of workers, can be considered signs of specific chemical intoxication in iodine production. Changes in the lens, vitreous body and fundus of the eye are observed in workers in iodine production. The latter are manifested in a violation of the caliber of the retinal vessels and the development in some cases of dystrophic changes in the area of the macula lutea.

It is difficult to assert that these symptoms are the result of exclusively chronic industrial intoxication.

This assumption is confirmed by the fact that in the following five years, we failed to observe an increase in the number of cases with changes in the fundus.

The study of the chronic effect of iodine vapors on the state of visual functions is of particular interest. The study of this issue has not only theoretical but also practical significance for the early diagnosis of functional disorders of the visual organ, which often precede the development of organic eye lesions.

The results of the study made it possible to identify a decrease in visual acuity in a group of people in the most hazardous shops of the iodine plant. At the same time, a certain direct dependence of the

frequency and degree of decrease in visual acuity on the length of service in this production area was discovered.

The conducted studies on the study of the visual field established a narrowing of its boundaries to white and red colors in more than half of the workers. It should be noted that the boundaries of the visual field were more narrowed in people working in the most harmful shops of the iodine plant and having a long production experience. The cause of the narrowing in some cases was eye diseases, as well as functional disorders, which were caused by chronic intoxication.

To identify early and subtle functional changes in the visual organ during chronic exposure to small doses of chemical hazards in iodine plant workers, a certain role is played by studying the state of light sensitivity.

When analyzing the results of the study, the degree of hazard in the production area and the worker's work experience were taken into account.

It should be noted that the iodine plant workers show a noticeable decrease in the level of light sensitivity, which is detected much earlier and more often than changes in the boundaries of peripheral vision.

The data on the state of light sensitivity were directly dependent on the length of service in this production. At the same time, these changes were more common in hazardous workshops than in other production areas. A decrease in the level of light sensitivity was determined in individuals whose age did not exceed 40 years, so the obtained facts could be associated with the lability of the autonomic nervous system of young people and the impact of toxic production factors. The changes revealed were mainly functional in nature. The results of functional disorders to a certain extent correlate with the morphological studies performed, which show certain disorders in the structure of the nerve elements of the retina and optic nerve.

The detected decrease in the quantitative content of nucleic acids should be explained by hypoxia in nerve cells.

It has been established that all these disorders are combined with certain changes in the structure of the organic matter of vascular membranes, which leads to an increase in their permeability. Metabolic shifts in the content of glycogen and ascorbic acid undoubtedly play a role.

Considering the possibility of a toxic violation of the level of ophthalmotonus in workers in various workshops of the iodine plant, the study of intraocular pressure is of great practical importance.

A study of the dynamics of the level of ophthalmotonus in people with 3-5 years of work experience did not reveal an increase in pressure. However, glaucoma was diagnosed in three people with 12 to 17 years of work experience. The latter, in our opinion, is not toxic, since in subsequent years, a study of the state of ophthalmotonus in dynamics did not reveal an increase in its level in a single case.

It is impossible not to highlight the fact that we have established a tendency towards a higher level of ophthalmotonus in individuals who were constantly in contact with iodine vapors (in comparison with the control group).

Thus, clinical observations, supported by experimental studies, reveal a higher frequency of functional and structural changes in the visual organ in individuals with chronic intoxication with harmful chemical compounds of the iodine plant in comparison with workers who do not have industrial contact with these harmful substances.

It is possible that changes in the visual organ, especially decreased visual acuity, corneal sensitivity, narrowing of the peripheral visual field and changes in light sensitivity in some cases occur earlier than other disorders in the body and are one of the signs of general intoxication.

This information is of great practical importance. Knowledge of the described symptoms should facilitate early detection of changes in the visual organ that occur under the influence of harmful chemicals and their timely treatment, as well as the widespread implementation of preventive measures, which in turn will lead to a decrease in eye pathology in chemical production.

System of measures to prevent damage to the visual organ in iodine production. The conducted studies revealed that the technological process of obtaining iodine from formation waters is accompanied by the release of vapor and gaseous chemical substances into the air at workplaces, which often have a harmful effect on the visual organ. In this regard, it is recommended that iodine enterprises implement a number of measures aimed at improving working conditions and reducing eye diseases. These include:

1. Elimination of gas emissions and manual labor-intensive operations by improving technological

equipment and automating the operation at all stages of the iodine production process.

When a large amount of evaporating iodine is released into the air, the following is required:

a) careful sealing of the equipment with the removal of vapors from it by means of supply and exhaust ventilation of the appropriate capacity;

b) mechanization of the transfer of crystalline iodine into molds, their transfer to the press and the pressing process itself.

1. A great danger to workers occurs in the iodine crystallization shop. Therefore, in the crystallization rooms and in the adjacent pressing departments, it is necessary to equip supply and exhaust ventilation, and the ventilation must be built in such a way that air is extracted directly from the sources of steam and gas emissions and from the breathing zone in the workplace. Clean air must also be supplied here.

Along with this, the air removed from shops containing large amounts of iodine must be purified by capturing it in absorbers, such as a solution of potassium iodide. In the iodine sublimation shop, where iodine is loaded into sublimation apparatuses, unloaded from cooling cuvettes, crushed on packing tables, and packed into glass containers, a very large amount of iodine vapor and dust is released. To eliminate these phenomena, it is recommended to change the technology of the above processes; mechanize the crushing of iodine, and equip the packing tables with side sections.

1. To avoid evaporation and emissions of sulfuric acid and chlorine in the water oxidation section, it is necessary to install hermetic hatches on mixers and unpaired tanks. Oxidizers should be discharged into chlorinators and mixers using acid meters.

2. Keep records of people with eye diseases and arrange for their dispensary observation.

3. Strictly observe the rules of professional selection for each production, profession and specialty.

4. Ensure control over compliance with lighting standards, permissible dustiness, and permissible concentrations of toxic substances in the workshops.

5. Industrial aesthetics and scientific organization of labor should be widely introduced in work areas associated with the risk of eye damage.

6. In order to improve medical care for industrial eye injuries, simple, comprehensive treatment plans should be developed, with

the possibility of their use in industrial conditions. It is recommended that the list of drugs used for iodine injuries include a cocaine solution for instillation, which precipitates insoluble iodide cocaine.

7. In order to improve the level of hygienic knowledge of plant workers, it is necessary to improve the methods of sanitary and light work. Along with the above, comprehensive plans for the work of feed plants must include measures to improve the technical and sanitary culture of workers.

8. The ophthalmologist, with the help of the administration, is also obliged to introduce personal and collective eye protection equipment in production. In areas technically associated with the use of sharp oxidizers, in order to avoid accidents and eye burns, it is necessary to use personal protective equipment - glasses of the Monoblock and Progress type. Those working in the adsorption shop should, along with respirators, also use protective glasses of the Progress-2 - 3 type.

Crystallizer operators must perform technological operations in gas masks in order to avoid irritation of the mucous membranes with iodine vapor. The implementation of the proposed set of sanitary-hygienic, technological and organizational measures will undoubtedly contribute to the reduction of occupational diseases of the body, including occupational eye damage in workers in iodine production, as well as the improvement of working conditions, purification of the air, and the reduction of pollution and gas contamination of the plant and adjacent territory.

SECTION V

PROPAEDEUTICS OF EYE MICROSURGERY

In the section on eye microsurgery offered to the reader, which is essentially an introduction to the problem, the authors decided to highlight under the heading of propaedeutics from the Latin propaedeutica (preliminary training, preparation), which in turn comes from pro (before) and paedeu (educate, train).

Such systematically presented introductory material, from our point of view, is absolutely necessary in accordance with the guidelines that are laid down as a basis in the curriculum and program of the cycle of thematic advanced training for ophthalmic surgeons "Eye Microsurgery" (see below).

Microsurgery is a qualitatively new stage in the further development of the surgical activity of an ophthalmologist, which arose on the basis of the achievements of scientific and technical progress in recent years. It is our deep conviction that at present all surgical interventions on the eyeball, and especially cavity operations, should be performed exclusively at the microsurgical level.

This also applies to some reconstructive and cosmetic interventions on the adnexa of the eye. This opinion follows from a comparative assessment of the quality of the surgical intervention itself, the course of the postoperative period and the outcomes of operations performed in the style of surgical traditions of past years, or performed in accordance with the principles of microsurgical installations of the present time. Experience convinces us that it is precisely the microsurgical technique in combination with the use of optical magnifying systems and powerful illuminators (against the background of the use of microsurgical instruments, needles and suture material) that ensures the accuracy of the manipulations performed. The latter are reduced mainly to incisions of the eye tissues, the implementation of reconstructive elements with the subsequent suturing of the surgical wounds.

The precision of the stages in surgical intervention leads to a defining characteristic of microsurgery: minimal trauma from the surgeon's actions, while preserving normal anatomical relationships between tissues as much as possi-

ble. This, in turn, results in significantly greater safety during surgical procedures, meaning reduced risk and improved anatomical and functional outcomes.

Microsurgery currently continues to develop in two directions. Firstly, microsurgical techniques make it possible to significantly improve traditional operations, figuratively speaking, to give second birth to well-known, widespread interventions that are performed daily by ophthalmic surgeons of any eye department. This includes cataract extraction, standard antiglaucoma operations, suturing penetrating traumatic wounds of the cornea and sclera, removal of foreign bodies, keratoplasty. All of them, performed under a microscope, are distinguished by a higher quality, which determines the final result of treatment.

The second direction of development of microsurgery is the development and implementation (so far mainly in ophthalmological research institutions, problem laboratories and eye clinics) of fundamentally new types of surgical procedures, often of an optical-reconstructive nature.

These include, in particular, the keratomileusis operation, which changes the optical power of the cornea, which helps to reduce the degree of myopia; the operation of transplanting an artificial cornea, known to ophthalmologists as "keratoprosthetics", bandage strengthening of the cornea and thermokeratoplasty, recently developed for the treatment of acute and progressive keratoconus, the operation of implanting an artificial lens into the eye cavity with various options for its location and attachment to the tissues of the eye, vitreophagy.

Some fundamentally new microsurgical interventions have now become the property of practical ophthalmological institutions. These are, first of all, pathogenetically oriented operations for primary glaucoma, extracapsular cataract extraction using phacofragmentation and phacoemulsification methods.

However, further development of the microsurgical direction of ophthalmology will depend not only on the capabilities of technical equipment but to a large extent on the training of microsurgeons.

This consideration was recognized by the USSR Ministry of Health, which issued Order No. 145 on November 11, 1975, titled 'On Measures for the Further Development of Surgical Care for Eye Diseases.' Under this order, 11 re-

search institutes focused on eye diseases, along with departments of ophthalmology at medical institutes and institutes for advanced training of doctors, were designated as centers for eye microsurgery.

Such a center is the Department of Ophthalmology of the Central Order of Lenin Institute for Advanced Medical Studies. The department is tasked with conducting thematic advanced training of ophthalmological surgeons. The goal of the thematic advanced training cycle "Microsurgery of the Eye" is to familiarize students with the basics of the operation.

The cycle enrolls heads of ophthalmology departments of republican, regional and provincial hospitals and heads of departments of large ophthalmology hospitals.

The pedagogical process is carried out by the department in the form of correspondence and full-time training. It includes the performance of pre-cycle work for four months without interruption from work and a subsequent two-month full-time cycle of improvement at the department.

The following tasks are completed in the pre-cycle phase of training:

1. Modern installations for the treatment of penetrating wounds of the eyeball (with an analysis of our own clinical material for 5 years).

2. Pathogenetically oriented operations for primary glaucoma (with an analysis of our own observations).

During the full-time advanced training cycle, the pedagogical process is conducted on a very diverse topic of microsurgical direction. The curriculum includes the following topics:

1. History of the use of surgical microscopes and microinstruments. Introduction to different types of microscopes.

2. Instrumentation, needles and suture material for microsurgeries.

3. Microsurgical technique of suturing traumatic wounds of the conjunctiva, cornea, sclera and iris.

4. Microsurgical technique of cataract extraction surgery. Introduction to artificial lens implantation surgery.

5. Microsurgical technique of antiglaucoma surgeries.

6. Corneal transplant surgery (layer-by-layer, penetrating). Keratoprosthetics.).

Particular attention is paid to the analysis of complications encountered during these operations, methods of prevention and elimination of these complications using a microscope. The task of the practical part is to consolidate the theo-

retical knowledge obtained by the cadets during lectures, to practice microsurgical techniques on simulators in a special training operating room, to master the skills of operating under a microscope on the eyes of animals, cadaveric eyes using microinstruments, microneedles and special suture material, assisting during operations, and independently performing operations. The task of the teacher is to demonstrate the possibilities opening up for a surgeon operating under a microscope, using the example of cataract extraction, pathogenetically oriented antiglaucoma operations, and keratoplasty. The doctor masters the technique of performing the following operations under a microscope: cataract extraction, sinusotomy, trabeculotomy, iridocycloretraction, basal iridectomy, goniotomy, goniopuncture, keratoplasty (layer-by-layer, partial penetrating, subtotal).

The number of students in the cycle does not exceed 5 people. This is explained by the peculiarity of the working conditions. Doctors are trained in new methods of surgical actions, which requires long individual lessons with each of them, education and consolidation of new complex surgical techniques.

It should be noted that acquiring the necessary knowledge and skills in eye microsurgery poses significant challenges for medical students, due to the limited availability of educational literature on the subject. The existing publications include: M.M.Krasnov's *Glaucomatous Microsurgery* (Medicine Publishing House, 1974); the collection *Eye Microsurgery*, edited by Academician of the USSR Academy of Medical Sciences, Professor M.M.Krasnov (Moscow, 1976); S.N.Fedorov's *Implantation of an Artificial Lens* (Medicine Publishing House, 1977); the collection *Reconstructive Ophthalmic Surgery*, edited by Academician of the USSR Academy of Medical Sciences, Professor M.M.Krasnov (Moscow, 1979); and various individual articles published in periodicals that address specific issues of eye microsurgery from a scientific perspective, though they are not specifically educational in nature. Therefore, the publication of the first domestic textbook on the subject in 1982, *Microsurgery of the Eye* by A.I.Gorban and O.A.Dzhaliashvili, was a significant milestone, offering undeniable value to doctors. Building on this, we are incorporating several key aspects of this monograph into postgraduate advanced training, as

well as the propaedeutics section of eye microsurgery.

The introductory elements in microsurgery offered to the reader, written from the position of teachers with solid experience of their own microsurgical practice and experience in conducting the pedagogical process on the cycles "Microsurgery of the eye", should to a certain extent fill the existing gap in the educational literature and help practicing doctors, in particular when performing inter-cycle assignments (see above). We have selected topics designed primarily for ophthalmologist-surgeons with a certain amount of experience in their specialty, who are required, in accordance with the demands of the time, to switch to performing operations under a microscope. With the beginner microsurgeon in mind, we considered it necessary to present, first of all, modern installations for the equipment and operation of a microsurgical operating unit, the basic principles of microsurgical interventions.

Since microsurgery arose and began to develop on the basis of surgical interventions in primary glaucoma, there was a need to cover such a topic as the morphological basis of microsurgical interventions on the hydrodynamic structures of the eye, as well as the issue of biomicroscopic inoscopy in the selection, implementation and evaluation of pathogenetically oriented microsurgical operations in primary glaucoma. At present, all emergency care for penetrating eye wounds has been transferred to the microsurgical level. A great achievement of healthcare is the creation of ophthalmo-traumatology centers in the country, equipped with modern microsurgical equipment. Considering the fact that almost all ophthalmic surgeons are involved in providing emergency care for eye injuries, we considered it appropriate to cover the issues of microsurgical treatment of wounds of the eyeball, outlining the elements of reconstructive surgery and modern conservative treatment.

Since microsurgery in ophthalmology is closely related to the surgical activities of an ophthalmologist of a broader scope (performance of such surgical interventions as dacryocystorhinostomy, enucleation, evisceration of the eye, strabismus surgeries), in presenting the materials the authors decided to touch upon such issues that are simultaneously related to both microsurgery and ophthalmic surgery as such. This includes, for example, the processing of surgical instruments after purulent operations, in

the presence of Botkin's disease in the anamnesis, sharpening of cutting instruments, potentiated drug preparation of the patient for surgery, anesthesia, and infection prevention measures. At the request of the listeners, these questions have to be presented during the microsurgical improvement cycles and, taking into account the same request of practicing doctors, we have included them in the publication.

The authors hope that the materials in this section will be useful both for those undergoing advanced training in microsurgical centers and for doctors who are proficient in ophthalmic surgical techniques and who have decided to begin mastering ophthalmic microsurgery on their own (with the availability of an operating microscope and microsurgical instruments).

Chapter 1

MODERN INSTALLATIONS FOR EQUIPMENT AND EXPLOITATION OF A MICROSURGICAL OPERATING UNIT

The work of a microsurgeon will meet modern requirements only if it is performed on the basis of a specially equipped operating room, where the main features of interventions on the eyeball and its adnexa with the use of an operating microscope and microsurgical instruments are taken into account. In the process of practical work and teaching, we had to see various types of operating rooms, starting from very modest ones in remote areas of the country and ending with excellent operating blocks in research institutes and experimental clinical laboratories, equipped taking into account all modern requirements of ophthalmic surgery. The average practitioner, naturally, cannot be oriented towards the latest version of the microsurgical operating room. Therefore, further in our presentation, we will dwell on modern requirements for equipment and operation of the operating block in relation to the institution of practical health care. An example of such an institution is the clinical basis of the ophthalmology department of the Central Order of Lenin Institute for Advanced Medical Studies, where the educational process is carried out under the program "Microsurgery of the Eye".

At one of these institutions—the Moscow Ophthalmological Clinical Hospital named after the Order of the Red Banner of Labor—

a 300-bed facility, there are three microsurgical operating rooms and a quantum operating room, capable of performing 30-40 surgical interventions per day. According to the staffing plan, the team includes a head of the operating block, an anesthesiologist, and 16 mid-level medical staff members.

Preoperative room. If it is generally accepted that a theatre begins with a cloakroom, a hospital with an admissions department, then in relation to the operating block it should be said that it begins with the preoperative. The system of the preoperative room with two doors (entrance and exit) located at opposite ends is very convenient, which facilitates the process of transporting patients to and from the operating rooms. The preoperative room is connected to the doctors' rest room, the nurses' room, wardrobes for medical personnel, a sanitary unit with a toilet and shower. Anesthetic supplies and cylinders with compressed carbon dioxide are stored in the preoperative room.

Some surgeons prefer to place these cylinders in the operating room, so to speak, "closer to the consumer", so that the cooled cryoextractor can be delivered to the work faster and does not lose the acquired minus temperature when transferred from the preoperative room. However, if two or three microsurgeons work in the operating room at the same time, they can be irritated by the noise of the gas strings that occurs when filling the cryoextractor. In addition, if the cylinder with carbon dioxide is not tightly sealed, a leak of the latter can occur, with the appearance of a specific gas smell in the operating room.

The preoperative room should also have a refrigerator set to a temperature of 4°C for cadaveric eyes, corneas, sclera, brefobones, cartilage and other donor materials needed for plastic reconstructive interventions.

It is very useful to make a built-in cabinet with a display case for storing instruments, where the instruments lubricated with Vaseline oil should be placed in strict order and disassembled.

Silica gel should be placed next to them to absorb excess moisture since it can cause rusting of the instruments, especially poorly dried ones.

If the cabinet is located in a darkened area of the preoperative room, it is useful to provide it with bright artificial lighting, which will help the surgeon quickly navigate

in the selection of the necessary instruments before the operation.

In addition, the light bulbs will help to warm the air and make it drier, which is beneficial for the instruments stored in the cabinet. If possible, it is better to place the cabinet with instruments in a separate room, since, despite its hermeticity, moisture penetration cannot be guaranteed (the air humidity in the pre-operative room is usually increased even if neither autoclaving nor boiling of instruments, hand brushes, or linen is carried out in the room).

It is in the pre-operative room (and in no case in the operating room) that boxes with sterile masks, gowns, and containers with shoe covers for the feet should be placed in order to completely eliminate the process of dressing the surgeon in the room where microsurgical interventions are performed.

Operation of the operating block should include useful elements of scientific organization of labor, which contributes to the automation of work, and, therefore, its acceleration, helps to reduce the time for performing a number of ritual actions for the surgeon, and raises the aesthetic side of the work to the proper level.

In particular, the element of "NOT" can be introduced into the seemingly insignificant moment of preparing for washing the hands of the surgeon and mid-level medical personnel.

Since microsurgery almost completely excludes the use of rubber gloves, it requires perfect maintenance of hands, fingers and nails. It is not uncommon to see how individual employees are busy searching for scissors and a nail file before the start of the operating day, which, naturally, takes time. For these reasons, it is useful to have a ready-made tray with scissors, a nail file, acetone and cotton wool for removing varnish (Fig. 54) near the hand wash basin, where boiled brushes for mechanical hand treatment are usually stored in a 2% solution of carbolic acid.



Fig. 54. **Accessories for mechanical treatment of nails of medical personnel**

It is very convenient to use and economical to use soap that is not

in a soap dish next to the water tap and therefore gets wet but is suspended by the tap on a magnet.

The elements of 'NOT' in the pre-operative room include boxes containing sterile wipes and gowns, each equipped with a pedal system for opening and closing the lids.

In this case, surgeons and nurses will be able to dress without the help of junior medical personnel.

Sterilization of the surgeon's hands. Particular attention should be paid to the correctness of the process of sterilization of the surgeon's hands. Whichever of the many existing methods is used, it should include the procedure of mechanical washing off bacteria on the skin along with the surface layers of the epidermis. Next comes the treatment of the skin with one of the antiseptics, followed by an element of tanning.

This causes a narrowing of the pores and thus prevents the migration of microorganisms to the sterile surface of the skin during the surgical intervention.

In our own comparative assessment of methods for treating surgeons' hands, we found the accelerated washing method using acrylic hydroperoxides, synthesized by F.Yu.Rachinsky and V.T.Osipyan in 1967, to be the most rational. Studies have confirmed the high bactericidal and sporicidal activity of hydroperoxides.

The most effective preparations were acetic anhydride and formic acid combined with a hydrogen peroxide solution. In 1974, at the Moscow Ophthalmological Clinical Hospital, we became the first in ophthalmic practice to use a hand treatment method involving a mixture of hydrogen peroxide and formic acid (the 'pervomur' mixture).

The effectiveness of disinfection was initially tested by bacteriological testing of the wash taken from the hands of surgeons, after which the washing method was put into effect. The method of hand treatment is very simple. Within a minute, you should wash your hands (up to the elbows) with soap under a running tap (without brushes), then in a basin where "Pervomur" is poured. Hand treatment with "Pervomur" takes only 1 minute. In 5 liters of the mixture in one basin, without changing the solution, 10 people can treat their hands.

Having dried their hands with a sterile napkin and put on a sterile gown, the surgeon can begin work. This method of hand disinfection reduces the time it takes the surgeon to prepare for surgery by 4-5 times. It completely eliminates the

use of ammonia solution, ethyl alcohol, iodine tincture. The consumption of soap is also significantly reduced.

Additionally, it should be noted that at the end of the operating day, if the surgeon has used the 'pervomur' mixture, they should wash their hands with soap, dry them thoroughly, and then apply a thick cream.

The method for preparing the "pervomur" mixture is as follows: 171 ml of 30% hydrogen peroxide is poured into a 5-liter bottle, then 81 ml of 85% formic acid. After mixing the contents of the bottle by shaking, it is placed in the refrigerator for 1 hour (in a bucket of cold water). Then distilled or boiled water at room temperature is added to the bottle (up to 5 liters). The solution is suitable for use within 24 hours.

At present, the method of treating hands with diocide is quite common. The method consists of ordinary hand washing with soap under a running tap, followed by immersion in a 1:5000 diocide solution for 3 minutes. After drying your hands with a sterile napkin, they are treated with alcohol. Disinfection of hands with diocide ensures sterility in 86% of cases.

In a large hospital, where up to 30 medical personnel process their hands in the pre-operative room daily, it is advisable to offer a choice of hand washing methods. At least two methods should be available. It is also helpful to introduce a 'NOT' element, such as a reminder for the surgeon or nurse regarding the sequence and exposure time for hand processing according to each method. For this purpose, the recommended method can be written on the white tile on the wall in front of the sink using permanent Nitro paint (Fig. 55).

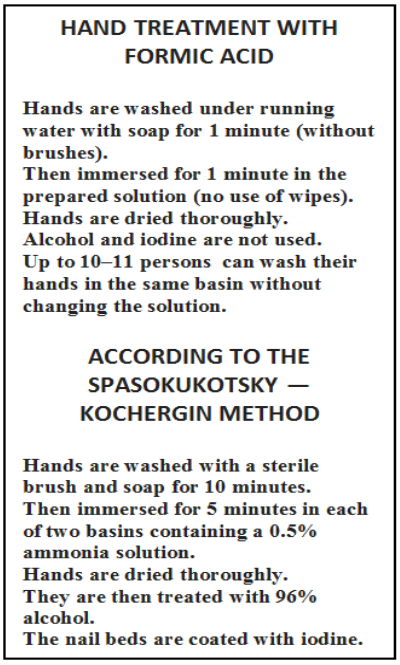

Fig. 55. **Methods of hand sterilization for the surgeon and operating nurse**

Surgical linen. Having addressed the issues related to preparing the surgeon's hands, it is essential to also consider important in-

formation regarding surgical linen. According to recent regulations, operating room linens should consist of two colors: non-sterile gowns and masks for junior medical personnel should be white, while all sterile accessories should be made from colored materials, such as blue or light blue fabric.

Preference in the choice of material for sewing should be given to satin. Colored linen includes a sheet covering the patient, napkins on the instrument table of the operating nurse, a mask on the patient's face. It should be noted in passing that the mask should under no circumstances be made of gauze: gauze, especially when shaken before applying it to the patient's face, scatters small fibers of fabric that settle on the optical units of the operating microscope. A mask made of colored satin should hang down from the operating table; as for the hole in the mask that limits the operating field, it must be hemmed with a seam.

The size of the hole ("window") must be within 3x5 cm. The sheet thrown over the operating chair must also be colored (sterile), as well as the gowns of the surgeon, assistant, and operating nurse.

A.I.Gorban and O.A.Dzhaliashvili (1982) believe that a special cut of gowns should be recommended for microsurgeons, taking into account the fact that the surgeon sits in a chair, and his head should be tilted at a certain angle to the eyepieces of the microscope. The back folds of the gown are cut off, which creates a comfortable fit in the chair. In front of the round neckline, the collar of the gown is cut vertically downwards up to 10 cm long (Fig. 56), which facilitates unhindered tilting of the head.

The sleeve of the gown should be buttoned: the laces often break, and the knot when tying them can interfere with the position of the hand on the armrest of the operating chair. As for the surgeon's mask, it is permissible to make it from several layers of gauze. Usually, the mask covers not only the face but also the head, leaving only the eyes free, for which an oval hole is made (Fig. 57). The surgeon, having arrived in the operating block, in a room allocated for changing clothes, takes off his white hospital gown and changes into special operating pajamas.

A colored sterile gown is put on over the pajamas after hand disinfection.

Operating room. A special room should be allocated for micro-surgical operations, in which purulent operations should be strictly prohibited (even at the end of the operating day, when all the so-called "clean" operations have already been performed).

The walls of the microsurgical operating room are preferably covered with colored (even black) tiles. It creates a contrast in lighting, is devoid of bright light reflections and does not tire the eyes working in the room.

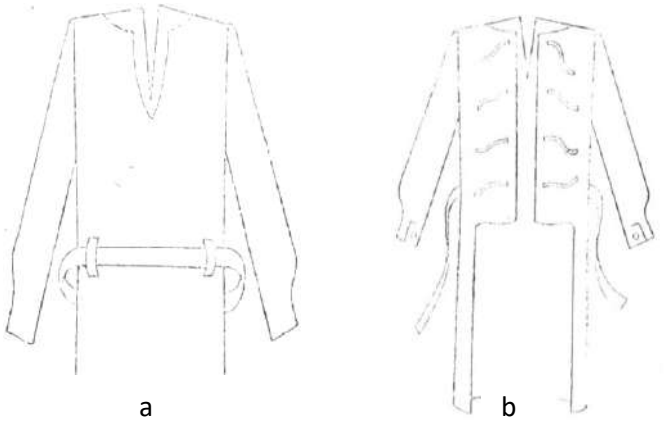

Fig. 56. **Microsurgeon's gown: a -front view; b-back view**

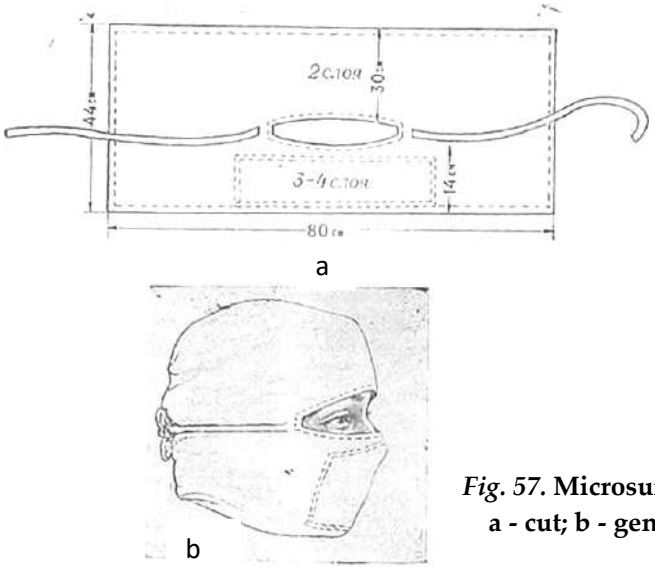

Fig. 57. **Microsurgeon mask a - cut; b - general view**

The area of the microsurgical operating room, in accordance with the requirements of the present time, should be calculated at 36 m^2 per operating table. There should be one operating table per 15 beds of the surgical eye hospital. Microsurgical operating rooms should be

especially carefully cleaned of dust since the time required for an operation under a microscope is significantly longer than performing surgical interventions using conventional techniques.

Naturally, under these conditions, the eye wound remains open for a long time, in contact with the surrounding air. For these reasons, as well as to create a favorable at mosphere of comfort for the patient and the surgeon, artificial ventilation of air is necessary, for which air conditioners are used with the ability to exchange air within an hour equal to 10 volumes of air in the operating room. A microsurgical operating room must be equipped with a system to curtain the windows. Naturally, shutters on the inside or various types of curtains on the windows are not acceptable. The best solution for darkening is the installation of dark curtains, such as rolls of black paper with a mechanical mechanism for lifting and lowering, placed between the window frames. A microsurgical room without windows is also acceptable and even preferable.

An important rule for a microsurgical operating room is the prohibition of boiling instruments or eye drops within it, as the steam from boiling water can damage the delicate optics of the surgical microscopes.

Operating microscopes. The central place in the operating room is occupied by the operating microscope. To date, several types of operating microscopes have been created in ophthalmology worldwide. They differ in different methods of fastening (on the floor, ceiling, step), various devices for changing the degree of magnification of the object being examined (there is a step change in magnification, as well as a smooth one, called transfraction). At first, the latter type of change in magnification attracts with the smoothness of the transitions. However, experience shows that the process of transfraction is accompanied by a change in the sharpness of the image of the object, which requires additional focusing. Since in microsurgery it is not so often necessary to change the degree of magnification, and usually only two degrees of magnification are sufficient, a practicing physician may be quite satisfied with, by the way, a stepwise change of microscope magnifications, which is cheaper in cost.

Magnifications required for microsurgical work fluctuate within the limits of 4 to 40 degrees with a field of view diameter measurement from 8 to 30 mm. Naturally, the size of the field of view is inversely proportional to the degree of magnification of the microscope. Strong magnification leads to a limitation in the surgical field.

The change of magnification can be provided either manually or by a pedal (using the legs).

Microscopes also differ in the design of the objective and eyepieces. An objective with a vertical or almost vertical position above the surgical field is advantageous. This eliminates interference (shadows) that arise from the surgeon's hands and instruments when the objective is inclined.

The eyepieces of a binocular stereoscopic microscope can be located on the same line (along the extension of the axis) with the objective and can be inclined at an angle of 45°. The latter option for arranging the eyepieces is more convenient in work since the surgeon can freely look into the openings of the eyepiece tubes without resting against them with the lower orbital edge. The designs of surgical microscopes differ in different types of illumination. The light can be coaxial, that is, with the incidence of the light beam approaching the axis of the microscope at an acute angle.

There is lateral diffuse and lateral slit illumination. The most advantageous is considered to be a combination of different types of illumination, which eliminates the possibility of shadows and glare.

Some surgical microscopes also include a stereoscopic binocular microscope for an assistant.

Opton surgical microscopes are well-known in the field of ophthalmology worldwide. Many research institutes, ophthalmology departments at medical schools, and institutions for advanced training are equipped with various models of surgical microscopes from Opton and other foreign optical companies. However, in this presentation, we will focus less on working with imported equipment. In our country, with the increasing number of ophthalmologist-microsurgeons and the widespread implementation of microsurgery, there should be a focus on domestically produced optical equipment, which is available in unlimited quantities. Every ophthalmologist has the opportunity to purchase a

domestically produced surgical microscope.

The simple model 457 is quite popular among the mass of practicing doctors and is also often used by otolaryngologists.

This surgical microscope (Fig. 58) consists of a binocular head with an illuminator, a transformer, and a stand consisting of a base, a stand, and a rod. The binocular head is the main part of the device, connected to the stand by means of a ball joint. It is equipped with a focal screw 7, the rotation of which ensures a clear image of the surgical field. The head can be tilted downwards using a ball joint, moved in a horizontal plane by turning the lever 3 or by moving the rod 4. The height of the binocular head is changed by moving it together with the lever and rod along the stand 5. The movement occurs in the area of the connecting sleeve 8. The illuminator of device 2 is an electric lamp (8 V, 9 W), powered by a common electrical network through a step-down transformer.

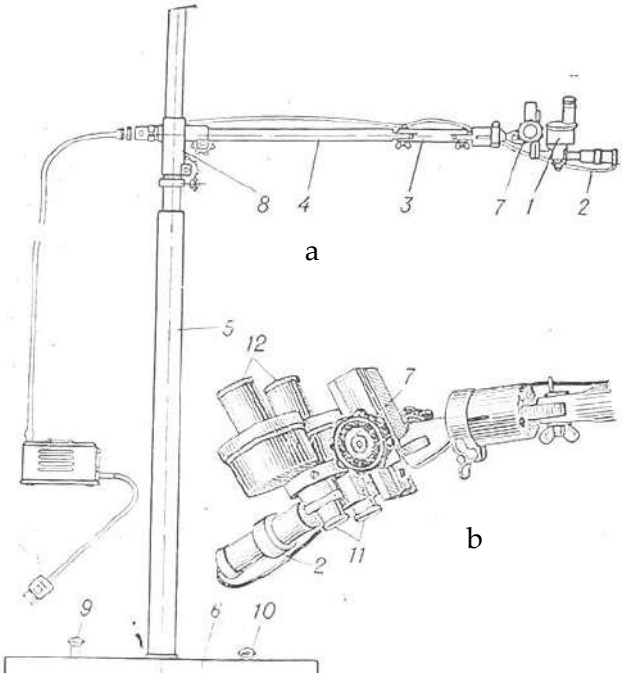

Fig. 58. **Domestically produced surgical microscope: a—general view; b—binocular head**

The lens of the illuminator is located between the objectives of the microscope, which ensures good illumination of the deep sections of the eye. The illuminated field has a diameter of 32 mm, sharp boundaries and sufficient brightness.

The optical system of the device consists of objectives 11 and eyepieces 12. The microscope kit includes four pairs of eyepieces. The magnification of the device varies from 4.5 to 21.6 times, the image is upright and three-dimensional. The entire microscope is moved using rollers with ball bearings mounted in the base of the device 6. To prevent spontaneous movement of the microscope and to fix it, there is a brake device controlled by the foot using pedals 9, 10.

Before starting the operation, it is necessary to check the serviceability of the lighting and optical systems of the operating microscope, find out what voltage the transformer will operate on. The illuminator lamp must be centered. To do this, slightly loosen the lamp holder and move it by rocking until a bright round beam of light appears in the field of view. This indicates that the lamp is centered and can be fixed in this position with a locking screw.

The device is installed near the operating table and secured with a brake device. After this, the fastening of the ball joint and lever should be checked. During the operation, they should not move spontaneously and at the same time should allow a change in the position of the microscope head with a slight effort of the hand. Select the oculars needed for the work and be sure to set them according to the distance between the centers of your pupils. This ensures the receipt of a single stereoscopic image of the operating field.

Some ophthalmologists prefer to use another model of the domestic surgical microscope (OM-2), which is more often used by general surgeons and neurosurgeons (model-178). This model is equipped with a demonstration system, which allows someone present to watch the microsurgical manipulations of the operator. The model has a photo attachment, which can be fixed on the optical head instead of the demonstration system.

The lighting system has a built-in filter for daylight and red-free light. The microscope design provides for all the necessary movements to give the optical head a position convenient for the sur-

geon. This model, thanks to the demonstration system, has advantages when conducting the educational process in the operating room. For a more detailed acquaintance with the device and installation of the OM-2 microscope, those who wish can use the technical description and operating instructions, which are attached to the device by the Leningrad Production Association "Krasnogvardeets".

Medical biological stereoscopic microscopes (MBS-1 and MBS-2), slightly re-equipped for microsurgical purposes, are quite suitable for work, especially in the conditions of small district-type eye departments. These microscopes are widely used by us for exercises and practicing the technique of microsurgical operations on the eyes of animals and human cadaver eyes in the conditions of a training operating room. The microscopes give a direct, three-dimensional image of the object under examination with a magnification of 3.5 to 88 times. The light source is an 8 V, 20 W electric bulb, powered through a step-down transformer TR-10 from an AC network of 127 or 220 V. The microscope is supplied with three pairs of eyepieces with a magnification of 6X, 8X, 12.5X and an ocular micrometer with an 8X magnification with a range of distances between the axes of the eyepiece tubes (depending on the distance between the centers of the pupils of the examiner) from 56 to 75 mm.

Having removed the microscope stage, the bracket of the latter can be fixed on the rod of the illumination lamp used in surgical work. The lamp, by the way, will provide additional illumination to that which is mounted in the microscope body.

If necessary, having familiarized yourself in more detail with the passport data of the MBS-1 and MBS-2 microscopes (technical characteristics, device and operating principle, description of the design, operating rules), you can adapt them for performing microsurgical operations, as some of our colleagues do. Many ophthalmological clinical institutions and practical health care institutions are equipped with a microscope from C.Zeiss (Fig. 59). We also have to use this model mainly. The microscope is quite convenient to use. However, it largely depends on the details of its settings and corrects operation. The reader should be familiar with some of these techniques.



Fig. 59. **C.Zeiss microscope in ophthalmology clinics**

In particular, the microscope should not be placed on the side of the eye being operated on, as some surgeons do, but always on the left in relation to the patient and the surgeon (Fig. 60). The right side should be left free. Here, with their instrument table, the operating nurse and assistant are located, whose work should be interconnected and coordinated. The column of the microscope stand should be installed at the patient's chest line. In order for the microscope to have a permanent location, and for the surgeon not to waste time each time telling the staff where to place the microscope, it is useful to draw the outline of the base of the microscope stand on the floor with indelible paint. This will be its permanent location.



Fig. 60. **Positioning the microscope in relation to the patient, surgeon and assistant**

It is necessary to pay attention to the fact that all the elbows of the microscope mounts are located at right angles. The microscope illuminator (6 V, 15 W lamp) is powered from the general electrical network through a step-down transformer. The inclusion of the microscope in the network is indicated by the lighting of the lamp at the bottom of the three-legged frame of the base. Through the rheostat, three degrees of heating of the lamp can be created by moving the switch located on the electric cord.

The illumination is coaxial, which is very convenient when manipulating in the deep parts of the eye but is inconvenient during microsurgical actions on the surface of the eyeball membranes due

to the resulting glare. Therefore, coaxial illumination is advantageously combined with lateral light falling on the surgical field at an angle of 30-45°.

The illuminator needs to be adjusted before work. The electric bulb should be inserted into the socket and, having turned on the electric current, gradually moved downwards until a clear light spot appears on the screen located in front of the microscope objective. Very important units are located on the sides of the microscope head. These are the image magnification switch, the focus screw and the head tilt screw (Fig. 61). The microscope can give 5X, 8X, 12.5X, 20X and 30X magnifications. Despite the sufficient range of magnifications given by the microscope, 8X and 12.5X magnifications are most often used in practical work. The change in magnification is stepwise.

All of the above units are controlled manually. In order to maintain sterility during the operation, rubber caps are put on the above units before the operation (they are sterilized in a "pervomur" solution).

At the end of the operating day, the caps are removed. On the left side of the microscope head (under the magnification switching system) there is a device with a lever, by moving which you can place various filters in the path of light (Fig. 62).



Fig. 61. **Carl Zeiss surgical microscope:**
a- image magnification switch;
b- focus screw; c- screw for tilting the head



Fig. 62. **Carl Zeiss surgical microscope. Mechanism for changing color filters**

This is a blue-green filter, most often used to detect the smallest vessels, bleeding from which can significantly interfere with the performance of fine microsurgical ma-

nipulations. Bleeding is usually eliminated by thermocoagulation of the vessels in red-free light. The second filter, called neutral, has a slightly bluish tint.

It should be used to reduce eye fatigue of the surgeon during long-term work, for example, when performing plastic surgery. We also use this filter when removing sutures from the eyelids, conjunctiva, external capsule of the eye, to reduce the phenomena of photophobia and blepharospasm of the injured or operated eye. In the process of adjusting the microscope illuminator, it is necessary to check whether the light path is blocked by one of the specified filters. Through the eyepieces, especially when turning on the third brightness of the illumination, the so-called sighting circle is visible. 011 is located only in front of the right eyepiece, but in the presence of binocular vision, it is perceived by both eyes in the form of a black circle. Using the sighting circle, you should check the correct adjustment of the illuminator bulb.

As the bulb moves downwards in the socket under a low magnification of 5X, an image of its spiral appears in the center of the sighting circle in the form of horizontally arranged wire turns. If the image of the spiral is absent, the bulb in the socket should be additionally moved up or down. In the case of an oblique arrangement of the spiral, the bulb should be rotated around its axis until the spiral occupies the central horizontal position in the sighting circle. Using the sighting circle as a reference, the surgeon can also correct his existing ametropia (anisometropia) of refraction. In the upper section of the right and left eyepieces, divisions from zero to plus five and from zero to minus five are applied (Fig. 63). This is a diopter calculation that can be used to correct refractive anomalies.



Fig. 63. **Diopter of microscope eyepieces**

This is done as follows: looking through the right eyepiece with the left eye, the surgeon should clearly see the sighting ring (circle). If there is no clear image, optical cor-

rection should be made by turning the upper part of the eyepiece.

The number (diopter power) next to the vertical marking line indicates the optical correction required for the left eye on the left eyepiece. Similarly, the refractive error of the right eye is corrected using the sighting ring.

If the surgeon prefers to work using glasses, then, naturally, this moment of correction due to the dioptrics of the eyepieces disappears. However, experience convinces us that glasses somewhat narrow the field of vision and, in addition, with a vertical position of the eyepieces, interfere with work. When preparing the eyepieces for work, you should not forget to place their tubes according to your pupillary distance.

The last detail of the adjustment is to move the microscope focus screw all the way up (this will help relax the surgeon's eye accommodation during the work).

Before starting work, it is also useful to wipe the microscope objective with a piece of washed material, and wipe the eyepieces with a swab with alcohol to remove the grease from the eyelashes that may remain on the eyepiece glass after the adjustment process.

When working with domestically produced surgical microscopes and a microscope from C.Zeiss, some surgeons note the inconvenience of not being able to observe the surgical field well enough when sitting. This is due to the fact that the optical axis of the microscopes is located at an angle to the surgical field. E.A.Vakurin (1979) proposed making some changes to the optical system of surgical microscopes, which makes it possible to see the surgical field directly from above.

In front of the microscope objective, the author places two deflecting prisms taken from biological microscopes and fixes them in a holder that can be easily made of tin. When upgrading the domestic OM-2 microscope the prism holder can be fixed to the optical head with a long strip of adhesive tape. The path of rays from the operating field before and after upgrading is shown in Fig. 64.

When using any type of microscope, the assistant usually, as stated above, is positioned to the right of the surgeon. In the absence of a second binocular microscope, he must use magnifying optical devices, despite good eyesight.

Usually, various types of magnifying glasses are used. They re-

duce the difference in the perception of the image by the surgeon and the assistant, which makes the assistance more qualitative. It should be noted that among the available magnifying glasses, preference should not be given to the visor magnifying glass. Due to its small focal length, the assistant is forced to get very close to the operating field, and the visor of the magnifying glass rests against the optical head of the microscope.

Operating table and chair. The production of microsurgical interventions using a conventional standard operating table does not meet the requirements. Operations take a long time, so the table should be wide enough, comfortable, with a stable mounting. The dimensions of such a table are 210 cm x 62 cm, with a height of 74 cm. A device for fixing the patient's head is attached to the table, in the form of a kind of socket, semicircular in shape, like a helmet, limiting the movements of the head on three sides (Fig. 65 a).

Such restrictions are necessary for the reason that during the operation the head must be absolutely motionless. Such a non-standard table is easy to manufacture according to the drawing (Fig. 65 b) in the conditions of any metal product production.

A trolley can also be used as an operating table, which is especially convenient in cases of ceiling mounting of the microscope. In this case, the trolley table is brought under the microscope so that the eye (operating field) is under the microscope objective.

The patient's head, which is in the fixing device, is then moved outside the trolley. The advantages of the operating table-trolley are that the patient is transported to the operating room and back without unnecessary transfers from the trolley to the table and back.

As for the operating nurse's instrument table, with microsurgical technique, it is necessary to ensure its bright illumination. This is necessary for quick orientation when handing the surgeon the necessary microinstrument, for the procedure of breaking off the cutting edge of a razor, for threading the eye of a needle, etc.

In microsurgical operations, a comfortable chair is usually used, or better yet, a surgeon's chair. The chair should have a lifting and lowering device to adapt the sur-

geon sitting in it to the operating table. Care should be taken to ensure that the surgeon's arms, bent at the elbows, are positioned at the level of a certain field (not lower or higher than it).

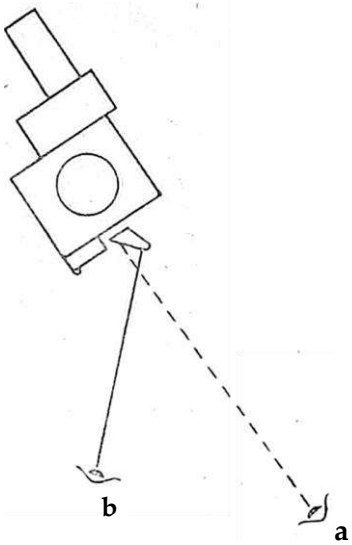

Fig. 64. **The path of light rays to the microscope objective: a—without a prism; b—using a prism**

The conditions for microsurgical work are met by a chair with a pneumatic lifting and lowering device and armrests that can be moved vertically, horizontally, in the front-back and lateral directions (Fig. 66).

The forearms and hands can be placed on horizontal planes bordering the socket where the patient's head is fixed. These planes serve as good support for the surgeon's hands during the work, relieve muscle tension and help eliminate tremors.

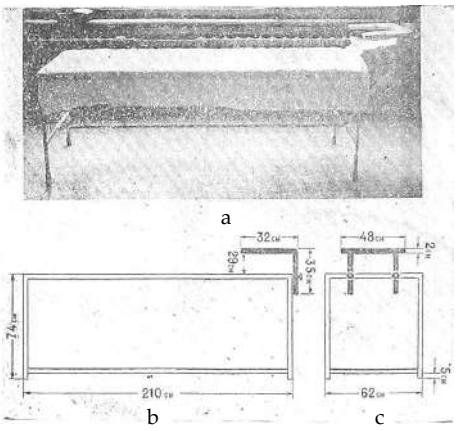

Fig. 65. **Operating table for microsurgery: a—general view; drawing-diagram (b—side view; c—front view)**

Microsurgical instruments.

The quality of microsurgical interventions is directly related to the instruments, needles and suture material. At present, due to the significant successes of the domestic medical industry, the production of sets of instruments for individual types of surgical interventions has been established. By 1980, 12 sets were released. This includes a set of instruments for cataract extraction in various modifications, including 43 items. Very popular among ophthalmic surgeons is a set of instruments for performing antiglaucoma operations. It includes

46 items, and many of the instruments in the set are of a purely microsurgical nature. Microsurgical instruments are also included in sets for removing foreign bodies, for corneal transplantation.

The All-Union Scientific Research and Testing Institute of Medical Technology (pilot-experimental plant) has developed a special set of instruments for eye microsurgery. It includes 75 instruments of 42 names for various types of surgical interventions under a microscope. The instruments in the set can also be used in operations performed without a microscope.

The microsurgical operating room, naturally, should be equipped with general surgical instruments (forceps, scissors, nippers, chisels), as well as conventional ophthalmic surgical instruments, which include eyelid retractors, eyelid lifters, a trephine cutter for performing dacryocystorhinostomy, scalpels, sets of trephines for keratoplasty, scleral trephination, etc. Without listing all the necessary instruments that an ophthalmic surgeon should have, we will delve into the characteristics of microsurgical instruments.



Fig. 66. **Operating chair for a microsurgeon**

One of the requirements for most microsurgical instruments is their specific length and thickness. In microsurgery, instruments that are neither too short nor too thin are acceptable. The instrument is grasped with two or three fingers (similar to how a pen or pencil is grasped). The fourth and fifth fingers, placed on the patient's forehead, provide support for the hand. The instrument should be long enough to reach the bend between the thumb and index finger, which will provide support for it (Fig. 67) and will help reduce the tremulous vibrations that acquire a fairly noticeable amplitude when observed through a microscope.

The proper thickness of the instrument also contributes to its

more reliable fixation by the fingers. It is quite easy to verify the validity of these remarks by trying to use a long and fairly thick pencil and a short, thin pencil or the rod of a writing pen for drawing or writing. A feeling of convenience and reliability in work is possible only in the first case. Microsurgical instruments should have a ribbed surface. On some instruments, holes are made for the same reasons, which also helps to significantly reduce their weight.

As for giving the instruments a matte dullness, it is absolutely necessary in microsurgery. The fact is that all shiny, especially nickel-plated, surfaces of instruments brightly reflect the light of the microscope, and this is an unnecessary irritant to the surgeon's eyes, distracts his attention and tires him.

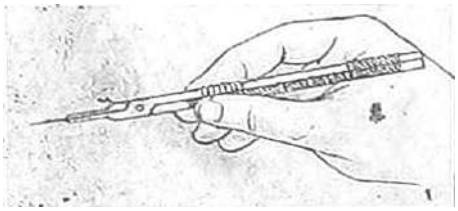

Fig. 67. **Position of the microsurgical instrument**

All microsurgical instruments can be divided into four categories: cutting, tissue-cutting, fixing and connecting.

Cutting tools.

Unrivaled in cutting quality in terms of creating an even cross-section of tissue are the razor blades "Sputnik", "Baltika", "Neva". The best should be considered the blade of the safety razor "Neva", which has the necessary hardness and retains its cutting properties for a long time. A very important factor is the ability to break off the edge of the razor and properly fix it in the blade holder. The razor break is preferably triangular in shape measuring 2X4X6 mm. Obtaining such a fragment is not difficult. The edge of the razor of the intended dimensions is tightly fixed in the blade holder, which is held with the left hand, and the rest of the blade, in order to avoid accidental injury, is wrapped in a sterile napkin and broken off with the right hand. From one blade it is possible to obtain at least four cutting fragments. The same blade should not be used to make multiple cuts. It is best to use a new blade fragment for each patient.

The quality of the fragment must be checked under a microscope to avoid bends and nicks in the cutting edge (Fig. 68 a, b).

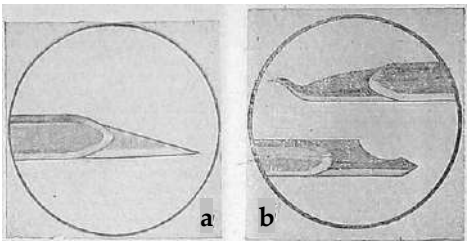

Fig. 68. **Quality of razor blade fragment:**
a—satisfactory; b—unsatisfactory

A novice microsurgeon should be advised to fix the cutting fragment in such a way that it does not protrude beyond the jaws of the blade holder by more than 1 mm. Too long an end of the fragment will cause it to vibrate when cutting tissue, which in turn will cause an uneven cut.

In addition, a long edge in the hands of a novice surgeon can cause irreparable harm. By pressing the blade on the tissue with a slightly greater force than necessary, that is, not proportioning the applied force with the degree of sharpness of the blade, the surgeon can perforate the cornea or sclera. That is why it is necessary to recognize the optimal release of the razor edge within 1 mm, which is consistent with the thickness of the outer capsule of the eye.

In addition to the razor blade, the category of cutting instruments includes linear, spear-shaped, round knives, used mainly for incisions of the outer capsule of the eye, and the Sato sickle knife for manipulations on thin tissue structures, such as the lens capsule (Fig. 69).

The classic instrument for tissue dissection is scissors. In microsurgery, in particular, for limbal incisions and corneal incisions, scissors with slightly curved branches and blunt edges are accepted. The lower branch of this type of scissors is always longer. They are divided into right- and left-handed. For cutting and excising the sclera there are scleral scissors, and for the iris - iris scissors with straight blunt branches. Scissors for Schlemm's canal are very necessary in the work (Fig. 70).

The category of cutting microsurgical instruments includes trabeculotomy and goniotomy (Fig. 71).

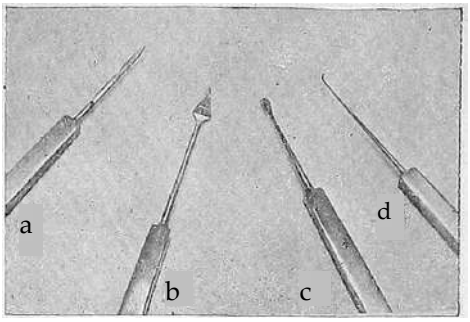

Fig. 69. **Microsurgical knives:**
a—linear; b—spear-shaped;
c—round; d—sulfur-shaped
(according to Sato)

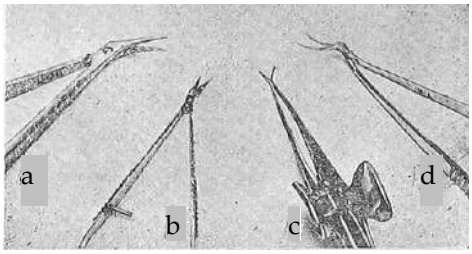

Fig. 70. **Microsurgical scissors: a—for the cornea; b—for the sclera; c—for the iris; d—for the Schlemm's canal**

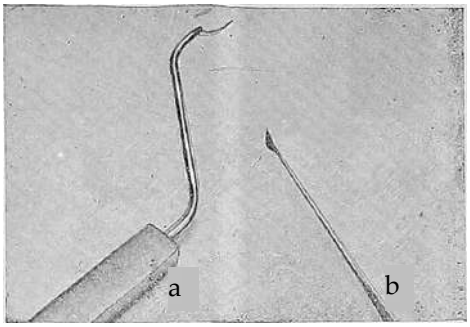

Fig. 71. **Trabeculotomy (a), goniotomy (b)**

Trephines and scarifiers (scrapers) cannot, of course, be classified as true microsurgical instruments. However, we mention them because most instruments used in microsurgery are standard instruments that have been adapted for use with a microscope.

Fixing instruments, particularly microsurgical tweezers, are essential in this context. Most microsurgical tweezers feature a special (double) curvature, resembling the neck and beak of the tiny hummingbird found in South America, which is the smallest bird in the world, weighing only about two grams.

Ophthalmic surgery is a precision surgery where the size of the objects ranges from 0.3 to 1.0 mm. As for microsurgery, it can be classified as a high-precision surgery where the size of the object is 0.1 to 0.3 mm, and even as a particularly precise surgery where objects smaller than 0.1 mm are involved. This makes it necessary to create tweezers from special metal alloys that ensure the strength of the working part (the tissue-gripping part), the dimensions of which are 0.12 to 0.25 mm (M.M.Krasnov, 1976). According to the design of the working part, the following types of microtweezers are distinguished: a — flat microsurgical tweezers; b — toothed microsurgical tweezers; v — tweezers with a working part in the form of two semicircles allow for gentle tissue grasping without puncturing or traumatizing it (Fig. 73). These tweezers (Hoskin type) are indispensable for manipulations on the iris.

Among the fixing instruments that provide optimal grip density, tweezers used for tying suture threads stand out.

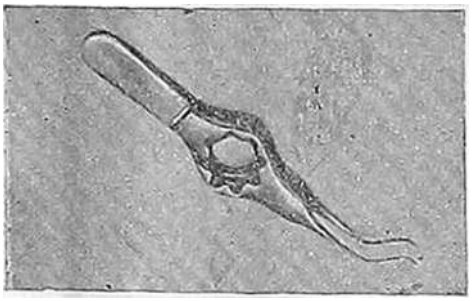

Fig. 72. **Microsurgical tweezers "hummingbird"**

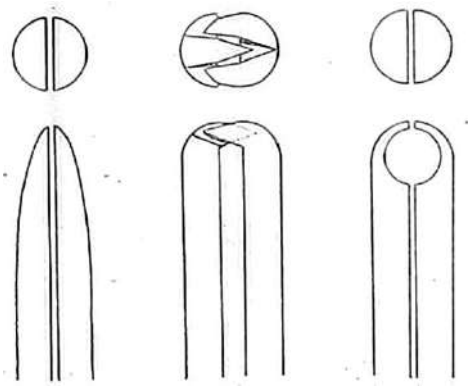

Fig. 73. **Working ends of microsurgical tweezers**

It is equipped with brushes with a groove on their inner surface and a very delicate mesh cut (Fig. 74).

To hold a razor blade fragment intended for tissue cutting, a blade holder capable of very strong fixation is required (Fig. 75). In the absence of a blade holder, a mosquito hemostatic clamp can be used to grasp the razor fragment. For ease of use, the finger support rings can be filed off the tweezers (V.G.Shilyaev, 1979).

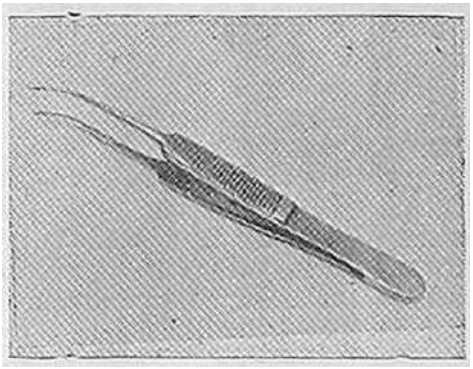

Fig. 74. **Tweezers for tying suture threads**

For the purpose of fixing needles when suturing eye wounds, very convenient spring needle holders with and without a lock have been created (Fig. 76). The first type of needle holder is preferable when working with dense tissues of the outer capsule of the eye, the second type - when suturing wounds of the iris. Since needle holders are designed not only to grasp the needle and pass it through the tissue but also quite often to grasp the micro thread and tie the suture knot, their branches must fit tightly to each other.

In order not to spoil the abovementioned properties of the needle holder, it should never be used to grip conventional (non-microsurgical) needles. For these

needles, in particular when suturing wounds of the skin of the eyelids, conjunctiva, it is necessary to use eye finger needle holders. At the same time, it is also necessary to dwell on the characteristics of eyelid speculums, which also relate to fixing instruments. They are presented in two types in domestic sets of eye instruments.



Fig. 75. **Blade holder**

This is a slatted eyelid speculum with rests on the bridge of the nose and temple, making it convenient for use during operations on the open eyeball, as it does not exert pressure on the eye. The wire eyelid speculum, being lighter, is more advantageous for use during microsurgical interventions that do not involve opening the eyeball.

Naturally, when becoming familiar with microsurgical instruments, every surgeon will be interested in questions of mechanical processing, sterilization, storage of instruments, and their sharpening.

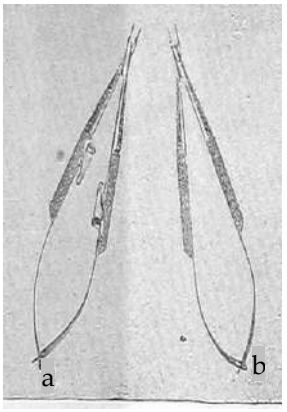

Fig. 76. Needle holders: a — with lock; b — without

Sterilization, storage and sharpening of instruments.

The instruments are processed and stored according to the general rules for surgery, with some peculiarities applicable to ophthalmic surgery and microsurgery. We present the methods adopted at the Moscow Ophthalmological Order of the Red Banner of Labor Clinical Hospital. After the operation, the instruments are soaked in a cleaning solution for 15 minutes, which includes 400.0 g of a 3% hydrogen peroxide solution, 2.0 L of water and 5.0 g of the cleaning agent "Biolot". Then the instruments are washed first with running water and then with distilled water. Sterilization is performed in a dry-heat oven at a temperature of 180° for 60 minutes. In this case, cutting instruments cannot be placed directly on trays. They

should be placed in racks, which will prevent damage to the blades. If there are no special stands, cutting tools can be laid out on foam pads.

Despite the high temperature, foam rubber does not spoil for a long time, retaining its elastic properties. Foam rubber should also be used for sterilizing needles, for which each needle, in order to avoid losing it on the tray of the dry-heat oven, should be stuck into a foam rubber pad.

It is also permissible to sterilize a needle with silk inserted into it. However, it should be remembered that silk that has undergone such sterilization two or three times becomes brittle, losing its properties.

Non-cutting instruments are well sterilized by boiling in a 2% bicarbonate solution in distilled water for 30 minutes.

In some ophthalmological institutions, a diocide solution is preferred as a sterilizing agent. The instruments are placed in a 1:2000 diocide solution for 3 minutes with the addition of an anti-corrosion agent NDA in an amount of 1.0 g per 1 liter of solution. After this, the instruments are rinsed in boiling distilled water.

According to the instructions for a set of instruments for microsurgery, sterilization of the instruments should be carried out by immersion in a 6% hydrogen peroxide solution at a solution temperature of 18-20° C. The exposure is 18 hours. At a solution temperature of 50° C, it is reduced to 3 hours.

Disinfection in 96% alcohol for an hour is allowed. After the operation, according to these instructions, the microinstruments are thoroughly washed or wiped with alcohol. Cutting instruments are wiped dry. Between operations, cutting tools should be stored in special stands or in alcohol baths. In alcohol, they can also be placed on a soft cushion with the blade facing up.

The remaining instruments are stored either in the nests of the stands, or in branded boxes on foam rubber, or unfolded in a cabinet, without touching each other. Instruments must not be kept on glass or metal. They must not be stored in an undried state, or thrown away during processing and operation.

After purulent operations, the instruments are first disinfected in a 2% solution of carbolic acid for 30 minutes, then washed with running water and kept for 60 minutes under a quartz lamp.

Another method can be recommended. The instruments used in the purulent operation are thoroughly washed in warm running water after its completion, after

which they are poured with a 5% solution of lysol for 10-15 minutes.

Then, the instruments are washed with distilled water and subjected to double sterilization by any method.

If the patient has a history of Botkin's disease, the instruments should be immersed in a cleaning solution for 30 minutes, then washed with water and boiled for 45 minutes, starting from the moment the water begins to boil.

Next, sterilization is performed with dry hot air at a temperature of 180° for 60 minutes.

Sharpening of ophthalmic surgical instruments is performed either manually or electrolytically using the EZI-Z device (Fig. 77) and a special electrolyte.



***Fig.* 77. Device for sharpening surgical instruments**

The electrolyte contains orthophosphoric acid and chromic anhydride in the following weight percentages (orthophosphoric acid - 73-74%, chromic anhydride 9-10%, water 15-16%). The electrolyte should be prepared in a wide glass or enamel container. Since the dissolution of chromic anhydride in orthophosphoric acid is slow, it is recommended to take an acid with a specific gravity of no more than 1.0. Water must then be removed from it by evaporation.

The vessel is loaded with 170 g of crushed chromic anhydride and 1044 ml of orthophosphoric acid. The contents are heated for several hours at a temperature of 70°-90°C until the chromic anhydride crystals are completely dissolved and excess water is removed. Heating and evaporation are stopped when the solution at a temperature of 20°C has a specific gravity of 1.72 (at a temperature of 70°C - 1.65).

The specific gravity is determined with a hydrometer in a glass cylinder (a hydrometer is a device for measuring the density of liquids and solids).

The total weight of the electrolyte in the bath should be 1.72 kg (chromic anhydride 0.17 kg, orthophosphoric acid 1.27 kg, water 0.28 kg). The service life of the electrolyte is 250-300 hours of operation per 1 liter of electrolyte. Based on this characteristic, 15 thousand medium-sized scalpels can be sharpened in the same electrolyte.

The spent electrolyte has a dark green color, is viscous, and is difficult to wash off from the tools. The rules for sharpening tools are as follows: unscrew the screws, remove the lid from the bath, set the potentiometer handle to the extreme left position, insert the thermal contactor into the bracket and include it in the circuit of the device by inserting the pins into the sockets of the panel. The thermal contactor should be lowered into the electrolyte by 10-15 mm.

Next, on the control panel, press the "Heating" button (the "EZI-Z" sign will light up on the wall of the device). A thermometer should be inserted into the bath, performing the sharpening procedure under temperature control. Sharpening should only begin at a temperature of 70 h = 5°C. At the same time, a green lamp on the panel lights up. By turning the handwheel of the feed mechanism to the right, the fixed cutting tool is immersed in the electrolyte, but with the calculation that only the cutting edge is immersed. After this, the button on the panel with the "Sharpening" sign is turned on, and a red signal lamp lights up.

Using the potentiometer knob, set the required operating mode (a current of 0.5 A is recommended). Sharpening of the tool is performed by slowly rotating the handwheel of the lifting mechanism until the sharpened tool is completely removed from the electrolyte within 5-6 seconds. The procedure is repeated 2-3 times. Then the sharpened tool is washed in a stream of cold water. After sharpening is complete, the device must be disconnected from the electrical network.

Microsurgical needles

Needles and suture materials play a major role in microsurgery. Needles can be characterized by several parameters, in particular by the eye. Needles with a kerf eye (cut eye for multiple thread loading) accepted in general surgery and for many years in ophthalmology are unacceptable in microsurgical technique.

In microsurgery, needles with a continuous "granny" eye of reusable use are more justified. They are free from the above-mentioned shortcomings. The highest quality needles are single-use needles (without an eye) with a thread fixed in the posterior section of the needle. These are the so-called atraumatic needles that do not require reloading the thread. With a thread length of 30 cm, it is enough

to apply approximately 30 interrupted sutures.

By the nature of the action, needles are divided into piercing and cutting. The former has a conical point and a round cross-section.

They are easily pricked into tissue, but the advancement of such needles, especially in dense tissues, in particular in the cornea or sclera, is very difficult. This is due to the fact that the needle creates a channel for the suture by moving apart (and not cutting) the tissue. Therefore, in microsurgery, preference should be given to cutting needles.

They have a point for injection, which immediately passes into the body of the needle with cutting edges, which determines the profile of the needle cross-section. It can be in the form of a triangle (type A), or a trapezoid (type B, Fig. 78).

The latter cross-section is more convenient to work with. In addition to the specified parameters, microsurgical needles are characterized by length (from 4 to 9 mm) and curvature (7 g, 74.3 / in circumference). In the absence of the specified micro-needles produced by foreign companies, microsurgical needles can be prepared by your own efforts.



Fig. 78. **Microsurgical needles**
Microsurgical needles with eyes:
a) Triangular cross-section profile;
b) Trapezoidal cross-section profile;
c) General view of the needle

To do this, according to the suggestion of V.G.Shilyaev (1979), you should take a round needle for suturing vessels, shorten it by half and grind it on a dental grinding machine from the concave and convex sides. After such processing, the needle will become flat, saber-shaped, and its end will be sharpened. The needles are disinfected (as well as other cutting microsurgical instruments, in particular, razor blades) in 96° alcohol for an hour. To avoid losing the needles, they should be stuck into gauze napkins.

Microsurgical suture materials

Silk, synthetic fibers, biological threads, and hair can be used as suture material in microsurgery. Each material has its own advantages and disadvantages. Silk is the most popular among ophthalmologists since it is elastic, easy to work with, ties well into a knot, and does not cause a significant reaction in the tissues of the eye.

Microsurgical silk is made from the cocoon of the mulberry silkworm. The cocoon threads in the amount of 3-7 fibers are glued into bundles (without twisting), dyed blue or black. This silk, known under the names: virgin silk, Barraquer silk, Virginia silk, is produced by foreign companies in spools of 280 m (Fig. 79) with indexes 8U0, 10/0.

The index in the form of zeros characterizes the strength of the silk thread, its resistance to tearing and corresponds to a certain diameter of the thread. Naturally, the thicker the thread, the stronger and more resistant it is to tearing. Silk 8/0 corresponds to a thread diameter of 0.045 mm, and silk 10/0 has a diameter of 0.015 mm. At the Turkmen Research Institute of Eye Diseases, N.N.Nurmamedov and I.A.Mustayev developed a method for producing domestic microsurgical silk (1979). The fibrin threads of the white cocoon of the mulberry silkworm are connected to each other by a sticky substance - sericin, which is produced by the caterpillar.



Fig. 79. **Microsurgical silk**

The authors created microsurgical threads of 15 microns (from 3 cocoon threads).

They are most optimal for suturing wounds of the iris. For the cornea and sclera, threads of 25 microns (from 5 cocoon threads) were created. For working with the same tissues, threads of 8 fibrin cocoon threads of 40 microns thick were created, and, finally, threads of 60 microns (from 12 Cocoon threads). The authors conducted a comparative assessment of Turkmen silk with virgin silk in terms of thickness, tensile strength, elasticity, hygroscopicity, proving the advantages of domestic silk. Sterilization of this microsurgical silk is special. The threads are wound on bushings or glass rods of 50, 100 and 150 m and immersed in absolute alcohol for three days.

The threads are then stored in the same absolute alcohol. Since the strength of the silk may decrease with prolonged exposure to alcohol, it should not be processed (wound on bushings) in too large quantities. Washing microsurgical silk in water and boiling it, as is customary in general ophthalmic surgery, is not allowed, since sericin is soluble in water (as well as in aqueous solutions of alkaline and acids). In recent years, many ophthalmologists have had the opportunity to use natural Moldovan first-class, selected silk, proposed for microsurgery by F.I.Gizu, I.F.Bobu, O.L.Dvoretskaya.

The silk thread consists of five elementary cocoon threads, glued with natural glue-serin, has a diameter of 8/0-10/0 and meets world standards. Silk is sterilized in 96% alcohol for three days. To make it easier to work with this suture material, the authors recommend slightly tinting it by adding a 1% solution of brilliant green to the alcohol where the threads are stored.

If the surgeon does not have a special microsilk at his disposal, the situation can be solved in the following way. You should take ordinary twisted surgical silk 1/0 or 2/0 and unravel the main thread into its components.

Microsutures left under the conjunctiva do not cause a tissue reaction, are encapsulated and are not removed. Silk should be removed after the corneal wounds have healed. Threads made of artificial fiber (supramid, nylon, capron) differ from silk in their considerable strength and the very advantageous circumstance of the absence of a biological reaction from the eye tissues.

The disadvantage is the increased elasticity of the thread, which leads to the risk of the sutures coming untied, as well as the rigidity of the ends of the threads,

which, after being cut, irritate the adjacent parts of the eye (the inner surface of the eyelids, especially when blinking). To prevent this, the ends of the suture threads are immersed deep into the fibrous capsule (cornea, sclera) or melted with a thermal cautery. Otherwise, the ends of the threads, in particular those left under the conjunctiva, perforate the latter, causing much discomfort to patients.

Synthetic threads, or as they are called "monofilament", are most often dyed black. They, like silk, have different tensile strengths, and different diameters, according to which they are designated by a certain number of zeros. Synthetic threads threaded into an atraumatic needle (supramid 8/0 with a diameter of 0.05 mm, supramid 10/0 with a diameter of 0.025 mm) are very convenient (Fig. 80).

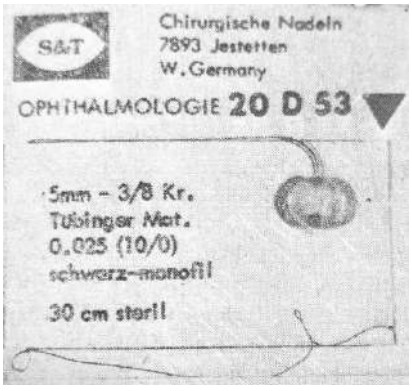

Fig. 80. **Microsurgical atraumatic needle with synthetic thread**

In the absence of the branded threads, nylon threads obtained from various products can be used. Sterilization of threads made from artificial fiber is extremely simple and is achieved by boiling for 20 minutes from the moment the water boils.

Recently, the solution 'pervomur' has gained popularity in ophthalmology for sterilizing suture material (excluding natural silkworm silk), as well as rubber and glass products. With its high bactericidal properties, 'pervomur' not only kills bacteria but also their spores.

The method of sterilizing suture material in the "pervomur" solution is simple. Silk, nylon, lavsan are loosely wound on glass rods or spools and immersed in a 2.4% "pervomur" solution for 2.5 hours.

After this, the material is rinsed in four changes of distilled water and stored in 96° alcohol.

Biological sutures, which are the tendons of the tails of white rats, are produced by the Odessa Plant of Chemical Preparations and Biogenic Stimulants in a package of 10 sterile threads with an indication of the shelf life.

Despite their advantages (satisfactory strength, spontaneous absorption), biothreads have currently yielded their primacy in micro-

surgery to natural silk and artificial fiber.

From experience, it can be concluded that sutures are not always reliable in the event of complications such as prolapse of a large amount of vitreous body, expulsive bleeding. They slide in the tweezers, the suture knot comes undone, not tightly tightening the wound. In addition, in the postoperative period, biological sutures swell, sometimes causing a reaction of the cornea in the form of edema, up to the formation of epithelial blisters, melting of the tissue around the suture.

The diameter of the biothread cross-section is never thinner than 6/0-5/0.

Anti-infection measures. The issue of postoperative infection in the conditions of microsurgery, when the performance of operations is to a certain extent extended in time, should be subject to special analysis.

The entire system of operation of the microsurgical operating unit serves to prevent infection (see above). The operating day ends with a wet cleaning of all rooms. Use a solution of lysol at the rate of two tablespoons per bucket of water. For washing, you can take water with the addition of a 10% solution of ammonia. After wet cleaning, the room is quartzized (bactericidal lamps are turned on). In the morning before the start of the operating day, the floor is wiped with a solution of bleach. Take 1 glass of bleach powder, dissolve it in ½ water, insist for a day and filter. Then this concentrate is diluted with 10 liters of water. The resulting solution is used for wet cleaning. It ends with the quartzization of the operating room. Twice a month, a laboratory assistant collects material for sowing on meat broth with the addition of 1% glucose (sugar broth).

A sterile swab soaked in distilled water is used to wash off the sterile hands of the surgeon and operating room nurse. The swabs are brought from the laboratory in sterile sealed test tubes, just like the sugar broth.

Instruments, needles, suture material, and material for drying the surgical field are checked for sterility by dipping them directly into test tubes with sugar broth. Bacteriological control of eye drops and air is performed. The nutrient medium with the collected material is placed in a thermostat for 48 hours, after which, by making transfers to dense nutrient media, the microbial flora is determined.

A mandatory and strict condition for the operation of a microsurgical operating room is the prohibition of using its premises for radiation (laser) effects and interventions on infected tissues. In addition to the above measures, the infection prevention system includes local administration of antibiotics after all abdominal operations (naturally, in the absence of contraindications) according to the scheme given below.

Chapter 2

BASIC PRINCIPLES OF MICROSURGICAL INTERVENTIONS

Elements of deontology in microsurgery. The outcome of surgical intervention depends on many factors. Among them, we attach great importance to the element of deontology. It would be correct to say that the stage of surgery does not begin at the moment of manual action, but long before it. The process of surgery, as such, should be preceded by a period of surgical thinking about how, in what most rational way to fulfill the surgeon's duty. This thesis is especially significant at present, when, possessing microsurgical technique, the doctor has the opportunity to choose for each patient the type of pathogenetically oriented surgical intervention shown specifically to him, in particular in primary glaucoma. Having summarized the data of the preliminary examination of the patient, the surgeon performs this important deontological moment. The surgeon's deontological mission is also manifested in the creation of psychological contact between him and the patient, which is especially necessary before the operation.

We are deeply convinced that an operation (of course, if it is not urgent) should be preceded by repeated conversations with the patient, in which the surgeon is obliged to tell him in a manner understandable to the patient about the disease that has arisen, about the purpose of the upcoming surgical intervention and about the final expected result. At the same time, the doctor should instill in the patient cheerfulness, faith in the success of the upcoming operation. The patient should believe the surgeon and trust him. And if, as is usually the case, the patient addresses the doctor by name and country, then why shouldn't the doctor make it a rule to address the patient in the same manner. We know from experience how it al-

ienates people from the doctor and what sometimes insurmountable barriers to contact are created by addressing them by their last name or by addressing them in the form of the standard word: "patient".

In deontology, everything matters: the doctor's appearance, the intonation of his voice, and the trusting touch of his hand. These are elements that undoubtedly influence the success of treatment.

The surgeon should carry out the final check of the patient's condition before sending him to the operating room. This includes measuring body temperature and blood pressure. Blood and urine tests should be checked again, the patency of the lacrimal ducts should be ensured, and the quality of the eyelash trimming performed the day before should be checked. The conjunctival cavity should be examined without fail, and at the slightest sign of an inflammatory process, the bacterial flora should be urgently examined (smear, conjunctival scraping, and, if necessary, discharge culture).

It is also necessary to check the correctness of the marking of the eye to be operated on. Such marking is absolutely necessary if the operating unit works with a daily heavy workload, calculated in several dozen surgical interventions, and one surgeon performs up to 5-6 operations. Marking consists of applying a mark to the skin in the eyebrow area of the eye to be operated on using a solution of brilliant green. This eliminates unnecessary further contacts between the operating unit personnel and the patient, in particular the traditional question about which eye (right or left) is to be operated on. It should also be taken into account that the patient is already under the influence of the drug preparation, and his answer may disorient the personnel.

In our opinion, the issue of obtaining the patient’s consent to surgery in the form of a receipt before the operation is quite complex. To our knowledge, there are no official legal regulations regarding this matter for adult patients. In some research institutes where new types of surgical interventions are being developed, some of which are being performed for the first time, patients provide consent through a receipt that also outlines possible complications. However, in general ophthalmic surgical practice, where proven microsurgical techniques are used, this approach is unacceptable due to its negative impact on the patient's psyche. We believe it is appropriate to obtain a receipt only when performing procedures

of a more radical nature (such as enucleation, evisceration of the eye, or exenteration of the orbit), with the necessity of the intervention clearly explained in the document. Given the advanced age of many patients, it is also advisable to hold a preliminary meeting with close relatives to explain the current medical situation.

Preparation for surgery, premedication, narcosis, and anesthesia. Great importance in ophthalmic surgery, and especially in microsurgical practice, should be given to a well-thought-out preoperative preparation of the patient and the pain relief system.

This stage in the complex of microsurgical intervention is especially necessary for several reasons. Microsurgical operation is known to be longer in time; during operations performed under a microscope, absolute immobility of the patient's eye (and therefore the head and the whole body) is necessary.

This can be achieved only by using a complex of potentiated pain relief, which ensures the calm behavior of the patient in the preoperative period and during the operation, contributes to a smoother course of the surgical intervention itself, reduces the risk of surgical and postoperative complications.

We consider it necessary (as is customary in our own practical work) to create, by means of medicinal influences and "influence by words", such a psychological mood in the patient that turns the act of surgical intervention into a necessary, but by no means tragic situation. The patient should not be afraid of the operation. He should not be an opponent, but a reasonable accomplice in what is happening and to a certain extent help the surgeon in his difficult work.

From our point of view, the accepted schemes of preparing the patient for the operation serve the fulfillment of the set goal. Despite the fact that the intervention is carried out in an extremely small anatomical zone, it should be approached from a general surgical position. The patient, especially before cavity eye surgeries, should be examined by a therapist (condition of the cardiovascular system, electrocardiography, blood pressure, blood clotting and bleeding time, prothrombin index, blood sugar level in the morning on an empty stomach, which is very important to know, given the frequency of latent diabetes mellitus, predisposing to hemorrhages and infection).

The therapist should also give an opinion on the condition of the respiratory system, gastrointestinal tract, and kidneys.

Elderly men with dysuric disorders should see a urologist before surgery since such patients often have hypertrophy of the prostate gland. This can complicate the course of the postoperative period due to the need for catheterization of the bladder due to the impossibility of its independent emptying.

In our practice, there have been observations when cystitis and even pyelitis developed in such cases, which necessitated the transfer of the operated patient to the urology department. To prevent possible odontogenic infection, the patient should be examined by a dentist before surgery.

Particular attention should be paid to identifying possible intolerance to drugs (antibiotics, sulfonamides, anesthetics, and first of all, dicaine, novocaine).

This is necessary for the timely replacement of the drug causing an allergic reaction with its analogue. In doubtful cases, we are inclined to recommend, as is done in practice, the instillation of a medication, for example, the same dicaine, into a healthy eye or intradermal administration of a drug (antibiotic, novocaine) into the forearm, which makes it possible to judge their tolerance.

The data obtained from preliminary examinations of the patient allow us to develop an individual scheme for managing the preoperative and postoperative periods, and to select a method of anesthetic care. Currently, in many operations with opening the eyeball (cavity operations), especially with increased intraocular pressure, hyperosmic agents are used to prevent hemorrhages, vitreous prolapse, and choroidal detachment.

They increase the osmotic pressure of the blood, which leads to dehydration of the eye tissues and improved outflow of intraocular fluid. As a result, the surgeon performs the intervention against the background of reduced intraocular pressure (about 15 mm Hg).

This factor is the prevention of possible complications, especially in antiglaucoma operations, when complications in some cases are a consequence of a sharp decrease (drop) in intraocular pressure.

The most popular and safest in terms of possible undesirable consequences is a hyperosmic drug - glycerol. Recently, many have begun to prefer glyceryl ascorbate to glycerol, which has poor taste tolerance. It consists of glycerin, which is prescribed at a rate of 1.5 g

per 1 kg of the patient's weight, ascorbic acid at a dose of 0.1 g per 1 kg of the patient's weight, and 20-25 g of any fruit syrup. Such a cooled mixture does not have an unpleasant taste and is usually well tolerated, only occasionally causing a feeling of heaviness in the epigastric region or a feeling of nausea. There are usually no contraindications for prescribing glycerol (glyceryl ascorbate), with the exception of diabetes mellitus.

The category of drugs that reduce intraocular pressure and thereby prevent some surgical complications includes diacarb, which has the ability to inhibit carbonic anhydrase of the ciliary body, which leads to a decrease in the production of intraocular fluid by the ciliary body, as well as an improvement in its outflow.

Therefore, diacarb, like glyceryl ascorbate, is included in all existing schemes of preoperative preparation of patients in ophthalmic surgery. Contraindications to the prescription of the drug are diabetes mellitus, kidney and liver diseases.

The conditions of microsurgical surgical interventions have increased the requirements for premedication of the patient and anesthetic care. Pain relief issues should be addressed jointly with the anesthesiologist, who must examine the patient the day before and on the day of the operation. Local anesthesia relieves pain, but it cannot ensure complete patient calm on the operating table, and cannot eliminate adverse reactions from the cardiovascular and respiratory systems. This is all the more dangerous since surgical interventions are mainly performed on elderly people, whose medical history is often burdened with general somatic pathology.

Taking the above into account, anesthesiologist S.S.Khadyshyan (1976) developed and tested a premedication and anesthesia protocol for eye microsurgery on a large clinical sample. This protocol meets the specific requirements for interventions under a microscope on the delicate anatomical structures of the eye. It includes effective analgesia, reduction of intraocular pressure, prevention of pressure increases at any phase of the operation, stabilization of both general and local hemodynamics, and prevention of complications such as vomiting, vitreous body prolapse, and expulsive hemorrhage. Great importance is attached to premedication, with the help of which neuroendocrine shifts are blocked, cardiovascular activity is normalized, which preserves the body's reserve

forces and creates a state of mental peace.

The proposed scheme includes the administration of a long-acting hypnotic (luminal 0.1) in combination with tranquilizers (meprobamate 0.2) and antihistamines (diphenhydramine 0.1) the day before the operation. Half an hour before the operation, the patient is given narcotic analgesics (promedol 1% - 1.0), neuroleptics (droperidol 2-3 ml), ataractics (seduxen 0.5% - 1.0), as well as antihistamines (diphenhydramine 1% - 1.5) intramuscularly. The patient should be taken to the operating room on a gurney. Here the anesthesiologist performs induction, including a combination of three drugs (intravenous administration of droperidol at a rate of 0.2 mg per 1 kg of the patient's weight, administration of fentanyl 0.05-0.1 mg, seduxen at a rate of 0.4 mg per 1 kg of the patient's weight). After the patient is put to sleep, he is given local anesthesia, which no longer causes any oculocardiac reflex. Anesthesia is maintained by repeated administrations of fentanyl and seduxen in dosages of the drugs depending on the patient's age.

Perhaps, in the conditions of a small eye department of a district hospital, it will not be possible to carry out such anesthesia, which requires the presence of an anesthesiologist. In this case, we can recommend a simpler scheme of premedication and analgesia, which we use at the Moscow Ophthalmological Order of the Red Banner of Labor Clinical Hospital, especially when operating on patients with an acute attack of primary or secondary glaucoma against the background of high blood pressure, where the risk factor doubles.

The night before and in the morning on the day of the operation, the patient takes 0.05 g of diphenhydramine, 0.01 g of seduxen, 0.25 g of diacarb and 150 ml of glycerol (glyceryl ascorbate) orally. An hour before the operation, a lytic mixture of 1 ml of a 2% solution of promedol and 1 ml of a 1% solution of diphenhydramine is administered intramuscularly. On the operating table, before the start of the surgical intervention, the patient is given droperidol 2.5-7.5 mg intravenously in combination with fentanyl 0.05-0.15 mg.

After this, muscle relaxation and a drowsy state occur in 2 minutes. The effect lasts for about half an hour and completely disappears after 3-4 hours. Such neuroleptic analgesia reduces arterial and intraocular pressure, prevents vomiting and vitreous loss. Natu-

rally, analgesia is combined with conventional local anesthesia.

The full range of measures implemented allows for the increasingly widespread use of combined microsurgical interventions to be performed with reduced risk. This includes, for example, antiglaucoma surgery such as septal trabeculectomy in combination with cataract extraction.

Only after completing all, one can say, "ritual actions" before sending the patient to the operating room, the operator can begin to perform his duties in the operating block.

For the sake of the cause, the microsurgeon is obliged to get used to some self-restraints, remembering that before the beginning of the operating day, he should not lift heavy objects, should not take drugs that excite the nervous system, should avoid mental overstrain and negative emotions. All this can affect the course of the operation, lead to the appearance of involuntary tremors of the fingers, quite noticeable under the microscope, nervousness when complications arise. Before the start of the operation, the surgeon takes off his suit and puts on surgical pajamas, which he should only wear in the operating room. He puts on shoe covers on his feet, and a surgical mask on his face and head. After this, he should prepare the microsurgical equipment for the operation and create the necessary comforts for himself, which will contribute to a better performance of the surgical intervention.

First of all, after sitting in the operating chair or on a stool, he should adapt himself in relation to the operating table in height, having tested the supports for the forearms of the hands, which should be located flush with the operating field.

The surgeon's body and hands must be comfortable and stable, otherwise, any change, for example, a hand slipping while working under the magnification of an operating microscope, especially during the cutting of eye tissue, may lead to irreparable consequences. It is necessary to properly adjust the operating microscope (see above) and install its lens over the eye being operated on, choosing the magnification necessary for the intended purposes. Only after this should you return to the preoperative room and begin sterilizing your hands, instructing the operating nurse to prepare the surgical field.

At the same time, the anesthesiologist (see above) also gets involved in the work so that by the

time the surgeon returns to the operating room (after sterilizing his hands), the patient is fully prepared for the upcoming intervention.

The work of the operating nurse is reduced to the performance of the following elements. She must ensure that the patient is comfortably positioned on the operating table and that nothing interferes with him. It would seem that such trifles as a comb and hairpins in women's hair should be removed. It is also necessary to check whether dentures have been removed. All this should be checked before the patient enters the operating room, but a repeated check performed here will not cause harm.

The patient is transferred from the gurney to the operating table, covered with a sterile sheet (up to the head), after which the skin is treated. It is wiped with a mixture of 96% alcohol and ether (in equal quantities), then wiped with a swab soaked in a mixture of 5% iodine tincture, alcohol and glycerin, also in equal quantities.

Skin treatment begins with the eyelids and then extends to the forehead, temple, nose, and cheek. We prefer to lubricate the skin of the entire half of the face with the solutions indicated above, corresponding to the eye being operated on, paying attention to disinfecting all skin folds and wrinkles, and the eyebrow area.

Naturally, before skin treatment, a dicaine solution should be dripped into the eye several times to eliminate unpleasant sensations associated with possible alcohol, ether, and iodine getting into the conjunctival cavity.

With this in mind, the nurse should wipe the skin of the face with a slightly wrung-out swab. After treating the skin and drying it with a sterile gauze napkin, a 1% solution of dicaine, a 30% solution of sodium sulfacyl, and a 3% solution of collargol are instilled into the conjunctival cavity in this order. Next, the conjunctival sac is washed abundantly with cooled saline. After this, the surgical drape is pulled over the patient's head and fixed to the back of his head with a pean. A fairly wide surgical mask with an opening corresponding to the eye being operated on is thrown over the drape (see above).

The final touch in preparing the surgical field is to lubricate the intermarginal space of the eyelids, the lacrimal point and the skin of the eyelids with a 1% solution of brilliant green. We assign this responsibility to the assistant.

After sterilizing the hands and dressing in a sterile gown, the sur-

geon (already under general anesthesia or general anesthesia) begins to administer local anesthesia. It was started beforehand by the operating nurse in the form of the instillation of a 1% solution of dicaine into the eye (in the case of intolerance, a 1% solution of trimecaine, 1% solution of lidocaine are used). The surgeon or his assistant connects an application element to this instillation anesthesia, which consists of the fact that a cotton wick soaked in a solution of dicaine (trimecaine, lidocaine) is placed in the upper conjunctival fornix, calculating the effect on the place of attachment to the sclera of the superior rectus muscle. When performing the procedure, care must be taken to ensure that the wick does not shift to the cornea.

We are deeply convinced that subsequent infiltration-conduction anesthesia should be performed personally by the surgeon, and not by his assistant since the quality of the microsurgical intervention largely depends on the quality of the anesthesia performed. Complete anesthesia of the eyeball and complete akinesia of the eyelids should be considered a law of microsurgery. Since motor nerves are somewhat less amenable to blockade by anesthetics compared to sensory nerves, there is every reason to first perform akinesia of the eyelids.

In contrast to generally accepted guidelines, when performing the procedure of conductive akinesia, which switches off the upper branch of the facial nerve, innervating the orbicularis muscle of the eyelids, we recommend the introduction of a significant amount of a 1% solution of novocaine, trimecaine, lidocaine (up to 20-25 ml), creating from one injection an infiltration shaft in the form of a horseshoe along the upper-outer and lower-outer edges of the bony orbit with subsequent direction of the needle, without puncturing it, laterally downwards, to the area of the tragus of the ear (Fig. 81). This also achieves an effect on the main trunk of the facial nerve.



Fig. 81. **Akinesia of the orbicularis muscle of the eyelids**

This also affects the main trunk of the facial nerve. When novocaine is injected to the proper depth, spe-

cifically to the periosteum, it induces reliable akinesia, which—when combined with general anesthesia—allows for completely calm microsurgical interventions on the eyeball, without the need for an eyelid speculum. However, when performing akinesia, it is important to ensure that novocaine does not spread into the thickness of the eyelids, as this could lead to unwanted compression of the eyeball.

All cavity microsurgical interventions on the eyeball should be performed against the background of ganglion retrobulbar anesthesia, which turns off the ciliary ganglion, sensitive long ciliary nerves, as well as short ciliary nerves of mixed type emerging from the ciliary ganglion.

When retrobulbar anesthesia is performed correctly by injecting 1.5 ml of a 2% solution of novocaine into the anterior sections of the intramuscular funnel, innervation of the external muscles of the eyeball is also switched off.

Retrobulbar anesthesia results in total ophthalmoplegia, the signs of which are ptosis of the upper eyelid, loss of sensitivity, mydriasis, and lack of mobility of the eyeball.

In this case, the doctor should not be confused by the fact that the ability to move the eye downwards usually remains intact. This occurs due to the fact that the trochlear nerve and the superior oblique muscle innervated by it are switched off from action, due to the peculiarities of their anatomical location, much later.

In an effort to induce good anesthesia, the microsurgeon should not get carried away with the retrobulbar administration of significant quantities of novocaine (about 2.0 - 3.0 ml). This can lead to excessive mechanical pressure on the eyeball from behind and cause prolapse of the vitreous body.

When performing a seemingly simple procedure of retrobulbar anesthesia, even very experienced ophthalmic surgeons may experience complications. The most common of these is a retrobulbar hematoma, which occurs literally "on the needle", that is, immediately after the syringe needle is removed from the orbital cavity. The appearance of increasing exophthalmos on the eyes, the density of the eyelids, tightly covering the eyeball, the conjunctiva and eyelid tissues being soaked with blood - all these are signs of a retrobulbar hemorrhage. It may occur as a result of damage to one of the fairly large branches of the ophthalmic artery by the syringe needle. With the correct performance of the

retrobulbar anesthesia procedure and the introduction of novocaine into the anterior parts of the muscular funnel, this complication almost never occurs.

However, if the syringe needle penetrates too deeply into the muscular cone, where the ophthalmic artery lies between the external rectus muscle of the eye and the optic nerve, one of the vessels may be injured. In this case, surgical intervention on the eyeball must be canceled. The patient should be given 10.0 ml of a 10% calcium chloride solution intravenously; if there are no contraindications, 1.0 ml of a 1% vicasol solution is administered. A pressure bandage is then applied to the orbital area, with a rubber bag containing ice fixed in place. The patient is transported to the department on a gurney. After the hematoma has resolved in 5-7 days, usually without discharging the patient from the hospital, so as not to cause him psychological trauma, the planned surgical intervention can be performed.

Another very serious complication that must be remembered when performing retrobulbar anesthesia in the presence of high myopia in a patient is a puncture of the true posterior staphyloma of the sclera with a syringe needle. This can happen when inserting the syringe needle into the area of the lower-outer quadrant of the orbit, if the patient has not actively enough diverted the eyeball inward - upward.

The hypotension that occurs will be a signal of what has happened. However, if novocaine is injected into the cavity of the eyeball, there may be no hypotension. Even hypertensive syndrome may occur. In this situation, there is nothing left to do but cancel the planned operation and, having applied a bandage, send the patient on a gurney to the department with a recommendation to observe bed rest for several days.

Based on the above, our students of the advanced training courses are advised to perform retrobulbar anesthesia for high axial myopia in the zone of the lower-inner (upper-inner) quadrants of the orbit.

In my own practice, this has proven itself when it was necessary to perform abdominal surgeries for myopia of 30.0 D and higher.

Local preparatory manipulations. After akinesia and retrobulbar anesthesia, a manipulation of applying a ligature to the superior rectus muscle follows. This seemingly elementary procedure for an ophthalmic surgeon requires cer-

tain explanations for the sake of correct execution. Observing the work of surgeons, I have often had to be convinced that the ligature is applied too superficially (the muscle, especially if the muscle is flattened on the sclera, slips out of the fixing tweezers); between its branches there remains only a fold of the conjunctiva and Tenon's capsule. In this case, the ligature does not provide proper fixation of the eyeball and its downward abduction. To avoid this error, use curved microsurgical tweezers, a regular small surgical cutting needle, a finger needle holder, and 4/0 silk thread.

When closing the tweezers, spread apart to a width of 5 mm and placed perpendicularly (but not obliquely!) to the surface of the eyeball 8 mm from the limbus (corresponding to the attachment point of the superior rectus muscle to the sclera), it is necessary to grasp the conjunctiva, Tenon's membrane, and muscle tendon. When moving the tweezers to the sides, make sure that it is the muscle that is grasped.

This will be evidenced by the fact of active movement of the eyeball together with the tweezers. Next comes the stage of suturing the rectus muscle itself with a needle. This should be done not in the zone of its capture, that is, under the fixing tweezers, but 2-3 mm higher for the reason that the belly of the muscle should be sutured, but not its tendon (Fig. 82). When suturing the tendon, the eye is usually not sufficiently retracted downwards, and when the ligature is pulled, a gaping limbal wound occurs (for example, during cataract extraction surgery), deformation of the sclera, which can increase intraocular pressure. To suture the muscle, the needle should be immediately moved from the vertical position during injection to a position parallel to the surface of the eyeball. While advancing the needle in the indicated direction, do not rush to remove it without making sure that the needle is being passed through the muscle and not through Tenon's capsule. If the upward displacement of the needle located in the tissue is difficult, this indicates that it is located in the thickness of the superior rectus muscle, and therefore can be advanced further and punctured. Such a sequence of manipulations excludes repeated unsuccessful ligation of the superior rectus muscle, as happens in practice. In order to carry out this procedure with greater ease, the assistant should help the surgeon by moving the upper eyelid with an eyelid lifter

and at the same time turning the eye downwards by pressing the muscle hook on the area of the inferior conjunctival fornix.

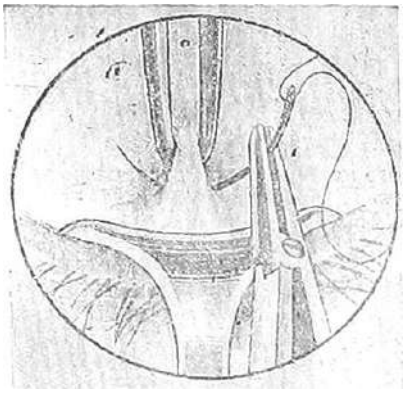

Fig. 82. **Ligature application to the superior rectus muscle of the eye**

The surgeon must be vigilant when performing this procedure. Damage to the muscle vessels may occur, which will cause hemorrhage into the Tenon capsule and conjunctiva.

By pressing the ligature site with a tampon, the bleeding can be easily stopped. The ligature should not be removed, and after a few minutes, the subsequent planned elements of preparation for the operation can be performed. A more serious complication that can arise when applying a ligature to a muscle is a puncture or even suturing of the sclera and choroid. This occurs in the presence of a thin sclera, a weak superior rectus muscle in combination with pronounced preoperative hypotonia of the eyeball, when the surgeon, thinking that he is fixing the muscle, grabs the fold of the sclera along with it and suturing it. The appearance of swelling of the conjunctiva at the site of the ligature, in parallel with the increase in hypotension, are the symptoms that indicate a complication has arisen. In this case, the ligature, naturally, should be cut off, and the planned operation postponed. The patient is transported to the department, and prescribed bed rest for several days (to avoid detachment of the retinal membrane). In this case, we consider any urgent surgical measures to be unnecessary: the hole in the sclera from the puncture with a needle is tamponed with adjacent tissues. However, the application of episcleral sutures, a bio-seal over the hole cannot raise objections.

The ligature placed on the superior rectus muscle not only fixes the eyeball but also retracts and fixes the upper eyelid well, which allows one to do without an eyelid speculum. However, the lower eyelid must be retracted and fixed. This is easily achieved by placing a fixed silk suture on it. The suture, in order to avoid possible bleeding

from the marginal arterial arch of the eyelid, should be carried out below the location of this arch, that is, 3-4 mm from the edge of the eyelid. For greater certainty of fixation, the superficial layers of the orbicularis muscle are also stitched.

If the surgeon considers the opening of the palpebral slit insufficient, it should be increased by canthotomy. After applying a clamp to the area of the external commissure of the eyelids for 30 seconds to exsanguinate the tissue, the tissue should be cut with one movement of straight blunt scissors up to the orbital edge. The preparatory measures are not limited to the actions described above.

Many surgeons (and this is really justified) massage the eyeball before an abdominal operation to reduce intraocular pressure. The massage should be done only after the frenulum suture has been applied to the superior rectus muscle, so as not to cause complications (see above) that may arise during manipulations on a significantly hypotonic eyeball. It is preferable to massage not by continuous (sometimes instrumental) compression, but by moderate intermittent pressure on the eyeball with the fingers of both hands of the surgeon for 4-5 minutes. Since the massage is performed through closed eyelids, naturally, the mechanical force applied will cause emptying of the accessory lacrimal and mucous glands located in the conjunctival cavity, and especially the meibomian glands of the cartilage. Therefore, in order to free the conjunctival cavity from mucus, sebum-like secretion of the meibomian glands and maintain its sterility, after the massage it is necessary to thoroughly rinse the entire conjunctival sac with a physiological solution, followed by additional instillation of sodium sulfacyl and disinfection of the intermarginal space and skin of the eyelids with a 1% alcohol solution of brilliant green. In extensive microsurgical interventions, which are fraught with disruption of the framework function of the outer capsule of the eye due to the loss of a large amount of vitreous body, deformation and collapse of the eyeball, it is necessary to pre-suture a metal ring, preferably a double one, which takes on the functions of the framework and maintains the shape of the eyeball when its contents are lost (Fig. 83).

The ring is usually sutured with four sutures to the episclera in

the oblique meridians of the eye, using a sharply bent needle, with the calculation that the puncture and puncture of the needle are located near the ring (Fig. 84).

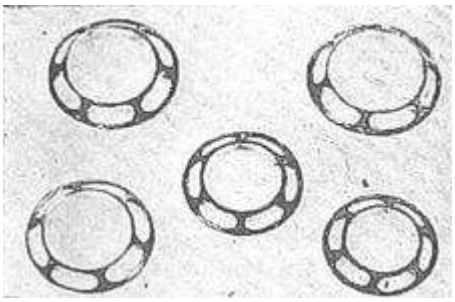

Fig. 83. **Set of frame eye rings of domestic production**

Otherwise (with a distant puncture and puncture of the needle), tightening the suture will bury the ring in the fold of the sclera.

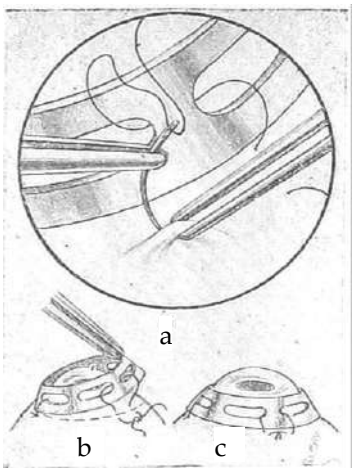

Fig. 84. **Stages of suturing the frame ring to the episclera (a, b, c)**

New skills of a microsurgeon.

In order for the practitioner in the role of microsurgeon to regain the comfort in work, calmness and confidence so necessary for the success of surgical intervention, we consider it necessary to acquaint him with fundamentally new provisions and rules of work, which should be mastered as soon as possible. The microsurgeon must get used to the fact that the operation is performed by him only in a sitting position, practically in one position, without changing the position of the body.

Therefore, if the chair is incorrectly adjusted to the operating table and the surgeon is not seated correctly, fatigue will very quickly appear due to the tense (too extended or bent) position of the back and neck. That is why, when preparing for an operation, you should not spare time for preliminary adaptation to the chair and operating table.

The surgeon must adjust to the new 'eye-hand' setup. In conventional ophthalmosurgery, the entire distance from the eye to the hand, fingers, instrument, and its working ends was clearly visible, allowing movements to be made with the shoulder, elbow, and other smaller joints. However, when

working under a microscope, the surgeon only sees the working parts of the instruments and must operate them without having visual control over the movements of the fingers holding the instruments or the instruments themselves. It is crucial to immediately adapt to the fact that the right hand holds the primary (cutting and piercing) instrument, while the left hand holds the auxiliary (fixing) instrument.

The process of introducing an instrument into the brightly illuminated surgical field (in the field of view of the microscope) can be divided into three periods. The first of these, the macroscopic period, consists of quickly bringing the instrument to the edge of the illuminated field directly under the control of the eye (without looking into the microscope). The second period, called the "transition scotoma", consists of slowly and carefully introducing the instrument into the surgical field. At this point, the doctor switches his vision to the surgical field under the microscope and loses visual control of the instrument for a few seconds. This is the transition scotoma. It is followed by the microscopic period of observing the instrument through the microscope. It is characterized by a clear slowness of the movements of the fingers holding the instrument and a very small amplitude of these movements, which will be discussed below.

It should be noted that multiple changes in the working position from the “eye-hand” position to the “eye-working end of the instrument” position during surgical intervention are quite difficult.

In this case, the operation time is extended, and a continuous change in accommodation occurs. As for surgeons with refractive ametropia or presbyopia, whose vision correction has been previously performed using the optical capabilities of the microscope eyepieces, it is practically very difficult and unsafe for them to carry out the macroscopic period of grasping an instrument, for example, a blade holder with a razor fragment, and quickly approaching it to the illuminated surgical field. Therefore, in our work, we completely exclude both the macroscopic period and the transition scotoma, preferring to work without taking our eyes off the microscope eyepieces, that is, at a certain stable accommodation voltage. In this case, the operating nurse, in accordance with the surgeon's requirement, places the necessary instrument in his hands, and the working end of

the instrument immediately appears in the surgeon's field of vision. Here, an important role belongs to the assistant. Sometimes he must not only give and take the instrument from the surgeon but also help insert and remove its working ends from the microscope's field of view. The assistant must control the movements of the surgeon's hands, without interfering with him or blocking the microscope's field of view.

Particular attention should be paid to the feeding of cutting and piercing instruments (razor blades, needles) to avoid hand injuries. The microsurgeon must get used to performing all surgical movements using three fingers and a hand. The first and second fingers, as mentioned above, hold the instrument, and the third performs an auxiliary function of supporting the instrument.

The surgeon rests his fourth and fifth fingers on the patient's forehead, never clenching his fingers into a fist (Fig. 85).

The microsurgeon's fingers must function separately, which requires special training exercises. These include a simple exercise with successive alternate bringing together and spreading of the fingers of the hand (Fig. 86).

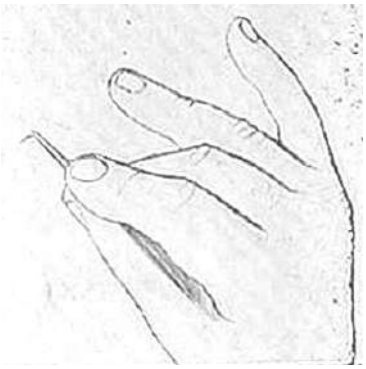

Fig. 85. **Fixation of a microsurgical instrument**

At first, if difficulty arises in performing the exercise, pads in the form of gauze rolls should be placed between the fingers. Playing the piano is also useful for training the finger joints, although it is by no means necessary to be a pianist: you can simply type on the keyboard or perform exercises simulating the game on the table. The microsurgeon should train his fingers in performing grasping, pinching movements using the pads of the fingers, which will then ensure easy interception of the microneedle, thread, and will develop tactile sensitivity. It is useful to perform squeezing and relaxing movements with the fingers, for example, squeezing and releasing an ordinary rubber ball. This training will help to smoothly squeeze and unclench the microinstruments of the fixing action.

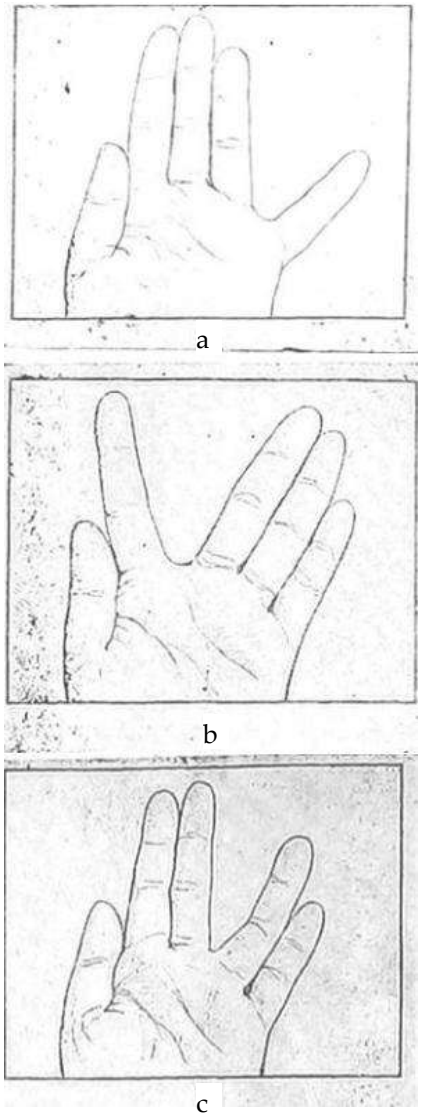

Fig. 86. **Training exercise for a microsurgeon - sequential spreading and bringing together of the fingers (a, b, c)**

We also recommend rotational exercises, which are necessary when passing the needle through tissue, when performing trepanation of the sclera and cornea. These movements are performed with the participation of the hand, which is located horizontally on the fixing device in a state of slight supination or pronation.

It is very useful to repeat the movements practiced under the microscope using instruments, trying to keep their working ends in the field of view of the microscope under various magnifications.

In this case, the surgeon gets used to the new reflex "eye - working part of the instrument", the slowness of the movements and their small amplitude.

All microsurgical manipulations should be performed suspended, absolutely without pressure on the tissues. This habit is easy to acquire by the exercise of grasping and holding matches suspended with paired fingers. The exercise also trains the ability to work the fingers in isolation (Fig. 87).

Experience shows that the time it takes to master a microsurgical technique requires several months (up to six months). However, the time it takes to shorten this process largely depends on the surgeon himself. Patience is necessary. Moreover, it is much easier for a newcomer to ophthalmic surgery to acquire the necessary skills, who

has not yet developed his own habits and a stereotype in his work.

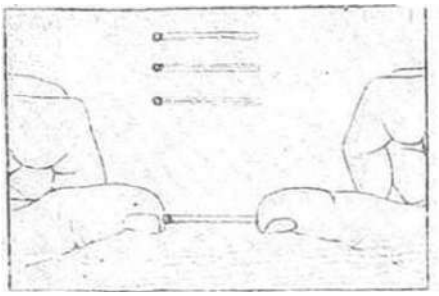

a

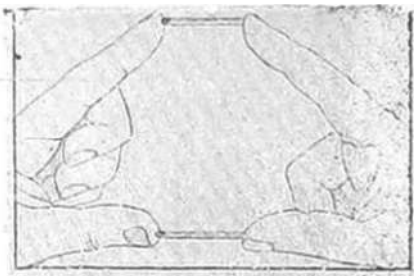

b

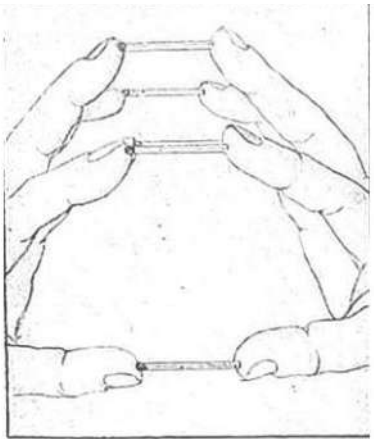

c

Fig. 87. **Training exercise for a microsurgeon - successive grasping of matches with paired fingers of the hands (a, b, c)**

It is much more difficult for a doctor with extensive experience as an ophthalmic surgeon to adapt to microsurgical techniques.

Naturally, at first, he will experience discomfort while working with a microscope, perhaps there will be dissatisfaction, some nervousness, since the usual and previously easy-to-perform techniques, for example, making an incision, suturing a wound, become unusually labor-intensive and uncertain. It is quite natural that a surgeon, losing old habits and confidence in his actions in these conditions, would like to return to them again.

This is where you need to say to yourself: "Stop!" There should be no return to the old! If a surgeon performs one operation using a microscope and microinstruments, and a second operation of the same type using the old method; or performs part of a surgical intervention under a microscope, and part without it, then the acquisition of new habits will be delayed for a long time. There were cases when a doctor with a lot of experience, having tried to plunge into microsurgery and having encountered certain difficulties, refused microsurgical interventions altogether. However, there should be no return from microsurgery. It will become habitual and will bring satis-

faction after the surgeon has developed in himself a new reflex “eye – working end of instruments”, gets used to the operating field, strongly limited by the magnification of the microscope, slow movements of the fingers.

Hemostasis in microsurgery. A solid principle of all microsurgical interventions is the creation of a “dry” surgical field.

Drying of the field is of primary importance and should be carried out with materials that actively absorb blood, but at the same time do not leave behind foreign elements in the form of fibers. Pieces of foam rubber, methylcellulose sponge, cigarette filters meet these requirements. But most often, "cigarettes" made of absorbent cotton wool are used. They are prepared as follows: a roll of absorbent cotton wool is stratified and moistened with water. Then the layer of cotton wool is cut into pieces measuring 4X5 cm. Each such piece, before rolling with the palms into a "cigarette", must be folded from two opposite sides, which eliminates the possibility of leaving cotton fibers in the wound during use. Having rolled the "cigarette" in the palms, it must be placed on a smooth hard surface and rolled again "ironed" with a wooden board (similar to how linen was rolled with a roller in the past). The tightly squeezed “cigarettes” are wrapped in a gauze napkin for autoclaving.

It is impossible to operate under a microscope if there is bleeding from the eye membranes: the risk of cutting the tissue, in particular, with a razor, without accurately seeing the area in which you have to work is too great. Drying the surgical field with the efforts of an assistant, unlike traditional surgery, cannot provide the time necessary for cutting or suturing the tissue since this time is extended during microsurgical operations.

That is why, in microsurgery, it is necessary to take measures for hemostasis of both a general and local nature. If, according to the data of the examination, the patient is found to have a condition that can lead to increased bleeding (hypertension, diabetes mellitus, decreased blood clotting, prolongation of bleeding time), then it is necessary to take appropriate measures already in the preoperative period. Currently, the most popular is the Yugoslav drug dicinon. It reduces bleeding time, reduces capillary permeability and fragility, increases the number of platelets and causes their activa-

tion, without promoting thrombus formation.

Dicynone is especially indicated for the prevention of capillary bleeding, which is necessary in microsurgical practice. Dicynone is prescribed in tablets of 0.25 g several hours before surgery, and is also administered intramuscularly or intravenously - 2-4 ml (1-2 ampoules) of a 12.5% solution of the drug. Dicynone can be combined with well-known agents that reduce bleeding (vicasol, calcium chloride, aminocaproic acid, etc.).

Among local hemostatic preparations, one can name hemophobin, which is a pectin solution with the addition of calcium chloride. This solution, released in vials and ampoules, is collected with a pipette and dripped directly onto the bleeding surface of the wound. The drug can also be prescribed 1 tablespoon 2-3 times a day for oral administration. It is possible to use a hemostatic sponge, which is prepared from native human blood plasma and thromboplastin. The sponge has the appearance of a dry, light yellow mass that easily crumbles when pressed. To stop capillary bleeding, a sterile sponge should be applied to the wound surface.

Sometimes bleeding is caused by vascular trunks connected with emissaries in the sclera. These vessels are classified as anterior ciliary, usually located in the opening of the scleral outlet, and therefore gape. Under the microscope, one or another vessel can be seen to take in aqueous humor, which washes away the blood. These vessels must be turned off by another method - thermocoagulation, using an injection needle heated over a spirit lamp flame, a probe, or better yet, a rod onto which a metal ball is soldered to maintain the temperature (Fig. 88). Diathermocoagulation cannot be used to cauterize a bleeding vessel.

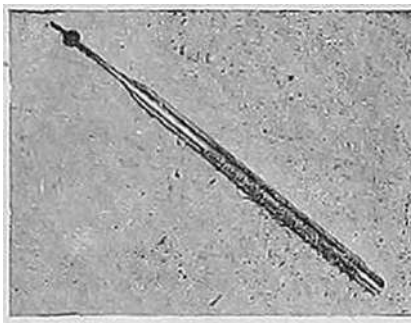

Fig. 88. **Thermal cautery**

Sometimes a vessel connected with the emissary, due to its gaping opening, is difficult to turn off by coagulation. In this case, it is necessary to coagulate the sclera near the emissary, where the anterior ciliary vessel passes in the thickness of the tissue. Naturally, such a crude in-

strument as a muscle hook cannot be used for the purpose of coagulating a vessel.

A novice microsurgeon should be advised not to get carried away with coagulation of the sclera and to strive, if possible, to turn off only the vessel itself, without unnecessarily cauterizing the surrounding tissue.

Incisions and sutures. According to Academician M.L.Krasnov, 90% of any surgical operation consists of tissue incisions and suturing. This position undoubtedly applies to eye microsurgery. Therefore, we consider it necessary to teach the beginning microsurgeon how to make incisions in various tissues of the eyeball, how to suture surgical wounds, and how to tie and remove suture threads.

Every surgeon should get into the habit of examining the working ends of instruments under a microscope before surgery and replacing the instrument if it is unusable. Particular attention should be paid to assessing the quality of a razor blade fragment.

The law of microsurgical interventions is the prohibition of any manipulations, especially making tissue incisions, without their reliable fixation with tweezers, which not only fix the tissue but often feed it towards the cutting or piercing instrument, which facilitates both cutting and piercing of tissue. The techniques for fixing the eyeball in a fixed position are well-known to doctors from general ophthalmosurgical practice.

Fixation with tweezers can be done by grasping the tissue at the limbus along the 6 o'clock and 3 o'clock meridians, fixing the superior rectus muscle, which is convenient for manipulations in the area of the upper limbus.

However, as experience shows, in microsurgery, given the small size of the field of view under the microscope, it is more advantageous to fix the tissue being cut or punctured near the site of the cut or puncture, exerting counter pressure on the cutting or piercing instrument.



Fig. 89. **Section of the conjunctiva of the eyeball**

In some cases, for example, during goniotomy, double fixation is used at two opposite points, which also allows for rotation of the eyeball. The simplest in technical terms and safest are manipulations on the conjunctiva of the eyeball, with which, in fact, microsurgical activity should begin.

Conjunctival incisions are most often made with thin, slightly curved scissors with blunt long ends. These features are very advantageous since the surgeon's fingers do not shade the surgical field.

You can use spring scissors, which are quite maneuverable in operation. All scissors cut tissue by crushing it between the branches.

Since the conjunctiva of the eyeball is easily displaced, it must be fixed before cutting. To do this, use surgical tweezers to grasp a fold of the conjunctiva with the left hand. The width of the grasped fold and the density of its grasp with tweezers determine the fixed tissues.

If the jaws of the tweezers are opened wider, within 5 mm, and the tissue to be fixed is pressed down, then in addition to the conjunctiva, Tenon's capsule will be in the captured fold. The first section of the fixed tissues should be made with the scissors perpendicular or slightly obliquely positioned behind (or next to) the captured fold (Fig. 89). When creating a conjunctival flap during cataract extraction surgery, and especially during antiglaucoma operations, one must strive to spare the conjunctiva as much as possible. One must not repeatedly grab the incision tap with tweezers or insert the scissor's jaws into the wound several times. One must try to cut out the conjunctival flap by making two or three sections of the tissue with scissors while fixing the edge of the incision behind Tenon's capsule. Otherwise, the incision will be uneven, multi-stage, and a hole may appear in the conjunctiva, especially with careless separation of the flap. It must be closed. If the conjunctiva is thin and tears from one touch of tweezers and a needle, it is useless to eliminate the resulting hole by suturing it: the more you sew, the more the hole in the conjunctiva increases, and, in addition, new holes appear from the needle puncture. In this case, the tissue defect should be closed with thermocoagulation.

To do this, use tweezers to grasp the tissue around the gaping wound and cauterize it with a hot thermocauter (preferably from the

inner, wound surface). A more gentle, physiological, bloodless measure is to tamponade the opening in the conjunctiva with Tenon's capsule. To do this, the tissue of Tenon's membrane is grasped with tweezers through the opening in the conjunctiva (Fig. 90), brought out, after which the conjunctival tissue is tied with a thread (without applying a suture) at the edge of the tamponade opening.

Conjunctival wounds can be closed with interrupted sutures, a continuous suture across the edge, or a mattress suture, which seals the brine well.

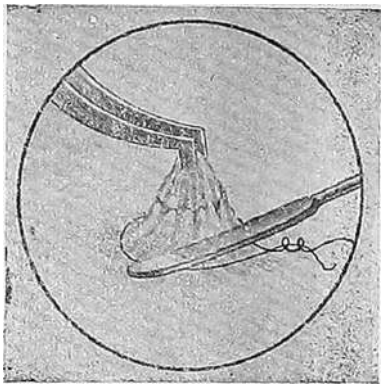

Fig. 90. **Tamponade of the hole in the conjunctiva with Tenon's capsule**

We prefer to apply a suture through a tap, without tensioning the tissue. It is better to sew with a double microsurgical thread, with frequent stitches, capturing only the edge of the conjunctival incision (without Tenon's capsule, which, however, can be pulled into the suture with a needle three or four times). The ends of the continuous suture thread should be secured with a loop. The criterion for a sufficiently good adaptation of the edges of the sutured wound is the retention of a sterile air bubble under the conjunctiva (after performing antiglaucoma surgery).

After cataract extraction surgery, the wound tightness should not be checked in this way. When applying interrupted sutures, the ends of the microthreads above the knots should be cut short with scissors. A razor blade should not be used for this procedure since active tension on the ends of the thread may cause it to cut through the conjunctival tissue.

Removal of a continuous suture from the conjunctiva must be done under instillation anesthesia.

Using an injection needle, we usually untie the knot (loop) at the ends of the suture, cut the suture thread in two or three places with scissors and, grasping the cut sections with tweezers, calmly remove them.

Manipulations on the outer capsule of the eye are of a more re-

sponsible nature. Since the cornea, being quite close to the microscope's illuminating lamp experiences heating and, as a result, dries out quickly, all microsurgical operations on it must be accompanied by continuous tissue hydration using a physiological solution or Medium 199.

Most often, incisions on the cornea are not made immediately. It is better to first cut the cornea by 2/3 of its thickness (for example, during cataract extraction with a corneal approach). Moreover, this non-through incision should be made with one movement of a razor blade. For greater confidence in the actions, under the control of a microscope, using an injection needle or a micro spatula, you can apply (draw) the outline of the future incision on the cornea with a solution of brilliant green.

We never recommend repeating the incision several times, gradually deepening the razor blade into the corneal tissue. The fact is that the cornea is very hydrophilic, and after the incision is made, the edges of its wound quickly swell (the wound seems to strive for self-adaptation). This masks the cut line, making it less noticeable. Therefore, subsequent tissue sections with a razor may go along a different channel, and the incision as a whole will be multistage, and the edges of the wound channel will be uneven. This unnecessary tissue trauma can be avoided to a certain extent by dripping a fluorescein solution onto the cornea and washing it off. However, fluorescein will only clearly reveal the course of the first (epithelial) incision line, but not repeated deeper tissue sections. We recommend performing the final incision of the remaining deep third of the cornea (during cataract extraction surgery) with a razor through paracentesis, after which the lower, longer branch of the corneal scissors is inserted into the opening.

The microsurgeon should remember that, to maintain the evenness of the incision, they must not take a 'step' after closing the scissors' jaws and removing the lower jaw from the anterior chamber. Instead, the lower jaw should remain in the chamber to guide the proper direction of the next 'step' in the tissue incision. If this is not done, the incision may become jagged, which could hinder proper adaptation during subsequent suturing.

Corneal trepanation under a microscope allows one to see the trace of the first position of the trephine (epithelial imprint), to estimate the depth of the tissue section, to avoid lateral sliding of the cut-

ting edge. Having placed the trephine perpendicular to the surface of the cornea, the surgeon should make small rotational movements towards and away from himself, excluding rough boring or screw-like depressions of the cutting edge of the trephine in the corneal tissue. The trephine procedure should be performed under the lowest magnification of the microscope, and it is advantageous to tilt the optical head forward as much as possible in order to clearly see the area of the corneal section.

In layered keratoplasty, corneal trepanation is followed by detachment of the cut-out recipient disc. The procedure can be performed with any cutting instrument, including a razor blade, but a round knife is better. The most critical moment is the beginning of delamination. The tweezers are used to grasp the corneal plates in the dissection zone, lifting them upward. The dissecting instrument is inserted into the resulting gap, and the corneal stromal fibers, clearly visible under the microscope, are dissected with horizontal movements, tangentially. It is necessary to strive to separate the flap in one layer, ensuring that the resulting bed for the donor cornea has a smooth surface.

A microsurgeon who is accustomed to moistening the cornea surface when working with it should refrain from moistening the tissue in the incision area in this case.

The surgical field should be dry, otherwise, the surgeon will be disoriented in depth and may involuntarily change the "incision level", up to perforation of the corneal tissue.

Before the procedure of suturing a corneal wound, the surgeon should master the correct grip of the microneedle with a needle holder. The needle should be fixed in its middle part, perpendicular to the axis, which ensures its proper maneuverability. The grip should be made 1 mm from the edge of the needle holder jaws. If the working ends of the needle holder are not straight, but curved, then the convex part of the curvature should be located on the side of the needle tip (Fig. 91).

In order for the thread to slide well in the tissue, the diameter of the needle cross-section must be at least twice the diameter of the thread cross-section. Microsilk fully satisfies this requirement and even more. The wound channel after the microneedle passes through a double microsilk thread and, in addition, a knot, which (without tight-

ening) some surgeons tie under the eye of the needle. This is done for reasons to more easily detect the needle when it is lost if the thread is fixed on the needle. For better sliding of the thread in the wound channel and on the needle holder (in the process of winding when tightening the suture knot), the thread can be moistened.

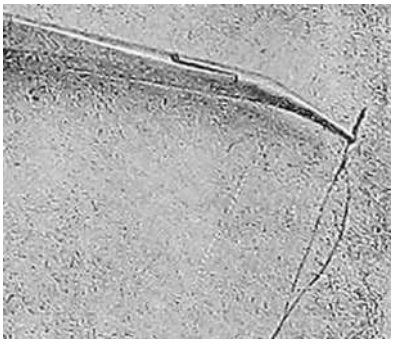

Fig. 91. **Capturing the microneedle with the needle holder**

It should be recalled that the "suture pitch", i.e. the distance of the needle insertion and exit from the wound edge, should be 1.0-1.5 mm, and the suture should be deep and reach Descemet's membrane. There are no objections to the application of through sutures with capture, despite the difficulty of puncturing Descemet's membrane. Sutures that adapt the wound edges throughout their depth are a reliable preventative measure against the development of adhesions from the wound edges.

It is necessary to ensure that during suturing of the wound, there is no distortion of the wound edges with their displacement both vertically and horizontally, so that the puncture and puncture of the needle are carried out symmetrically, on one straight line. Before suturing, the edge of the wound should be well fixed with tweezers, after which the needle should be punctured perpendicular to the surface of the tissue near the place of fixation. After the puncture, without removing the fixing tweezers from the edge of the wound, the surgeon with his right hand with the needle holder, in accordance with the curvature of the needle, makes a rotational movement in order to pass it into the tissue.

The needle should be pushed not only by pushing it straight forward but also by moving it slightly to the sides, which will help it pass more easily by cutting the tissue. It is also useful to use the fixing tweezers to feed the edge of the wound onto the needle as if putting it on or pricking the tissue onto it (Fig. 92 a).

As the needle advances, the needle holder can be moved back along it, in the direction of the eye, while pushing the needle itself

forward. The fixing tweezers must not be removed until the needle has been passed through the edge of the wound. In parallel with the insertion of the needle tip into the opposite wound edge, the fixing tweezers are transferred to it (Fig. 92 b).



Fig. 92. **Technique of suturing the edges of a corneal wound; a — first stage; b — second stage**

After suturing the second edge of the wound, the surgeon transfers the needle with the thread to the left hand, pulling the thread through the suture channel almost to its end. This makes it possible to use the same thread for subsequent stitches.

After this, the long end of the suture thread is wound twice around the closed jaws of the needle holder (either toward or away from you), the short end of the thread is grasped with the spread jaws of the needle holder and, passing it through the turns of the long thread, the suture knot is tightened (Fig. 93a). Next, the procedure of single winding of the thread is performed, but in the other direction, with the final tightening of the knot (Fig. 93b).

Considering the fact that the cornea is very hydrophilic, as a result of which the edges of the surgical wound swell quickly, you should not tighten the suture knot too actively (the edges of the wound should only be brought together, but not pulled together). Otherwise, in the postoperative period, a bedsore may appear under the suture knot, and the knot itself will sink into the corneal tissue, which will cause difficulties in removing it. A more severe complication in the form of necrosis and sequestration of the area of the cornea compressed by the suture is also possible.

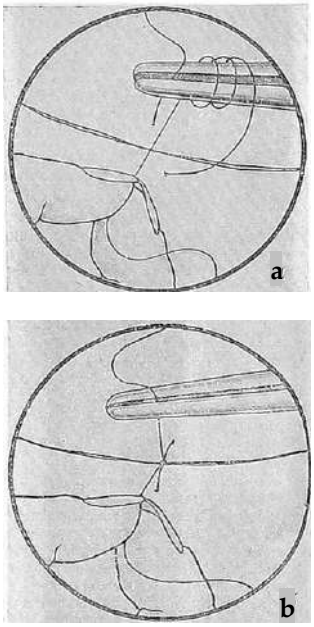

Fig. 93. **Technique of tying a seam: a — first stage; b — second stage**

After tightening the knot of the suture, the threads must be cut short enough, using a razor for this. There is no cutting of the dense tissue of the cornea when tensioning the threads of any suture material (Fig. 94).

To avoid traumatizing the tissues of the eye (the mucous membrane of the eyelids), it is advisable to melt the sharp ends of the synthetic microthread by touching them with the end of the thermocauter. The knot of any suture should not be left over the wound channel. It must be shifted to the side, peripheral to the incision line, by tightening the thread.

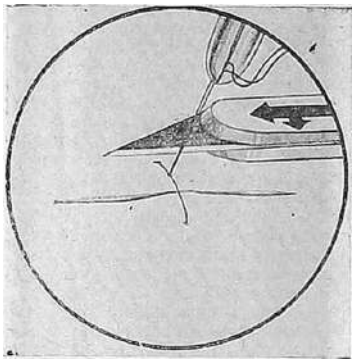

Fig. 94. **Technique for cutting seam threads**

Since silk, and especially synthetic threads, practically do not cause a reaction in the corneal tissue, they should be kept for a long time, until the wound is completely consolidated (3-4 weeks).

Removal of sutures from the cornea must be done only under a microscope.

Before removing the sutures, it is necessary to produce sufficiently good instillation anesthesia, and in some restless patients even akinesia of the eyelids. After weeks of being on the horn, the knot and ends of the thread of the silk suture become discolored.

Therefore, it is useful to stain the suture with a fluorescein solution before removing it. Then all the elements of the thread that need to be removed become clearly visible. The procedure should be carried out using a neutral filter of

the microscope to reduce the phenomena of photophobia and blepharospasm that inevitably arise in the patient from bright light. With one of the microtweezers, preferably tweezers for tying sutures, you should lift the knot of the suture, after which, through the resulting gap, using a razor blade, cross the thread of the suture with a movement from the inside out.

With successful healing of the corneal wound, removal of the sutures is not accompanied by seepage of drops of chamber moisture through the wound channel.

Scleral incisions and suturing of scleral wounds are somewhat different from the installations given above in relation to the cornea. When incising the sclera, it should be fixed nearby, and the fixation point should be changed in accordance with the continuation of the incision line ("step by step"). In advance, to ensure the manipulation, you can mark the area of the proposed incision with a solution of brilliant green. The incision should not be made immediately through the entire sclera. It is made layer by layer until a slate-brown color appears in the depth of the section, indicating that only a few plates separate the scleral wound from the underlying vascular membrane. When performing antiglaucoma operations, it is very often necessary to cut out triangular or quadrangular U-shaped flaps from the incision made in the sclera with a razor.

The process of flap separation should be carried out at one level, i.e. at one depth. The sclera can be stratified with any cutting instrument, but preferably with a razor blade or a round knife. The appearance of semi-transparent layers of the limbus during separation will indicate the projection of the anterior border ring of Schwalbe. In this case, the space between the ring and the emissaries of the sclera, through which the bleeding anterior ciliary veins, clearly visible under a microscope, also carrying colorless intraocular fluid, exit, will correspond to the location of Schlemm's line.

The sclera, unlike the cornea, is not hydrophilic, does not swell, and its incisions do not tend to self-adapt. Therefore, not only linear wounds of the sclera but even stab (pinpoint) wounds are prone to gaping. Any ophthalmic surgeon can verify this fact if he accidentally punctures the sclera with the end of a needle during scleroplastic surgery. The vitreous body usually begins to flow out through the pinpoint puncture.

Scleral wounds are closed with through (or almost through) sutures according to the principle of suturing corneal wounds. However, unlike the cornea, the suture knot should be tightened tighter, achieving tight adaptation of the wound edges, since edema of the scleral tissue and more active convergence of the wound edges against this background will not follow. If it is necessary to strongly tighten the scleral wound, in scleroplasty operations, it is better to use a twisted thread. Such a thread holds the wound edges together quite well, even in the presence of one or two overlaps.

Sutures on scleral wounds are covered with conjunctiva and are not subject to removal, except in cases where the knot and ends of the cut thread are eliminated through the conjunctiva.

In these cases, the suture must be removed. Scleral sutures brought out (after tightening one knot and crossing the threads) to the surface of the conjunctiva of the eyeball are also removed. Scleral sutures are removed with a razor.

Microsurgical interventions on the iris, i.e. inside the eye cavity, should be performed after mastering manipulations on the conjunctiva and the external capsule of the eyeball.

Neither section nor excision of the iris can be performed without fixing its tissue with tweezers. It is best to use micro-surgical tweezers of the "hummingbird" type with working ends in the form of semicircles (Hoskin tweezers). As a cutting instrument, preference should be given to iris scissors.

A razor blade is not suitable for working with the iris. When fixing the iris, care must be taken to capture both its mesodermal and ectodermal layers without applying excessive pressure on the underlying crystalline lens to avoid injuring its capsule. In the case of performing a peripheral iridectomy, the microsurgeon should select an area of iris tissue for excision, avoiding large trabeculae. The trabeculae contain blood vessels, and their dissection—especially in glaucoma, where the iris tissue is under tension due to miosis—can lead to bleeding. This bleeding may occur not only during surgery but also in the postoperative period.

In our practical work, we observed such a picture, when from the area of the coloboma (from the place of a section of the iris in the trabecula zone) a thin stream of blood flowed out, which explained

the presence of a recurrent hyphema. In order to avoid the formation of a wide peripheral coloboma, which can lead to a cosmetic defect in the form of sagging of the pupillary edge downwards, iridectomy is often performed by placing the scissors jaws perpendicular, and not parallel to the limbus, as is customary in ophthalmic surgery.

When performing a complete coloboma, it is advisable to capture the iris not far from the pupillary margin, i.e. in a denser zone where the pupillary sphincter is located. The position of the iris scissors should be the same as when performing a peripheral coloboma. With a rigid pupil and hyalinized sphincter, in order to avoid excessive forced tension of the iris tissue during complete iridotomy, which is also fraught with certain complications, up to and including iridodialysis, you can first perform a basal iridectomy, from the opening of which you can perform a sphincterotomy or, better yet, an ectomy.

Microsurgical control reveals that very often during iridectomy only the mesodermal elements of the iris are excised, and in this case, the posterior pigment layer becomes visible in the lumen of the coloboma. It should be removed with a cotton "cigarette", having first washed it with a stream of saline solution, in no case should you try to fix it with tweezers. This is useless and dangerous. It is useless due to the fragility of the pigment epithelium, which crumbles when touched by tweezers, and it is dangerous due to the possibility of injury to the anterior capsule of the lens by the tweezers. The application of sutures to the incision (coloboma) of the iris differs from the suturing of wounds of the external capsule of the eye. The iris should be fixed with more atraumatic tweezers that do not pierce the tissue and can be easily removed.

The needle holder is preferably without a lock, to avoid transmitting its clicks to the tissue of the iris.

Among the needles, preference should be given to atraumatic needles without an eye. If a microsurgical needle with an eye is used, it should be loaded only with micro-surgical silk, which is sufficiently soft. A thread of synthetic fiber (monofilament), passed through the eye of the needle and folded in half, will expand the wound channel in the spongy tissue of the iris as it passes due to its spring properties. Based on the guidelines of A.I.Gorban and O.A.Dzhaliashvili (1982), as well as

our own work experience, it should be said that when suturing a wound of the iris, it is not necessary to pierce both wound edges at the same time with a needle: the loose tissue of the iris stretches behind the needle and can, having curled up, become embedded in the wound channel. To avoid such incarceration, it is necessary, to have fixed the edge of the wound with tweezers, not so much to push the needle with the thread into the iris, as to put (string) the tissue on the needle. Having stitched the wound edge, the needle should be intercepted with fixing tweezers, after which the needle holder can be removed from it. If this sequence of actions is not performed, the needle, after removing the needle holder, not being fixed in the wound channel of the spongy tissue, will turn to the side or turn down, and it will have to be grasped again.

In the presence of the lens, this grasp is feasible, but if there is a vitreous body behind the iris, each surgeon imagines the difficulties and the danger that awaits him.

The vitreous body is taken under the control of a microscope for the position of the needle in the cavity of the eyeball. With sufficiently good mydriasis, it is visible behind the lens, where it should be retained, without any tendency to approach the latter.

The microsurgical technique has now forced a revision of the surgeon's tactics in the case of vitreous body loss during cataract extraction surgery. At whatever moment the vitreous body appears in the wound (at the moment of corneal paracentesis, cutting it with scissors, during iridectomy) — the lens must be extracted.

The old tendency to quickly close the corneoscleral wound after this and strengthen it with sutures must be forgotten.

Having covered the wound and applied local cold in the form of irrigation of the eye with a physiological solution stored in the refrigerator, the microsurgeon should stop and think without rushing. First of all, it is necessary to analyze the type (character) of the vitreous body, which will determine the further tactics of the surgeon's behavior. In the presence of a liquid vitreous body, the situation is simpler. In this case, we limit ourselves to the procedure of its repositioning. If the fallen vitreous body is thick, or as they say, formed, it cannot be left in the surgical wound and the anterior chamber in order to avoid subsequent cicatricial wrinkling and traction of the retina. With

such a vitreous body, anterior vitrectomy should be performed.

Using iris scissors or pointed conjunctival scissors, all the vitreous fibers located in the wound are excised and, by raising the edge of the wound, the vitreous body fills the anterior chamber and the lumen of the pupil is dissected and removed.

The intrarectomy should be performed until the iris assumes a normal horizontal position and the pupil takes a central position with the restoration of its round shape. Otherwise, in the postoperative period, the vitreous fibers trapped in the wound will lead to the pupil being pulled upward.

During the vitrectomy, in order to avoid possible subsequent detachment of the retina, the vitreous fibrils should never be fixed and pulled upward with tweezers. For this purpose, it is best to use tightly rolled "cigarettes" made of cotton wool, the ends of which should be cut at an acute angle (A.I.Gorban, O.A.Dzhaliashvili, 1982).

By dipping the "cigarette" into the vitreous body, the surgeon at the same time cuts the fibrils trailing behind it, lowering the scissors as low as possible (Fig. 95).

The procedure is usually performed until the vitreous body elements stop rising (trailing) behind the "cigarette". This usually coincides with the moment when the iris sinks into the eye cavity while restoring the round shape of the pupil. At the end of the vitrectomy, corneal or corneoscleral sutures are applied. The anterior chamber is filled with sterile air. The pupil should be constricted in order to "lock" the vitreous body behind the iris. We recommend completing all microsurgical operations on the eyeball of the cavity type by introducing antibiotics under the conjunctiva.

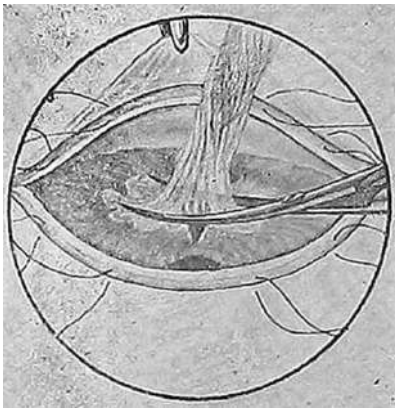

Fig. 95. **Anterior vitrectomy**

The surgeon must be clearly oriented in the compatibility of medications and their doses. This is helped by a diagram posted in a visible place in the preoperative room.

Chapter 3

MORPHOLOGICAL BASIS OF MICROSURGICAL INTERVENTIONS ON HYDRODYNAMIC STRUCTURES OF THE EYE

In recent years, major changes have occurred in the teaching of primary glaucoma. A new domestic dynamic classification of glaucoma has been created. This introduced a characteristic of the process based on the width of the anterior chamber angle opening, taking into account the stage of the disease, the degree of intraocular pressure increase, and the state of visual functions. This approach allowed the glaucomatous process to be assessed in terms of the presence or absence of stabilization.

This is of great importance in the issue of rational drug therapy, assessment of the need to include a surgical type of medical care in the system of glaucoma patient care.

In order to correctly select a treatment method and antiglaucoma surgery at the microsurgical level, an addition to the above-mentioned classification of the glaucomatous process is proposed, which has a pathogenetic element, with a subdivision, at the suggestion of Academician of the USSR Academy of Medical Sciences M.M.Krasnov, of glaucoma into hypersecretory and retention forms, with further pathogenetic differentiation of retention into angular, pre-trabecular, trabecular and intrascleral types (depending on the location of the obstruction to the outflow of intraocular fluid).

In some cases, retention occurs due to transient, inorganic causes, but more often as a result of irreversible morphological changes in various links of the hydrodynamic structures of the eyeball. Microsurgical interventions of a pathogenetic nature in primary glaucoma, aimed at eliminating the "breakdowns" that arise in one or another section of the hydrodynamic system, must be performed taking into account the peculiarities of anatomy.

The second edge of the iris wound should be sutured in the same way (fixing the iris with tweezers, passing the needle, intercepting the needle with tweezers and again grasping it with the needle holder). It should be noted that recently we have almost abandoned the use of the needle holder, replacing it, for the sake of ease and

quality of the needle insertion procedure, with fixing tweezers.

When working on the iris, do not rush to tie the sutures. First, all other planned manipulations are performed (in particular, on the lens or vitreous body), after which the knots of the sutures passed through the iris are tightened. For this purpose, tweezers are used to tie the sutures.

The ends of the suture threads should be cut shorter, using sharp scissors for this purpose. A razor blade is unacceptable for this procedure since when the threads are pulled, they can cut through the tissue of the iris.

For cosmetic reasons, the resulting suture knot can be immersed in the wound channel or transferred to the back surface of the iris. The applied sutures cannot be removed.

The microsurgeon must remember that all manipulations with the iris are performed suspended.

In the presentation of this chapter, we will not touch upon special issues of the technique of performing certain operations, but we consider it necessary to familiarize practicing doctors with some microsurgical techniques related to interventions on the vitreous body. They have to be performed in the operating room of all ophthalmological institutions. First of all, this is the "collection" of the liquid part of the vitreous body.

This manipulation, performed without microsurgical control, is fraught with various complications, and first of all, the possibility of damaging the lens.

The procedure is performed in the upper or lower outer quadrants of the eyeball, respectively, in the area of the flat part of the ciliary body.

Given the tendency of scleral incisions (and even pinpoint punctures) to gape, before suctioning the vitreous body, a reliable silk mattress suture should be applied to the scleral incision through which the procedure will be performed, without tightening it yet.

To suction the vitreous body, use a needle with a lumen of at least 0.8-1.0 mm, bent at a distance of 1.5 cm for safety reasons (in order to avoid injury to the opposite parts of the eyeball when inserting the needle into the eye cavity).

Having pierced the deep layers of the sclera between the threads of the mattress suture with a needle, the needle is sent toward the center, and upwards, where the liquefied part of the vitreous body is usually located.

Dosage of antibiotics for local application (1,000 IU corresponds to 1 mg)

Antibiotics	Concentration of eye drops	Concentration of eye ointment	Place of administration		
			Conjunctiva	Anterior Chamber	Vitreous Body
Benzylpenicillin	Benzylpenicillin	10,000–20,000 IU/ml		50,000–500,000 IU (0.5–1 mg) / 0.5–1 ml	2,000–4,000 IU / 0.1 ml
Oxacillin Methicillin	5% (50 mg/ml)		25–50 mg / 0.5–1 ml	2–2.5 mg / 0.1 ml	1–2 mg / 0.1 ml
Streptomycin	10,000–20,000 IU/ml		25,000–50,000 IU / 0.5–1 ml	1–2 mg / 0.1 ml	0.5–1 mg / 0.1 ml
Monomycin	0.25%	0.25%	10–25 mg / 0.5–1 ml	0.5–1 mg / 0.1 ml	
Gentamicin	0.25%	0.25%	10–20 mg / 0.5–1 ml	0.5–1 mg / 0.1 ml	
Erythromycin		1%			
Tetracycline		1%			
Levomycetin	0.25–0.3%	1% (emulsion)			
Polymyxin	10,000–25,000	20,000 IU/g	25,000–50,000 IU / 0.5–1 ml		
Cephorine			50 mg / 0.5–1 ml		

At the same time, the surgeon makes searching movements with the needle to the sides, simultaneously pulling the plunger of the syringe attached to the needle until 0.2 ml of liquid vitreous body is extracted.

Since both hands of the surgeon are occupied during this procedure (the left hand holds the syringe, and the right hand holds the plunger), fixation of the eyeball should be entrusted to another person. After suctioning the vitreous body, on the surgeon's command, the assistant should quickly (based on the anatomical and physiological principles of this system, which we will discuss further in this monograph) act.

In our opinion, only a doctor in training who has thoroughly familiarized themselves with the topography, anatomy, and physiology of the area where they will perform microsurgical procedures should be allowed to participate in training exercises and, later, independent work.

The concept of the hydrodynamic system includes anatomical elements that produce and drain the intraocular fluid, which is formed and transported in accordance with a number of regularities and physical laws.

Intraocular pressure is known to be caused by the impact of the internal structures and components of the contents of the eyeball on the outer capsule of the eye. These include the vitreous body, the lens, the retinal and vascular membranes, the blood volume which is not constant but is subject to fairly significant physiological fluctuations that affect the level of intraocular pressure (ocular motonus).

However, this influence cannot be compared with the role of the volume of free intraocular fluid, which accounts for 4% of the volume of the entire eyeball. Situated in the anterior and posterior chambers of the eye and in the capillary spaces between the membranes of the eyeball, the intraocular fluid makes up 200-300 mm^3. The amount of fluid is not constant, which is associated with its continuous renewal, i.e., new production and outflow from the eyeball.

The eye itself with its hydrodynamic system can be compared to a flow pool, where a strictly defined amount of liquid constantly flows into and out of it. The study of this process is the basis for studying the hydrodynamics of the eye.

Numerous experimental and clinical studies have established the reliable fact that 2-3 mm3 of liquid is normally produced in one mi-

nute, while the same amount flows out of the eye, and at the same time, calculations are used.

The study of the physiological foundations of the functioning of the hydrodynamic system of the eye is closely connected with the clinical anatomy of the structures that determine the process of hydrodynamics.

These structures include, first of all, the ciliary body, which, along with the responsible function of implementing the act of accommodation of vision, has an equally important function of producing intraocular fluid. It is known that the anatomical differentiation of the ciliary body, in the process of antenatal development, ends in the fourth month of the intrauterine life of the fetus. The beginning of the functioning of the ciliary body as a structure producing intraocular fluid also dates back to this time. The accommodative function of the ciliary body, naturally, gets the opportunity to develop only in the vasovagal period.

The ciliary body, as is known, is located between the iris and the choroid (Fig. 96). Its anterior border is the root of the iris, and its posterior border is the projection site of the dentate line of the retina onto the choroid. The ciliary body is 6 mm in length, of which 2 mm is the open part (Fig. 97) and its flat part (Fig. 98).

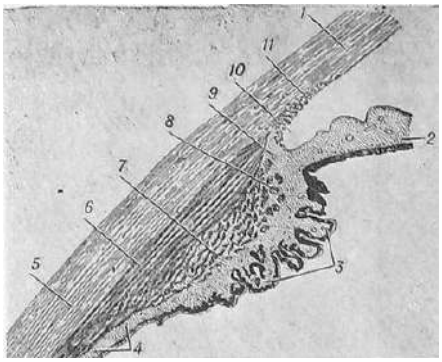

Fig. 96. **Ciliary body and surrounding structures (according to V.M.Shepkalova)**
1- cornea; 2- iris; 3- pars plicata (ciliary processes) of ciliary body; 4- vascular layer; 5- sclera; 6- meridional part of ciliary muscle (Brucke's muscle); 7- radial part of ciliary muscle; 8- circular part of ciliary muscle (Muller's muscle); 9- major arterial circle of iris; 10- Schlemm's canal; 11- trabecular apparatus

The functions of moisture formation are associated only with the processive part of the ciliary body, specifically with the processes themselves, which in the amount of 70-80 villi protrude into the cavity of the eyeball. Each process has a vascular core containing an artery and it. When characterizing the processive part of the ciliary body, its anterior part adjacent to the root of the iris should be specially highlighted.

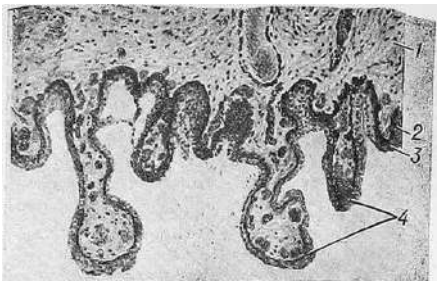

Fig. 97. **Process part of the ciliary body (according to V.M.Shepkalova)**
1- vascular layer; 2- pigment epithelium of ciliary body; 3- non-pigmented ciliary epithelium; 4- ciliary processes



Fig. 98. **Flat part of the ciliary body (according to V.M.Shepkalova)**
1- sclera; 2- meridional part of ciliary muscle; 3- vascular layer; 4- pigment epithelium of ciliary body; 5- non-pigmented ciliary epithelium

In fact, this is the first, largest process, which is called the cornice of the ciliary body. The position of the cornice in relation to the root of the iris and the angle of the anterior chamber (in projection) determines the profile or level of the posterior chamber of the eye, which plays a major role in the technique of performing antiglaucoma operations, including an element of iridectomy.

In the presence of a powerful ciliary body, the latter can extend to the equator of the lens, creating the prerequisites for the occurrence of some complications in the postoperative period in glaucoma, in particular for the formation of a pupillary block. Often, in response to the question of which intraocular membrane the ciliary body is a part of, one has to hear: "The ciliary body is the middle part of the vascular membrane of the eyeball."

The answer is only half correct. The fact is that the ciliary body includes not only mesodermal (related to the vascular tract), but also ectodermal (related to the retinal membrane) elements.

This knowledge is necessary: it helps to correctly understand the mechanism of formation of intraocular fluid, which, as will be discussed below, is of a complex combined nature.

The mesodermal part or portion of the ciliary body includes four elements. First of all, there is the periciliary space (Fig. 99), sometimes incorrectly called the suprachorionic space. It is a capillary slit around the ciliary body, blindly ending in front at the level of the transition of the ciliary body into the iris and passing posteriorly into the perichorionic space.

Unlike the perichorionic space, filled with a large number of fibrous-lamellar elements of the suprachorionic tissue, the periciliary space is significantly wider, especially in its anterior parts.

In addition, there are significantly fewer tissue structures here. The space is crossed only by the trunks of the anterior ciliary vessels associated with the emissaries of the sclera, and rare bundles of periciliary tissue are located in it.

The periciliary space contains the same fluid that fills the anterior and posterior chambers of the eye.

The structural anatomical features of the periciliary space explain the appearance of choroidal detachment primarily.

This fact, proven by clinical observations, as well as by echographic and histomicroscopic studies, forced us to change the technique of surgical intervention in case of choroidal detachment both in cases of its elimination and for the purpose of prevention.

In particular, at the Department of Ophthalmology of the Central Order of Lenin Institute for Advanced Medical Studies, when solving the above-mentioned issues, we completely abandoned the posterior trepanation of the sclera, which was performed several years ago. The trepanation hole in the sclera, located at the level of the perichorionic space, is not capable of completely evacuating all the exfoliated fluid accumulated in the cells of the suprachoroid and in the periciliary space, where it collects first and in large volumes. The hole made, as follows from the data of hysteroscopic studies, very soon closes with fibrous tissue suprachoroid and eventually ceases to perform its drainage function.

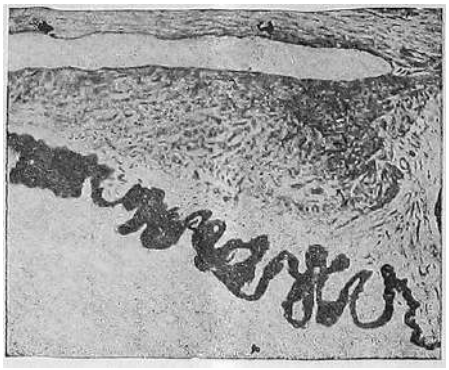

Fig. 99. **Periciliary space**

This, as a rule, does not happen if the hole in the sclera is trepanned 3 mm from the limbus, i.e. at the level of the periciliary space, which is freer from the presence of tissue elements located in the perichornoid fissure. The hole above the ciliary body is usually not blocked by anything.

Performing an intervention in the specified topographic zone is much easier in terms of technique

and is not fraught with complications, from which even a very experienced ophthalmic surgeon is not insured. In our practical work, especially if the intervention was performed against the background of high figures of ophthalmotonus, we had to see the prolapse of the vitreous body through the posterior trepanation hole.

The surgeon, who carried out the trepanation element very carefully, was not to blame for this.

The vitreous body, under the influence of the compressive force acting from within, pushed apart the thin tissue of the retina and rushed through the intervascular clefts of the chornoid into the trepanation zone. At this point (after closing the opening), the intervention, which was performed as the first element (in order to prevent possible detachment of the choroid), usually ended. The main stage of the planned anti-glaucoma operation had to be postponed for another time.

Such a complication, as a rule, is never observed when performing trepanation of the sclera or sclerotomy above the ciliary body. Here one can only expect invagination of the ciliary muscle into the trepanation window, which sometimes occurs under the pressure of greatly increased intraocular pressure.

However, invagination is temporary. After the main elements of the subsequent antiglaucoma surgery have been performed and the intraocular pressure has been reduced, the ciliary muscle takes its previous position, and the trepanation hole in the sclera becomes free, ready to perform the role of a conductor of fluid that accumulates during coronoid detachment in the non-ciliary space.

In cases where ciliary trepanation is performed not for prophylactic purposes, but to eliminate the detachment of the choroid that has already occurred, the intervention is usually used by us in another very advantageous aspect.

It is well known that detachment of the choroid is accompanied, as a rule, by the crushing of the anterior chamber, and sometimes its complete disappearance, which is fraught with serious, sometimes difficult-to-eliminate consequences in the form of the formation of high trapezoidal goniosynechiae, contacts and adhesions with the cornea of the iris and the anterior surface of the lens.

The appearance of such changes is fraught with the development of a severe clinical form of secondary glaucoma, the appearance and progression of a very specific sequential contact cataract, which

subsequently requires surgical treatment. Therefore, in order to prevent these changes, and in some cases to eliminate already started but not yet fully formed adhesions, ciliary trepanation of the sclera, performed to eliminate the detachment of the choroid, must be combined with the procedure for restoring the depth of the anterior chamber.

To do this, a spade-shaped needle connected to a syringe filled with sterile air is inserted into the pericylindrical slit through a trephine hole in the sclera.

The needle is advanced forward toward the limbus until its end appears in the corner of the anterior chamber, which is clearly visible through the cornea. After this, having made sure that the needle is actually in the anterior chamber and not in the posterior chamber of the eye, sterile air is introduced into the space of the anterior chamber by lightly pressing on the plunger of the syringe. In this case, the entire iris-lens diaphragm is displaced posteriorly, which is accompanied by separation of the adjacent membranes and rupture of the adhesions that have arisen between them. Rupture of adhesions of richly innervated cornea, iris and identification zones of the angle of the anterior chamber can be quite painful, which makes it necessary to perform the intervention against the background of conduction anesthesia. It is provided by retrobulbar injection of a 2% solution of novocaine in the amount of 1.5-2.0 ml.

Experience in practical work convinces us of the necessity of instillation into the conjunctival cavity after the intervention and in the first days of the postoperative period of atropine solution and hydrocortisone or dexazone solution. This reduces the manifestations of possible traumatic iridocyclitis. The instillation of a 1% solution of atropine, sometimes with subconjunctival administration, in addition to 0.2 ml of a 0.1% solution of adrenaline, promotes the rupture of posterior synechiae and the prevention of pupillary block, the occurrence of which against the background of long-term drug-induced miosis in a patient with glaucoma in the postoperative period is more than likely.

The second anatomical element of the mesodermal part of the ciliary body is the ciliary muscle, consisting of three portions (Fig. 100).

The first of them is the meridional muscle of Brucke, whose surface faces the peri-ciliary space. Its anterior part is attached to the trabecular ligament and the scleral

spur, the posterior part continues into the peri-chorionic space and the tissue of the choroid. When the muscle contracts, the anterior fixed part somewhat stretches the fountain spaces and the lumen of the Schlemm's canal, facilitating a more active outflow of intraocular fluid, and the posterior part of the muscle pulls the choroidea forward.

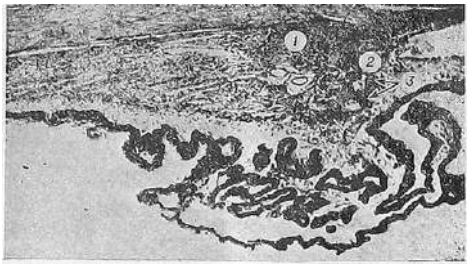

Fig. 100. **Ciliary muscle (according to A.P.Nesterov). Magnification x35: 1 – meridional part; 2 – radial part; 3 – circular part**

Based on this, the act of accommodation performed by the ciliary muscle should be considered very useful for a patient with glaucoma.

For such patients we recommend simple exercises for fixing the gaze on objects located at different distances from the patient, with the movement of the line of sight from one object to another.

The ciliary muscle includes, in addition to the indicated meridional part, which has a certain relation to the hydrodynamic system of the eye, the radial and circular muscle portions (Ivanov's and Müller's muscles), which in the process of accommodative efforts actually do not affect the hydrodynamics of the eye.

It has long been noted that the volume and shape of the ciliary body vary very widely. Thus, in particular, in a hypermetropic person, who has a further point of clear vision in the negative space behind the eye, the visual act is carried out only by the effort of accommodation.

A hypermetrope, due to his insufficient refractive power, cannot see clearly into the distance without the help of accommodation, not to mention vision at close range. Therefore, in a hypermetrope, the ciliary muscle, which is forced to be in its working state all the time, i.e. in contraction, is stronger and more voluminous than in people with other refractions.

Such hypertrophy of the continuously working ciliary muscle leads to an increase in the volume of the ciliary body as a whole. Therefore, when glaucoma occurs in a hypermetrope, it will often have a closed or narrow-angle shape, which is associated with the pressure on the root of the iris of the voluminous ciliary body, re-

sembling a triangle in section. Occupying a significant space in the posterior chamber, such a ciliary body promotes a more anterior position of the lens, which is also in a state of accommodative tension in a hypermetropic patient. The forward displacement of the entire iris-lens diaphragm that occurs, in this case, is fraught with the danger of a pupillary block and anterior chamber angle block.

The ciliary muscle in emmetropic refraction, which performs the function of accommodation mainly at close distances, is not so voluminous. Therefore, the ciliary body in an emmetropic patient in a meridional section has a club-shaped, less voluminous shape compared to a hypermetropic patient. This explains the fact that in emmetropic patients glaucoma is more often diagnosed as open-angle rather than closed-angle. The ciliary muscle is the least voluminous, stretched and even flat in people with myopic refraction, which is associated with very small accommodative efforts with this refraction.

Therefore, in myopes, glaucoma often has an open-angle form with a posterior position of the iridocrystalline diaphragm.

The third structural element of the mesodermal part of the ciliary body is a densely branched vascular network, due to which, in fact, its processes are formed. The arterial section of this network is represented by branches of two long posterior ciliary and seven anterior ciliary arteries.

There are no identical venous trunks for the system of long posterior ciliary arteries. Venous blood flows out through seven trunks of the anterior ciliary veins, sometimes also through recurrent anastomoses with choroidal vessels, naturally, only under the condition of the existence of such vessels. Knowledge of the anatomical architecture of the vascular system of the ciliary body, especially the location of the long posterior ciliary arteries, is necessary for every ophthalmic surgeon in order to avoid antiglaucoma surgical interventions in the periciliary space in the area of the horizontal meridian of the eye, where the long posterior ciliary arteries are located. An exception is targeted interventions on the arteries themselves (diathermocoagulation of the long posterior ciliary arteries, their cryoapplication) with the aim of reducing the production of intraocular fluid.

Knowing the anatomy well, the surgeon can easily detect one or the other ciliary artery. By cutting the conjunctiva above the place

where the internal and external rectus muscles of the eye attach to the sclera, separating the muscles and moving them aside, the vascular trunks can be seen through the sclera, corresponding to the muscle bed.

They shine through as dark stripes. These stripes are targeted by applying high or low temperatures.

In ophthalmological practice, for the same reasons of reducing the production of aqueous humor, a wider area of action is applied to the vascular system of the ciliary body (diathermocoagulation, cryoapplication). Since the vessels producing intraocular fluid are located in the processes of the ciliary body, the microsurgeon should know the projection zone of the processes on the external capsule of the eye. This zone is located 3-5 mm from the limbus, where the action of high or low temperatures should be concentrated.

The last structural element of the mesodermal part of the ciliary body is the elastic membrane, which is an anatomical continuation of Bruch's membrane of the choroid. It should be said that in the zone of the ciliary body this acellular, structureless membrane is much thinner than in the choroid, which is possibly associated with the function of the ciliary body to form intraocular fluid.

The ectodermal (retinal) zone of the ciliary body includes three elements that are a continuation of the retina and extend anteriorly to the root of the iris.

It is well known that in the place where the choroid passes into the ciliary body, there is the dentate line of the retina. Here the retina ceases to perform its visual function, being reduced to four layers (instead of ten).

The first layer of the retina—the layer of pigment epithelium—without undergoing noticeable changes passes over the ciliary body and, spreading along its flat and processive part, reaches the root of the iris. The remaining nine layers of the retina are reduced to one epithelial layer.

The latter, passing over to the ciliary body and lining it (also to the very root of the iris), receives the name of the ciliary epithelium. Figure 101 shows the pigment epithelium of the ciliary body and the non-pigmented ciliary epithelium in the region of the process of the ciliary body. The inner surface of the ciliary body facing the cavity of the eyeball is separated from the surrounding structures and the fluid of the posterior chamber by a very thin internal limiting mem-

brane, which is an anatomical continuation of the structureless internal limiting plate of the retina. Thin fibers and membranous elements of the ciliary ligament are attached to the internal limiting membrane of the ciliary body.

The necessity of describing the anatomical elements of the ciliary body with attention to the presence of sections of different origins - mesodermal and ectodermal - is due to the functional features of the formation of intraocular fluid due to each of the indicated sections.

The characterization of the anatomy and physiology of the ciliary body, as the main structure that ensures the production of intraocular fluid, would be incomplete without a description of its innervation.

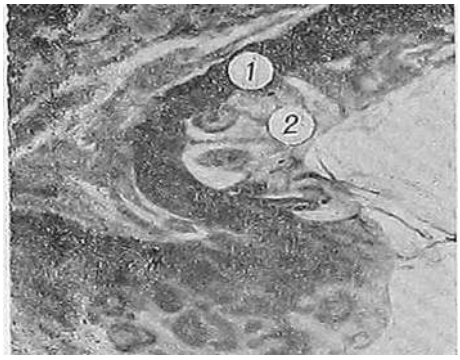

Fig. 101. **Process of the ciliary body. Magnification — 400 X:**
1—pigmented epithelium of the ciliary body; 2—non-pigmented ciliary epithelium

Possessing diverse functions, the ciliary body has a richly developed network of nerve fibers, the endings of which perform a very diverse innervation.

The ciliary body is surrounded by a rich nerve plexus located in the periciliary space. It is formed by three or four trunks of the long ciliary nerves, which in turn are branches of the nasociliary nerve.

The long ciliary nerves bring their sensory and trophic functions to the periciliary plexus. The periciliary plexus also receives four to six trunks of the short ciliary nerves, which extend from the ciliary ganglion located behind the eyeball. The short ciliary nerves are of a mixed type. They perform a sensory function, motor innervation, which ensures contraction of the ciliary muscle during the act of accommodation, and vasomotor innervation, which is so necessary for the normal formation of intraocular fluid by the ciliary body.

Finally, the short ciliary nerves also have a trophic function due to the presence of a sympathetic component in their trunks.

The rich sensory innervation of the ciliary body, originating from two systems (the long ciliary and short ciliary nerves), requires a very careful attitude to its tissue during manipulations carried out in glaucoma with the aim of reduc-

ing the production of intraocular fluid.

Such fairly common interventions in hypersecretory glaucoma at present are diathermocoagulation, as well as cryoapplication of the ciliary body (see above). We performed the latter bloodlessly using the transconjunctival approach. Observing the work of ophthalmic surgeons both in Moscow clinics and in ophthalmological institutions in other cities, we have noticed that some of them, when performing cryoapplication, are content with only instillation, or at best, application anesthesia, using a 0.5% - 1% solution of dicaine for this purpose.

It should be noted that such anesthesia is absolutely unacceptable for interventions on the richly innervated ciliary body (in fact, on the periciliary nerve plexus).

It will only turn off the pain sensitivity of the conjunctiva.

Manipulations on the ciliary body require good conduction retrobulbar anesthesia with a 1-2% solution of novocaine. All other surgical antiglaucoma interventions in the periciliary space should be performed exclusively against the background of such anesthesia (in combination with instillation and application anesthesia).

These include ciliary trepanation of the sclera with the restoration of the depth of the anterior chamber, cyclodialysis, iridocycloretraction surgery, dilation of the peri-ciliary space with a strip of autosclera and other microsurgical interventions.

The complex anatomical organization of the ciliary body ensures the no less complex process of production of intraocular fluid, which performs the necessary transport function, providing nutrients and microelements to many internal structures of the eyeball.

Despite numerous experimental and clinical studies, the mechanism of the formation of intraocular fluid by the ciliary body has not yet been fully studied. It can be regarded as a very complex set of processes that are carried out by cell membranes during the transport of various chemical substances and the liquid part of the blood through them.

The established fact of the dual mechanism of production of intraocular fluid is reliable: on the one hand, due to the work of the mesodermal and, on the other hand, due to the work of the ectodermal portion of the ciliary body.

The first mechanism is quite passive, the second is active.

The mesodermal portion performs the function of moisture formation by filtering the liquid part of the blood, producing approximately 25% of the total volume of moisture formed by the cil-

iary body. The so-called "sodium pump" plays a major role in the implementation of the filtration function of the ciliary body. Sodium ions, as well as chlorine ions, leaving the bloodstream into the cavity of the eyeball, make the moisture of the posterior chamber around the ciliary body hypertonic.

The consequence of this is filtration into the posterior chamber by osmosis of the liquid part of the blood. However, this process is not a mechanical pumping of moisture from the vessels of the ciliary body. The filtered fluid cannot be considered analogous to blood plasma.

The composition of the fluid is not constant. It changes as it circulates in the eye and performs complex trophic functions in relation to the vitreous body, lens, cornea and tissues that form the angle of the anterior chamber.

The fluid located in the circumference of the ciliary body processes is called primary. Its specific gravity in relation to blood plasma is significantly less (the weight of the fluid is 1.005, the weight of blood plasma is 1.024).

The fluid contains significantly more chlorides and lactic acid than plasma, but it contains little protein, urea, and glucose.

The intraocular fluid is very rich in vitamins compared to blood. In particular, its content of such an important vitamin for the vital activity of the tissue elements of the eyeball, especially the lens, as vitamin "C", increases in comparison with blood plasma by 15 times.

A significantly larger volume of intraocular fluid (75%) is formed due to the effort of the ectodermal part of the ciliary body, specifically, the ciliary epithelium, which performs the function of secreting fluid (along with its resorption).

Secreting epithelial cells sometimes appear swollen, vacuolated, which can be observed both in the process of producing biomicrocycloscopy and in histomicoscopic studies. In some cases related to hypersecretory glaucoma, we had to see the inner surface of the ciliary body, mainly its process part, strewn with rounded translucent cystic elements.

Based on the above, we consider it appropriate to dwell on the terminology legalized in ophthalmological practice. When there is excessive formation of intraocular fluid, it is customary to speak of hypersecretory glaucoma.

However, is such terminology always correct? Excess intraocular fluid is formed not only as a result of its increased secretion by the ciliary epithelium but also as a result of increased filtration of the liquid

part of the blood, the reduction of which is the purpose of the above-mentioned effects on the ciliary body. For these reasons, it is more correct to characterize the increased inflow of intraocular fluid as a consequence of the intensification of both mechanisms of moisture formation, with the same right calling glaucoma not only hypersecretory but also hyperfiltration. Considering the cumbersomeness of the terminology, its simplification should be considered rational. In particular, for practical work with wide use, the term "glaucoma of increased inflow" can be proposed, in contrast to the term "glaucoma of decreased outflow", implying the inflow and outflow of intraocular fluid.

Entering the eye mainly from one source - the ciliary body - the fluid flows out of the cavity of the eyeball along three anatomical structures - three outflow paths. The main, leading outflow path is the anterior one. It takes on the removal of about 85% of all the fluid, pouring it ultimately into the venous system of the eyeball and orbit. Several sections are distinguished in this path, and microsurgical pathogenetically substantiated antiglaucoma interventions pursue the goal of eliminating obstacles in that section of this path where the cause of the disorder of the outflow of intraocular fluid is concentrated.

We believe that the first section on the path of the intraocular fluid is not the trabecular apparatus of the angle of the anterior chamber, but the area of the pupillary opening, through which the posterior chamber of the eye communicates with the anterior chamber. Continuous contractile movements of the pupil undoubtedly contribute to a more active movement of fluid from one chamber to another. When the pupil dilates, the next portion of the fluid that ends up in its lumen is, by the subsequent contractile movement that ensures the narrowing of the pupil, squeezed out of the posterior chamber into the anterior.

Recognition of this mechanism of chamber fluid movement justifies the prohibition of the prescription of strict miotic regimens in the drug treatment complex of glaucoma patients.

We had to observe cases when a patient was prescribed a 1% solution of pilocarpine in the form of instillations 6 times a day in combination with the instillation of a 6% solution of pilocarpine at night.

Sometimes eserine, phosphocol were added to these prescriptions.

This led to the emergence of a sharply expressed drug miosis, the

development of cysts of the pigment border of the pupil. The outflow of intraocular fluid from the posterior chamber to the anterior became difficult (and the more the prescription of miotical means was increased, the greater this difficulty was).

As a result, the fluid accumulating in the posterior chamber, not having the proper outflow into the anterior chamber, began to press on the posterior surface of the iris. Under this pressure, the iris moved forward, and the root of the iris began to close the identification zones of the angle of the anterior chamber. In the end, open-angle glaucoma turned into closed-angle glaucoma. Softening the miotic regimen in these cases helps to normalize the ophthalmotonus due to a more active flow of fluid into the anterior chamber through the pupillary opening. For these reasons, one should also welcome the monthly drug unloading of glaucoma patients carried out by some doctors, which is expressed in the complete cancellation of mystical drugs for 1-2 and even 3 days.

In case of an increase in intraocular pressure, it is useful to prescribe distracting osmotherapy agents (diacarb, glycerol, magnesium sulfate, hot foot baths, mustard plasters on the back of the head).

All of the above, taking into account the undesirable consequences of mystical pupillary block, also makes our recommendation to prescribe so-called "eye exercises" to a glaucoma patient justified.

Its essence lies in moving the point of fixation of the gaze along the line of sight (see above). The patient is recommended to shift his gaze from distant objects to nearby ones, without concentrating visual efforts on one of them for a long time, in particular on the text of a book, newspaper, etc. Work at close range should alternate with rest for the eyes by directing the gaze to a distant object. The resulting change in the tension of the ciliary muscle in synergism changes the tension of the sphincter of the pupil. The pupil periodically narrows and dilates. This promotes a more active migration of fluid from the posterior chamber to the anterior. In addition, contraction and relaxation of the ciliary muscle is known to promote the outflow of intraocular fluid through the drainage system of the angle of the anterior chamber.

NOT – (Miotic immobility) of the pupil in glaucoma leads to complete immobilization of the iris, as a result of which an intimate fusion of its posterior pigment sheet

with the anterior capsule of the lens occurs. This is usually observed by ophthalmic surgeons during antiglaucoma surgery with the iris-tweezers. Sometimes it is possible to grasp only the stroma sheet of the iris with iris-tweezers, and the iridectomy is not penetrating. In the lumen of the stromal coloboma, the posterior pigment sheets of the iris remain, which does not allow the iris-tweezers to be considered qualitative.

Miotic immobility of the pupil in combination with planar fusion of the posterior surface of the iris with the anterior capsule of the lens is also fraught with other, more serious complications that can develop in the postoperative period. We are talking about pupillary block and subsequent hypertension due to the lack of the ability to drain intraocular fluid from the posterior chamber to the anterior, which most often occurs when creating a small non-penetrating coloboma of the iris. For these reasons, we strongly recommend in microsurgery to excise a piece of the iris of a sufficient area during iridectomies so that the created hole can take on the drainage function of removing intraocular fluid.

In this case, even if a pupillary block develops, it will not lead to an increase in intraocular pressure in the postoperative period, since the function of the pupil will be taken over by a well-executed coloboma of the iris. A fairly reliable prophylaxis of pupillary block and miotic pruritus in the postoperative period is the administration (already on the operating table, immediately after the end of the antiglaucoma operation) of a 1% solution of atropine instillation. The pupil, if the operation was preceded by strict miotic regimens, must be dilated, posterior synechiae, if possible, torn.

It is necessary to take all measures to ensure that the natural anatomical path of the flow of intraocular fluid from the posterior chamber to the anterior through the pupillary opening is restored. This is a kind of "reconstructive" element in glaucoma microsurgery, performed with the help of therapeutic measures, which once again demonstrates the inseparable connection of surgical and therapeutic elements in a single treatment tactic for helping a patient with primary glaucoma. A very important section of the anterior outflow path of intraocular fluid is the angle of the anterior chamber (Fig. 102), the central structure of which is considered to be the circular venous sinus located in the limbus, called the Schlemm's canal. Of interest is the

feature that the Schlemm's canal is not equidistant from the cornea along its entire length, which is very important to know for a surgeon who often has to deal with the Schlemm's canal during microsurgical interventions.

The Schlemm's canal is the most distant (at a distance of 1.0-1.5 mm) from the cornea in its upper and lower sections.

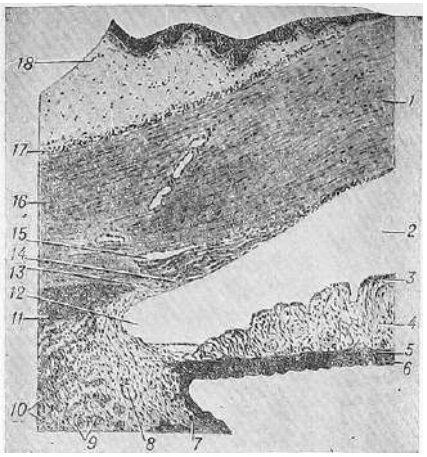

Fig. 102. **The angle of the anterior chamber and the structures surrounding it (according to V.M.Shepkalova)**
1- cornea; 2- anterior chamber; 3- anterior border layer of iris; 4- iris stroma; 5, 6- Posterior pigment epithelium of iris; 7- ciliary process; 8- major arterial circle of iris; 9, 10, 11- ciliary muscle; 12- angle recess; 13- scleral spur; 14- trabecular meshwork (anterior aqueous outflow pathway); 15- schlemm's canal; 16- sclera; 17- episcleral vessels; 18- conjunctiva

As for the lateral sections, they are somewhat closer to the cornea. The lumen of the Schlemm's canal, moreover, according to anatomical data, often branching, is only 0.25 mm. The characteristics of the drainage system should begin with a very thin (0.1 mm) inner wall of the Schlemm's canal, called the trabecula or trabeculae.

This section of the anterior outflow tract of intraocular fluid is a system of narrow slit-shaped lumens filled with mucopolysaccharides and separated by thin layers of fibrous tissue with an endothelial lining. Due to the special elasticity of the fibrous tissue, the slits that collapse during fluctuations in intraocular pressure can easily restore their lumen, which helps maintain normal ophthalmotonus.

The entire complex system of trabeculae during the work of removing intraocular fluid resembles to some extent an accordion.

From the standpoint of a clinician who has to examine the trabeculum by bio-micro-gonioscopic methods in the process of diagnosing and differentially diagnosing glaucoma, as well as performing pathogenetically oriented microsurgical operations on the trabeculum in glaucoma, it is useful to distinguish three parts in it. The innermost part is the uveal portion of the trabeculum (Fig. 103). It consists of several layers of collagen

strands originating from the anterior surface of the ciliary body and the root of the iris. They are directed in the form of bushy fibers to the anterior border ring of Schlemm's canal and are attached here.

In children, the uveal part of the trabecula is well expressed, with age it atrophies.

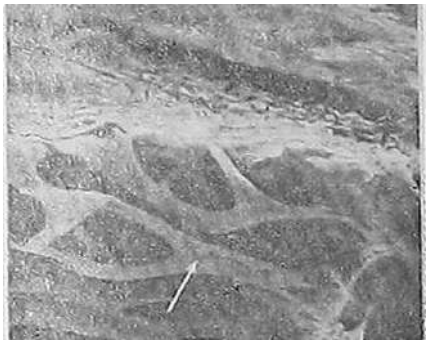

Fig. 103. **The upper part of the trabecular web in scanning electron microscopy (according to M.M.Krasnov)**

This part of the trabecula, more often known among ophthalmologists as the supporting framework of the angle of the anterior chamber or the pectineal ligament, cannot be considered a structure that provides real resistance to the outflow of intraocular fluid. The next part of the trabecula, which is called the corneoscleral, is in close contact with the uveal portion. It is significantly wider and more powerful than the uveal part, consists of 5-10 intertwined plates with openings both between them and in them (Fig. 104). Pigment granules can often be seen in the openings.

Each plate basically contains a thin collagen fiber surrounded by homogeneous elastic tissue with an endothelial lining of the surface. The very name "corneoscleral trabeculae" characterizes the course and direction of these elements, as if stretched between the cornea and sclera, i.e. between the anterior and posterior border rings of the Schlemm's canal, diverging from front to back like a fan.

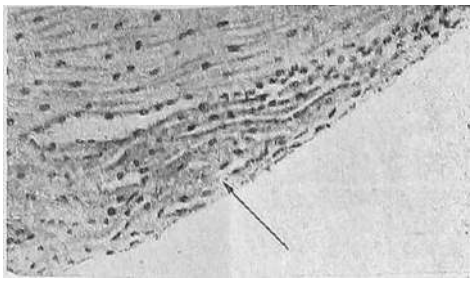

Fig. 104. **Corneal part of the trabecular apparatus**

In the direction of the Schlemm's canal, the corneoscleral trabeculae pass into the juxtacanalicular tissue.

This is actually the inner wall of the Schlemm's canal, the surface of which, facing directly into the lumen of the sinus, is lined with a continuous layer of endothelium (Fig. 105). This endothelial lining is

of great importance in the implementation of the transport of intraocular fluid.

The transport of aqueous humor through the uveal and corneoscleral parts of the trabecula can be imagined as a passive process, when the fluid, drawn by the difference in intraocular and venous pressure (intraocular pressure is 18 mm, and venous pressure is 8-10 mm Hg), passes through the trabecula, overcoming its resistance mainly in the corneoscleral section.

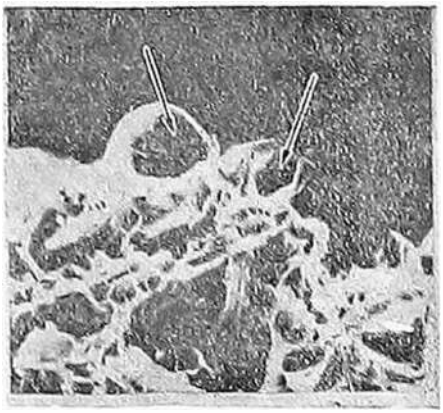

Fig. 105. **Juxtacanalicular part and endothelium lining Schlemm's canal under scanning electron microscopy (according to M.M.Krasnov)**

The outflow of fluid through the endothelial part of the trabecula, according to many researchers of eye hydrodynamics, is active. This is not a simple leakage of fluid through the cracks of the juxtacanalicular tissue and through the endothelial barrier. Endothelial cells, which, according to electron microscopy data, communicate on one hand with the intertrabecular gaps (fountain spaces), and on the other hand with the lumen of Schlemm's canal, actively draw fluid into themselves from the fountain spaces, then releasing it into the lumen of Schlemm's canal (Fig. 106).

This continuous operation of endothelial cells in the process of fluid transport resembles the function of a pump that transfers fluid from one container to another (into Schlemm's canal).

This information is absolutely necessary for a microsurgeon performing pathogenetically justified interventions (trabeculotomy, trabeculectomy) for the retention of trabecular glaucoma.

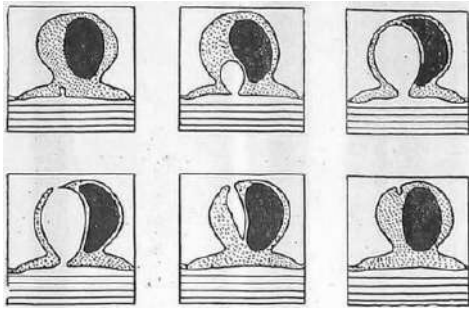

Fig. 106. **Scheme of enucleation of intraocular fluid and Schlemm's canal through the endothelium (according to M.M.Krasnov)**

Schlemm's canal is a circular sinus, slightly oval in shape, located in projection according to the border between the middle and posterior parts of the trabecula. Individual variants of a more anterior and more posterior position of the venous sinus are also observed. Variants of the anatomical structure of the canal with a double and even triple bed are described. We also had to encounter such a feature of the sinus during histomicroscopic studies.

The lumen of Schlemm's canal is far from being open along its entire length and is unevenly uniform. There are normally bridges in it. Under the influence of increased intraocular pressure, the collapse of Schlemm's canal may occur, which is associated with deflection and even a certain invagination of the elastic inner wall of the canal into its lumen.

Without touching on the issues of pathology, it should be said that a normal, open-lumen Schlemm's canal, like a trabecula, also resists the outflow of fluid, and, according to A.P.Nesterov, A.Ya.Bunin and L.A.Katsnelson (1974), this resistance is even greater than in the trabecula and amounts to 50%. The authors attribute 25% to the resistance to the outflow of fluid through the trabecular part. The remaining 25% is due to the resistance that the intrascleral pathways provide to the outflowing fluid. They, in the amount of 20-30 venous trunks, begin from the outer wall of Schlemm's canal, mainly from its posterior half (Fig. 107). In the thickness of the sclera, the indicated canals form an intrascleral plexus, which, through new collectors, connects with a second similar plexus, but located more superficially in the episclera, which is why it is called episcleral.

The work of a microsurgeon cannot be of high quality without knowledge of this anatomical detail.

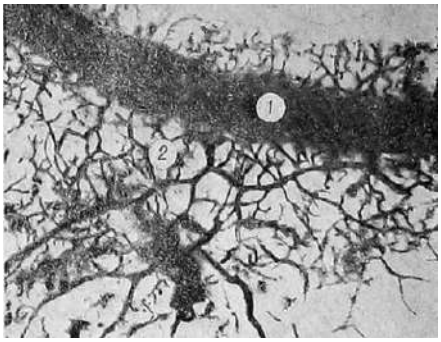

Fig. 107. **Drainage system of the eye during perfusion of the eyeball with a solution of Indian ink (according to L.P.Nesterov). Magnification - X-5: 1 - Schlemm's canal; 2 - dense network of intraocular vessels**

The intrascleral pathogenetic form of primary glaucoma dictates

the necessity of removing the obstruction to the outflow of intraocular fluid precisely at the level of the outer wall of the Schlemm's canal (sinusotomy operation) and its intrascleral collectors. Detection under a microscope in the stratified sclera of these vessels, which drain the transparent chamber fluid, is a good reference point for detecting the Schlemm's canal itself and surgical manipulations on its outer wall. From the episcleral plexus, the intraocular fluid ultimately enters the anterior ciliary veins, which also drain blood from the tissue of the iris and ciliary body.

These episcleral veins are clearly visible under the conjunctiva, where they exit through special openings in the sclera - emissaries.

Sometimes the collector vessels that branch off from Schlemm's canal, bypassing the scleral and episcleral plexuses, exit through the emissaries of the sclera under the conjunctiva and here flow into the anterior ciliary veins. These colorless, seemingly empty vessels are called aqueous or watery veins. They can be seen in 80% of cases in healthy eyes, with hypersecretory glaucoma and less often with retention glaucoma. The veins are usually located along the horizontal meridian of the eye 2-3 mm from the limbus (Fig. 108).

It is difficult to find an aqueous vein at once. Certain experience and training in the method of biomicroscopy of the eye are required since it is this method (and only it) that is capable of detecting aqueous veins. The search for an aqueous vein should begin with the recipient vein, into which it flows. The anterior ciliary vein, which has received fluid from the aqueous vein, can be recognized by its very light (scarlet) color, which is due to the dilution of venous blood by the intraocular fluid. Following the course of the recipient vein (towards the limbus), one can also see an aqueous vein. Finding aqueous veins in glaucoma has a certain practical significance. This is relevant to cases of hypersecretory glaucoma when excessive production of intraocular fluid requires either a decrease in its inflow or an increase (activation) of its outflow. No less significant is the presence of aqueous veins in retention-type glaucoma, caused by a pathological process in the trabecular or intrascleral part of the anterior outflow pathway of intraocular fluid, as well as in the Schlemm's canal zone.

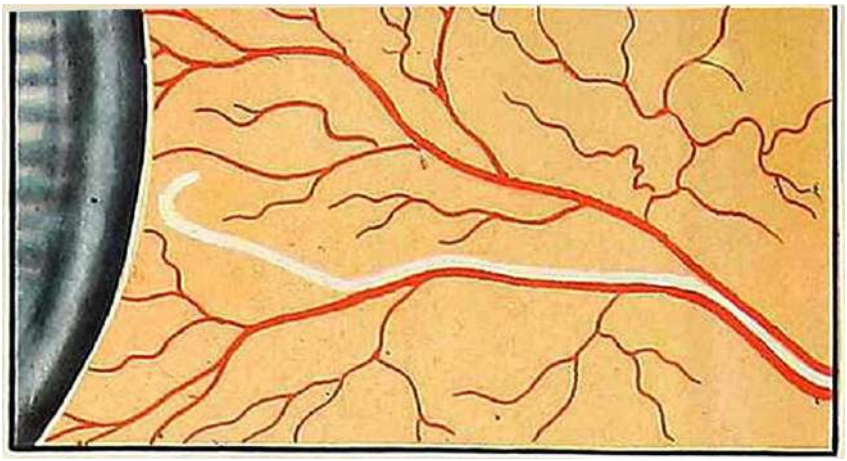

Fig. 108. **Aqueous (watery) vein**

The functional capacity of the drainage pathway can be judged not only by the coefficient of ease of outflow of intraocular fluid but to a certain extent by the change in the color of the aqueous vein and the trunks of the anterior ciliary veins located near it when the recipient vein is compressed by the edge of a glass rod, which receives both the aqueous vein and the branches of the anterior ciliary veins.

If the intraocular fluid from the aqueous vein enters the lumen of the surrounding venous trunks, displacing the blood from them, this indicates a fairly good functional capacity of the anterior outflow path. But if the observer sees that the aqueous vein has acquired a dark red color due to venous blood entering it, this is a sign of insufficient hydrodynamic force in the anterior outflow path of the intraocular fluid.

With increased intraocular pressure, we usually simplify the described test. By pressing through the upper eyelid on the eyeball, we observe the behavior of the episcleral (anterior ciliary) veins. If the blood from the venous trunks disappears due to the activation of the influx of chamber fluid into them, and the veins become discolored, this is a favorable sign of the absence of pronounced organic changes in the drainage system of the anterior outflow path of intraocular fluid. The constancy of the dark red color of the veins during the procedure of pressing on the eyeball, in glaucoma with pronounced stagnant injection, indicates a complete blockade of some

sections of the drainage system of the eye.

This circumstance is an indication for differential diagnostics of the retention form (angular, pretrabecular, trabecular, intrascleral) and selection of the type of pathogenetically oriented microsurgical intervention in accordance with the examination data.

The most pronounced negative phenomenon of the ebb is in an acute attack of primary glaucoma when there is an angular block of the angle due to the shutdown of the trabecular apparatus due to the adjacency of the root of the iris to it.

The positive phenomenon of the outflow described above allows us to recommend self-massage of the eye to patients with glaucoma (with hypersecretory and retention forms). In the morning, after washing their hands and closing their eyes, the patient massages the eyeball in the cornea area with the index or middle fingers in gentle circular motions through the upper eyelid for 1-3 minutes. The procedure reduces elevated intraocular pressure by 5-10 mm Hg.

It can be repeated 2-3 times a day against the background of a drug regimen. Self-massage of the eye is completely harmless. It activates the drainage system of the eye, increasing the outflow of intraocular fluid.

The same massage procedure, but performed by a doctor through the lower eyelid with the patient's eye open, can be recommended in the postoperative period (and even without delay if possible!), if the antiglaucoma surgery did not produce the desired effect due to the blockade of the created outflow path of the intraocular fluid by fibrin threads, edematous surrounding tissues.

After discharge from the hospital, to prevent excessive scarring of the filtering surgical canal (after the operation of filtering iridotomy, sinusotomy, trabeculectomy, sinus trabeculectomy), the patient can perform the massage procedure independently.

The second outflow path of the intraocular fluid is the middle path, called the uveoscleral. It is associated with the still poorly studied lymphatic system of the eyeball and orbit. This pathway is not active, taking on the removal of about 10% of the total volume of intraocular fluid.

Following the uveoscleral pathway, it penetrates from the angle of the anterior chamber through the ciliary body along the fibers of the meridional part of the ciliary muscle, through the spongy tissue

of the root of the iris into the periciliary space. It is possible that the fluid that gets here is absorbed by the venous system of the richly vascularized ciliary body. However, a more realistic path is the outflow of fluid into the lymphatic Tenon's space and the orbit along the trunks of the anterior ciliary arteries and veins through emissaries in the sclera.

Since the periciliary space communicates with the perichorioid space, there is a possibility of the fluid passing here with its subsequent outflow along the emissaries of the vortex veins into the Tenon's space and the lymphatic system of the orbit.

Real activation of the uveoscleral outflow pathway by medication is unlikely. Somewhat greater hopes should be placed on microsurgical interventions of the cyclodialysis type (iridocycloretraction, expansion of the perineal space due to autosclera).

Intraocular fluid has the ability to flow out through the third - posterior pathway. It, like the uveoscleral pathway, is lymphatic, draining a very small amount of intraocular fluid.

This pathway begins in the perivasal spaces of the retina, which accompany the vascular bundle to the optic disc and further in its trunk part. The optic nerve is known to be enveloped in three meninges.

The dura mater is interwoven in front with Tenon's capsule and sclera, the pia mater is intimately fused with the trunk of the optic nerve and even penetrates its tissue, separating bundles of nerve fibers. Between the dura and pia mater is the arachnoid mater. The space between all three membranes is called the intermeningeal (intervaginal) space. It is divided into the subdural and subarachnoid zones. The intervaginal space is filled with cranial cerebrospinal fluid.

The central vascular bundle of the retina passes through the central parts of the optic nerve trunk for 7-12 mm from the eyeball, but then it changes its direction, parting with the optic nerve.

At this point, the central artery of the retina enters the optic nerve at a right angle, and the central vein of the retina exits it, pouring blood into the superior ophthalmic vein.

At the point where the central vascular bundle of the retina passes through the intrathecal space of the optic nerve, the intraocular fluid flowing along its course (along the perivascular spaces) merges with the intrathecal cerebrospinal fluid.

Then the aqueous humor enters the cisterns of the brain, but

possibly also into Tenon's space, since the dura mater covering the optic nerve, as mentioned above, joins near the posterior pole of the eyeball with Tenon's capsule.

In addition, there is an opinion that there are gaps between the in-

The driving force for the outflow of intraocular fluid along the posterior pathway is the difference in pressure (intraocular, intermembranous around the optic nerve and intracranial). This difference is expressed by figures of the order of 15-17 mm Hg; 6-11 mm Hg; 5-10 mm Hg.

Naturally, this third pathway for the outflow of intraocular fluid cannot be an anatomical basis for microsurgical interventions.

Chapter 4

BIOMICROGONIOSCOPY IN THE CHOICE, IMPLEMENTATION AND EVALUATION OF PATHOGENETICALLY ORIENTED MICROSURGICAL OPERATIONS IN PRIMARY GLAUCOMAS

The angle of the anterior chamber is a complex anatomical formation where four membranes interact (the cornea passes into the tervaginal spaces of the optic nerve and the orbital tissues, mainly when the central arteries and retinal vein pass through the dura mater surrounding the optic nerve, which allows the fluid to flow directly into the orbital cavity.
sclera and the iris into the ciliary body). It performs a very important function, being the main path for the outflow of intraocular fluid from the eye cavity.

The study of this structure is possible only with the help of a special research method - biomicrogonioscopy, which every ophthalmologist is currently required to master. Biomicrogonoscopy is necessary first of all in glaucoma since the chamber angle most often and seriously changes in this eye disease. Research in recent years (Member of the USSR Academy of Medical Sciences M.M.Krasnov, 1974-1978) has established that changes in the drainage (filtering) system of the anterior chamber angle determine the pathogenesis of primary glaucoma, which allows us to speak of glaucoma not in the singular, but as a sum of glaucomas with different pathogenetic characteristics. The method allows us to determine the pathogenesis and even understand the etiology of some cases of secondary glaucomas, the occurrence of which is as-

sociated with a number of diseases of the eyeball, such as iridocyclitis, iridocyclic dystrophies, iridocyclic neoplasms, retinal vein thrombosis, and traumatic damage to the organ of vision.

Examination of the chamber angle in the process of daily work of an ophthalmologist is necessary for the purpose of timely diagnostics of glaucomas, conducting differential diagnosis between primary and secondary glaucomas. When diagnosing primary glaucoma, the task of a practicing physician is to recognize the glaucomatous process from the pathogenetic positions, on the basis of which the choice of rational therapy is determined. All these tasks can be solved using the method of biomicrogonioscopy.

The indicated technique is the only one of its kind and irreplaceable when it comes to choosing the type of pathogenetically oriented microsurgical intervention.

Conducting the pathogenetically oriented operation on the drainage system of the chamber angle often requires the use of the biomicrogonioscopic method on the operating table. The above technique is necessary to evaluate the results of the intervention performed on the structures of the anterior chamber angle, which is usually performed by an ophthalmic surgeon in the late postoperative period. Such a study is especially necessary in cases where surgical intervention does not lead to the desired result in terms of reducing intraocular pressure. Examination of the anterior chamber angle allows us to identify errors made by the doctor in surgical technique, to see changes caused by the complicated course of the operation itself or the postoperative period, which makes it possible to outline ways to eliminate them.

Before we move on to the presentation of these important questions, in particular the question of choosing and performing microsurgical operations for glaucoma on the basis of biomicroscopic data, we consider it necessary to dwell on some elements of the methodological plan.

Examination of the angle of the anterior chamber can be carried out with the help of goniolenses (Fig. 109), using bright light and magnifying systems of various types, from a binocular loupe to an operating microscope. The goniolens is inserted into the conjunctival sac after instillation of 0.5–1% dicaine solution for anesthesia.



Fig. 109. **Goniolenses**

The patient is in a horizontal position (on a couch, or operating table). The role of the goniolens is to neutralize the optical system of the cornea, which allows the rays of light reflected by the structures of the angle to leave the eyeball, i.e. pass through the cornea and the goniolens and become visible to the researcher.

The latter should be positioned opposite the zone of the angle being examined (the lower part of the angle should be viewed from the upper position - from the side of the upper parts of the limbus; the upper part of the angle - from the position of the lower limbus). The same applies to the study of the lateral segments of the angle. At present, various models of gonio lenses are used only in the process of performing surgical interventions on the Schlemm's canal, in particular in congenital glaucoma (goniotrabeculotomy, goniopuncture in various modifications).

For diagnostic and differential diagnostic purposes in glaucoma, as well as for selecting appropriate local drug therapy (including cholinomimetic, anticholinesterase, and adrenomimetic agents), the method of biomicrogonioscopy is used with gonioscopes and slit lamps. This same method (and exclusively this one) is also indicated when selecting pathogenetically oriented microsurgical operations in primary glaucoma.

All existing gonioscopes are a goniolens (the contact part of the gonioscope, placed on the cornea or on the cornea and the adjacent part of the sclera) and an attachment attached to the goniolens, the inner side of which is mirrored. Due to the goniolens (contact part), the light rays coming from the chamber angle are removed from the eye, after which they fall on the mirror of the inner surface of the gonioscope, in which the researcher sees the image of the structures of the angle. This image is projected in the mirror located opposite the section of the angle being studied. Existing gonioscopes differ mainly in the number of mirrors on the inner surface of the gonioscope attachment. There are single-, double-, triple- and quadruple-mirror models. The more mirrors, the fewer circular movements the gonio-

scope has to make to examine all segments of the chamber angle. The domestic industry produces the single-mirror gonioscope of M.M.Krasnov (Fig. 110).



Fig. 110. **M.M.Krasnov's Gonioscope (a) Common view; (b) Ray tracing diagram**

It is miniature, convenient and easy to use, which is of considerable importance for a novice ophthalmologist. When working with this model, the doctor sees only two images (the central one, including the cornea, iris, pupil and anterior surface of the lens, and the inclined - mirror, where the picture of the anterior chamber angle is reflected). By moving the gonioscope along the perimeter of the angle (rotating it around the axis), it is possible to gradually examine all areas of the chamber bay and the angle itself.

Boinigen's gonioscope is called pyramidal because the optical part of the device is a four-sided glass pyramid with mirror surfaces (Fig. 111). The angle of inclination of each of them is 62.5°. The top of the pyramid is cut off and has the shape of a spherical surface with a radius of curvature of 8 mm. This is the corneal part of the pyramid. Its edge is rounded to avoid injury to the cornea. A screw ring is attached to the gonioscope, which rotates in such a way that the contact (corneal) curvature of the gonioscope can rise and fall. The slit-like space between it and the cornea is filled with tear fluid according to the laws of capillarity, as a result of which there is no need to use a contact solution.

The glass pyramid of the gonioscope is enclosed in a translucent frame (speculum), which has a scleral surface. It is not necessary to use this frame during the examination. When working with a pyramidal gonioscope, it is possible to examine all sides of the chamber angle with almost no rotation of the pyramid around its axis. This is convenient, and in addition, it

spares the corneal epithelium.The disadvantages of the device include its excessively large dimensions, since the pyramid contains not one but four reflecting surfaces, corresponding to the upper, lower, outer and inner segments of the anterior chamber angle. In addition, the device is heavy (10 g) and in this respect cannot be compared with a domestic gonioscope.

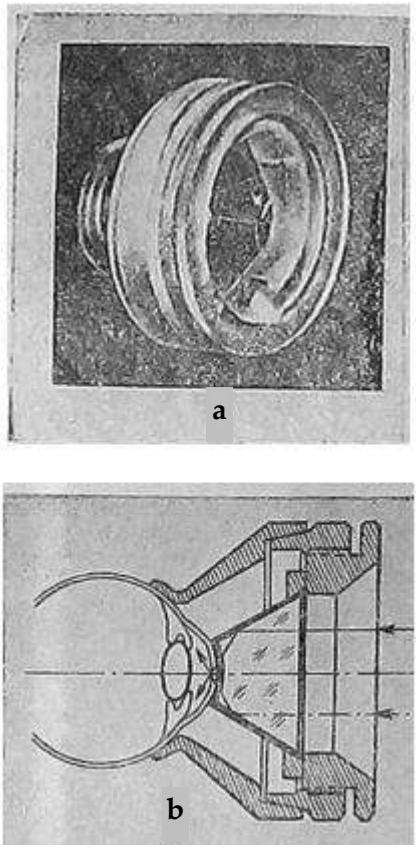

Fig. 111. **Boyningen gonioscope: (a) Common view; (b) Ray tracing diagram**

A novice specialist should be given advice concerning the sequence of implementation of the biomicrogonioscopic technique. First, it is necessary to perform instillation anesthesia of the conjunctival cavity and cornea (preferably both eyes, for the sake of calmer patient behavior during the examination), disinfect the contact part of the gonioscope with a swab soaked in a solution of rivanol, furacilin, boric acid (under no circumstances use alcohol or ether for this purpose and do not boil the gonioscope).

Next, seat the patient in front of a slit lamp, using 9-18X magnification of the microscope, it is necessary to find an image of the anterior segment of the eye in the field of view of the microscope.

It is possible to begin searching for an image under lower magnification, about 5X, which will significantly simplify the task. The researcher should remember that the slit lamp illuminator should be positioned to the right of him, at a small angle of biomicroscopy, approximately 10-15°.

After such preliminary preparation, a gonioscope is inserted behind the eyelids of the subject, similar to how an eyelid speculum is usually inserted into the conjunctival cavity. It is more advanta-

geous to begin examining the chamber angle with the gonioscope mirror positioned at the top since in this position the lower section of the angle will be visible.

It is important to examine primarily the lower segment of the angle since the angle in this place is always physiologically wider than the upper sections. The latter are usually narrower due to the pressure exerted by the upper eyelid on the cornea. It is easier for a beginning researcher to understand the physiological and pathological pictures that open up to his gaze if the angle is wider than narrow.

One should not think that by inserting a gonioscope behind the eyelids one can immediately see in the mirror the image of the corner of the anterior chamber. By looking through the microscope and the contact part of the gonioscope at the eye, the doctor will see the same elements of the eyeball (cornea, iris, lens) that he saw during ordinary biomicroscopy, without a gonioscope. In order to bring the gonioscope picture into the field of view, one should place a mirror image of the corner in front of the microscope objective. To do this (with the mirror positioned at the top), it is necessary to either move the frontal position of the slit lamp downwards (the patient's head and eyeball with the gonioscope inserted into the conjunctival cavity will move downwards), or raise the illuminator and microscope of the slit lamp upwards (to the level of the gonioscope mirror) by rotating the flywheel located in the lower sections of the stand on which the illuminator and microscope are mounted.

The slit lamp in the process of biomicrogonoscopy makes it possible to use diffuse light (with a wide illumination slit) and direct focal illumination in a narrow beam of light in order to obtain an optical section of the tissues that form the angle, which is sometimes necessary to determine the width of the angle. Parfocal and oscillatory types of illumination are also applicable.

It should be noted that to master the method of bio-microgonioscopy, sufficient skills in the technique of eye biomicroscopy are necessary. Let us analyze the normal biomicrogonoscopy picture in diffuse and direct focal light, without which it is impossible to solve issues related to the diagnosis of pathogenetic varieties of primary glaucomas and, moreover, the choice and implementation of microsurgical pathogenetically oriented anti-glaucoma interventions. If we focus on the image of the lower

sections of the angle, which is more rational (see above), and begin to examine the bio-microgonoscopic picture with the reflecting mirror of the goinoscope in the upper position, following the gaze in the direction from top to bottom, a bright picture of the identification zones or stripes (belts) of the chamber angle will open up before the examiner. They appear as if inserted, inscribed between the cornea and iris (Fig. 112). The cornea 1 has the appearance of a transparent dome, which, like the firmament, hangs over the structures of the angle and the iris (brown, blue, gray, depending on the color of the eyes), located horizontally or slightly obliquely.

The first zone 2 is called the anterior border ring of Schwalbe, after the scientist who described it. This zone is an elevation on the inner surface of the cornea with a fairly steep slope descending towards the chamber angle. This elevation is a circular connective tissue ring formed at the end of Descemet's membrane and corresponding to the limbus region. The anterior border ring differs from the adjacent corneal tissue by its whiter color and lower transparency. It should be noted that when examining in direct focal light, it is possible to obtain an optical section of the Schwalbe ring.

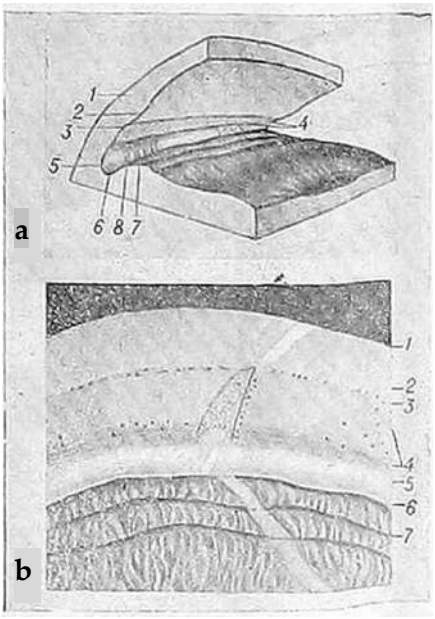

Fig. 112. **Identification zones of the anterior chamber angle and their surrounding structures:**
(a) Diagrammatic illustration;
(b) Slit-lamp optical section view

Unlike the corneal section, it is less transparent; however, the entire thickness of the tissue forming the border ring is usually quite clearly visible. Within the Schwalbe ring, especially in those areas where it borders the cornea, thin radial branches of vessels related to the marginal looped network of the cornea are clearly visible. As for age-related changes in the above-mentioned recognition zone of the chamber angle, they are usually expressed in the appearance of fairly large lumps of pigment on the

Schwalbe ring. This pigmentation is a consequence of the disintegration of the pigment that normally fills the cells of the posterior pigment layer of the iris. The pigment brought by the flow of intraocular fluid is more often found on the Schwalbe ring in the lower segment of the chamber angle.

The anterior border ring is followed by the notch zone 3. The notch is a narrow groove that is the boundary between the anterior border ring of Schwalbe and the next zone of corneoscleral trabeculae. The notch usually emphasizes the protrusion of Schwalbe's ring into the anterior chamber compared to other identifying zones of the angle. In the notch area, sometimes even in young people, pigment deposits are visible. The next zone of corneoscleral trabeculae and Schlemm's canal 4 always attracts the close attention of researchers, since it plays an important role in the drainage of intraocular fluid. The zone of corneoscleral trabeculae and Schlemm's canal is one of the main links in the complex system of fluid outflow from the anterior chamber.

From here the fluid flows into the intrascleral plexuses and then into the anterior ciliary veins. The inner wall of Schlemm's canal, facing the anterior chamber, is porous. It consists of very thin connective tissue fibers - corneoscleral trabeculae or crossbars. These trabeculae occupy a wider area than Schlemm's canal itself. Corneoscleral trabeculae start from the cornea and are attached to the sclera, which is where their name comes from. The crossbars consist of the same elements as the cornea. They arise as a result of the splitting of the corneal tissue into separate bundles. The intertwined corneoscleral trabeculae form a mass of openings through which the intraocular fluid seeps into Schlemm's canal. The trabecular zone, when viewed from the inside, i.e. from the camera side, has the appearance of a pale gray or brownish, fairly wide strip with smooth borders. It has a greater or lesser degree of transparency.

When examined with high magnification and sufficient illumination, it is possible to examine the trabeculae themselves. They have a matte shade and are generally characterized by a peculiar mesh pattern. When examined in focal light, it is possible to obtain an optical section of the trabecular zone. It has the shape of a triangle and is semi-transparent. The narrowest part, the apex of the triangle, is located near the anterior border ring of Schwalbe, i.e., where

the corneoscleral trabeculae arise. The wider part of the section, the base of the triangle, borders on the next identification zone of the anterior chamber angle, called the scleral spur.

The anterior edge of the optical section of the trabeculae is differentiated quite clearly, especially if the trabecular zone is slightly pigmented, the posterior edge is not as clearly visible. With age, thickening of the trabeculae and a decrease in the transparency of the entire trabecular zone as a whole are usually observed. In elderly people, trabeculae are often pigmented, but in most cases, this does not affect the functional capacity of the chamber angle.

In the deep sections of the trabecular zone, behind the translucent plates of the trabeculae, one can see the contours of the translucent Schlemm's canal 4, which is distinguished by more saturated color, often having a grayish or brownish tint. Schlemm's canal is especially well distinguished in cases of the presence of delicate physiological pigmentation. In some individuals, it is almost completely indistinguishable. Normally, Schlemm's canal does not contain blood.

During the examination, if the scleral part of the gonioscope presses too hard on the eyeball, blood appears in the Schlemm's canal. This is due to the retrograde blood flow due to the gonioscope squeezing the anterior ciliary veins. When blood appears in the Schlemm's canal, it stands out as a bright red stripe, sharply contrasting with the surrounding identification zones of the angle.

Despite numerous indications by histologists that the Schlemm's canal is characterized by branching, this is not observed during gonioscopic examination, even when the Schlemm's canal is filled with blood and is very clearly visible during examination.

In the process of studying the normal picture of the zone of corneoscleral trabeculae and Schlemm's canal in different age groups, we personally (530 observations) and a number of other researchers established the fact of different levels of projection of Schlemm's canal, different levels of its location behind the corneoscleral septum. The canal can be localized in the middle sections of the trabecula, but in some individuals, it is located more in front, that is, more corneally differentiating at the beginning of the optical section of the trabecular septum. There are cases of the posterior (scleral) location of the canal, which almost

merges with the identification zone following the trabeculae. These features of the localization of the venous sinus should be known to every practicing ophthalmologist in order to exclude errors in the diagnosis of the form of primary glaucoma in accordance with the new classification of primary glaucomas. This should also be remembered when determining the localization of Schlemm's canal on the operating table during pathogenetically oriented microsurgical interventions.

The microgonoscopic picture is supplemented by the zone following the trabeculum, which is called the scleral spur or posterior border ring 5.

The scleral spur has the appearance of a bright white strip with a slightly shiny tendinous shade. It serves as a place of attachment of the meridional portion of the ciliary muscle to the sclera. This zone received its name of scleral spur due to the fact that on histological sections the sclera in this area has the shape of a triangle, which really resembles a spur in appearance.

The scleral spur limits the Schlemm's canal from behind, forming its posterior wall. It is followed by the ciliary body band 6.

This zone is part of the anterior surface of the ciliary body, protruding into the region of the angle of the anterior chamber. It has a variable width, a brownish or yellowish color; the intensity of the color is usually associated with the color of the iris. With a dark iris, the ciliary body band has a more saturated brown color; with a light iris, it is usually sandy. This zone is characterized by a wavy relief, a kind of delicate radial striation. When examining the ciliary band in patients with a light iris, it is sometimes possible to notice a single bright red vessel here (the large arterial circle of the iris). It is located strictly concentrically to the limbus, in places disappearing into the tissue of the ciliary body, appearing on its surface again in the form of a kind of arc or arch. With age, the appearance of the ciliary body stripe changes greatly. In young individuals, it stands out among the other recognition zones of the angle by its brightest color. In older people, the ciliary body stripe becomes discolored and acquires an ash-gray appearance. The surface of the stripe loses its radial striation. The entire zone seems to be covered with delicate fibrous tissue. The ciliary body stripe passes into the peripheral part of the iris, called

the root 7. The root of the iris, when examining the upper and lower segments of the angle, appears to be located horizontally or slightly obliquely, and when examining the lateral segments, it is obliquely vertical.

It has a different color and a relief expressed to varying degrees. The root of the iris is separated from the rest of its parts by one of the most peripheral contraction grooves. In the area of the root, thin radial branches of vessels are sometimes visible, going from the ciliary zone in the direction of the central parts of the iris. They usually soon disappear among the trabecular tissue of the iris.

The identification bands of the chamber angle are sometimes partially hidden due to the presence of the pectineal ligament 8. The fibers of the ligament are thin bridges starting from the area of the root of the iris and going in the direction of the corneoscleral trabeculae, where they are attached, sometimes in the area of the anterior border ring. At the place of attachment, the elements of the ligament usually branch like a tree. The fibers of the pectineal ligament are the color of the iris and resemble the fibers of its stroma in appearance.

In elderly people, elements of the pectineal ligament are less common during gonioscopy. The reason for this is unknown. It is possible that this circumstance is associated with atrophy of the mesodermal tissue of the iris, from which the fibers of the pectineal ligament arise.

In practical work, it is necessary to be able to distinguish the pectineal ligament from corneoscleral trabeculae, as well as pathological elements, in particular from goniosyne. Depending on the extent to which the root of the iris approaches the cornea, i.e. covers the identification zones of the angle, several variants of the width (shape) of the angle of the anterior chamber are distinguished (Fig. 113).

Wide angle 1. With a wide angle, the iris does not cover the identifying zones of the angle at all. They are all clearly visible, including the ciliary body strip, which appears quite wide. A wide angle is observed in myopia, aphakia.

A medium-wide angle 2 is characterized by the fact that with it the root of the iris actively covers the ciliary body strip, which is barely distinguishable. The medium-wide angle is the most common form of the chamber angle in the norm.



Fig. 113. **Shape (width) of the anterior chamber angle**

Narrow angle 3. In the presence of a narrow angle, the identification zones can at best be seen only up to the trabecular zone. The ciliary body band and the scleral spur are covered by the root of the iris. Sometimes the zone of corneoscleral trabeculae is also partially covered, which makes it impossible to see the Schlemm's canal, especially if it is located posteriorly. A narrow angle is more common in hypermetropic people.

A closed *angle 4* is characterized by the fact that the iris covers all its zones and is adjacent to the anterior borderline of Schwalbe or even to the cornea itself. The closed form of the angle is pathological. It occurs in an acute attack of primary glaucoma, in cases of angle blockage by a neoplasm of the iris.

In the presence of poorly defined, blurred identification zones of the angle, when they are poorly distinguishable, it is difficult to judge its shape. In these cases, during the examination it is necessary to use a narrow slit, trying to obtain an optical section of the tissues forming the angle.

In the optical section, the dividing zones usually stand out in more relief, differing not only in color but also in their contours. The anterior border ring of Schwalbe, as a rule, protrudes forward - into the chamber - and seems to hang over the trabecular zone.

In the optical section, it can be observed that in the area of the notch, a bifurcation, stratification of the incident beam of light occurs with the formation of the so-called

"light fork". Using the "fork" as a reference point, one can judge the shape of the angle in some measure by the degree of its distance from the root of the iris. If the "fork" is located high above the root of the iris, then the angle is classified as wide. With a narrow angle of the anterior chamber, the "fork" almost contacts the iris.

The closed angle of the anterior chamber is characterized by the fact that the root of the iris touches the place where the beam of light bifurcates - the "fork", which seems to rest against the root of the iris, sometimes partially hiding behind it.

It should be noted that the width of the angle along its entire circumference is not the same: in the lower sections the angle is wider, and in the upper sections, as a rule, narrower. With age, in many individuals, the chamber angle tends to narrow due to the fact that the root of the iris begins to move more actively towards the chamber. However, the degree of narrowing of the angle is insignificant, the trabecular zone remains free, and its drainage capacity does not suffer. According to our observations, there is no direct relationship between the depth of the anterior chamber and the width of the angle.

Many years of experience in teaching the biomicrogonioscopic section at the Ophthalmology Department of the Central Institute of Ophthalmology and the Environment allows us to give some recommendations for beginning ophthalmologists.

Examination of the anterior chamber angle should be carried out in a certain sequence. First of all, it is advisable to determine the shape of the angle, and then assess the condition of each of the identification zones.

When examining the anterior border ring of Schwalbe, it is necessary to take into account the degree of its transparency, the presence or absence of pigmentation, exudate, since in the area of the ring and notch there are all the conditions for the deposition and retention of cellular elements and other inclusions located in the moisture of the anterior chamber. Particular attention should be paid to the examination of the trabecular zone and the Schlemm's canal differentiating in its depth, since changes in the filtration apparatus of the anterior chamber angle are of great importance in all cases of increased intraocular pressure, both primary and secondary.

It is necessary to take into account the degree of transparency of

the entire trabecular triangle as a whole, the type of trabeculae themselves, the presence or absence of their sclerosis, edema, the degree and nature of pigmentation.

When studying the condition of Schlemm's canal, attention should be paid to its width, contours, color. Examination of the ciliary body strip should reveal its width, color, the presence or absence of normal radial striation of the tissue, and the presence or absence of signs of sclerosis.

Thus, when conducting biomicrogonioscopy, the doctor faces several tasks: he must examine the chamber bay and decide whether there are loops in the foam pathological formations, determine the shape of the angle being examined, identify changes in its identification zones and be able to correctly decipher these changes.

We will tell, based on our own experience, literary sources, and also from the position of teachers introducing new guidelines for pathogenetically oriented microsurgery for glaucoma into the practice of an ophthalmologist, about the choice, based on biomicrogonioscopy, of the type of surgical intervention.

Our observations of more than 300 patients with primary glaucoma allow us to say with confidence that the choice of the intervention method should be based on a specific diagnosis of the pathogenetic form of primary glaucoma. In other words, surgical intervention must be performed precisely on the anatomical area where the outflow of intraocular fluid is impaired.

In accordance with the classification of primary glaucoma, approved by the Main Directorate of Medical and Preventive Care of the USSR Ministry of Health in 1977, three forms of glaucoma are distinguished: I - closed-angle, II - open-angle, and III - mixed.

An acute attack of glaucoma and suspected glaucoma are distinguished separately. A sign of closed-angle glaucoma is the inability to see the Schlemm's canal during biomicrogonioscopic examination due to its blockage by the root of the iris. This may occur with a closed and narrow angle, especially if the Schlemm's canal is located posteriorly.

A sign of open-angle glaucoma is a finding during a gonioscopic examination of the Schlemm's canal. Such a picture is possible in the case of a wide, medium-wide and even narrow angle. The latter applies to cases with an anterior (corneal) location of the Schlemm's canal.

A mixed form of glaucoma from a gonioscopy position is characterized by partial closure of the chamber angle; an open but narrow (slit-like) angle. It should be mentioned that this important section of the classification of primary glaucoma, analyzed by us from a gonioscopic perspective, needs to be supplemented. For the sake of completeness of the presentation of the materials it should be said that the pathogenesis of primary glaucomas according to the theory of Academician M.M.Krasnov can have two main mechanisms: excessive production (hypersecretion) of intraocular fluid by the ciliary body and difficulty in the outflow (retention) of fluid, which can occur in various anatomical areas of the anterior outflow tract. Hypersecretory glaucoma is characterized by an open angle of the anterior chamber. Biomicrogonoscopy does not reveal any pathological changes in the area of the angle and, in particular, in the structural elements of the drainage system (the angle is normal).

This is confirmed by the data of the topographic study. In accordance with the pathogenesis of hypertension in this case, surgical intervention should be aimed at limiting the production of intraocular fluid, for which purpose operations such as cyclodiathermy, cryoapplication of the ciliary body, diathermy of the long posterior ciliary arteries are undertaken. Surgical (microsurgical) intervention on the structures of the anterior chamber angle should be considered not indicated.

Retention glaucoma, in accordance with the new classification, as stated above, is divided into closed-angle, open-angle and mixed forms. Depending on the location of retention (according to Academician M.M.Krasnov), types of angular, pretrabecular, trabecular and intrascleral glaucoma are distinguished.

What biomicrogonioscopic signs characterize these pathogenetic varieties of glaucoma and what types of surgical intervention can the biomicrogonioscopic method of examination be used to guide?

During biomicrogonioscopic examination, the Schlemm's canal is usually not visible in this glaucoma (Fig. 114). The statement of this fact cannot be considered final. The identification zones of the chamber angle (Schlemm's canal) can be switched off (blocked) by the root of the iris in different ways.



Fig. 114. **Retention angle-closure angular glaucoma**

A distinction is made between functional and organic angle blocks. The difference between them can be established during a bio-micro-gonioscopic examination by pressing the contact part of the gonioscope on the eyeball. If, due to an increase in the volume of intraocular fluid in the chamber bay, the angle opens and Schlemm's canal becomes visible, the block can be considered functional, associated with insufficient outflow of intraocular fluid from the posterior chamber to the anterior. Excess fluid in the posterior chamber with drug-induced miosis (pupillary block), exerting pressure on the root of the iris from behind, causes narrowing of the chamber angle. In this case, basal iridectomy should be considered pathogenetically justified, as well as laser iridectomy. A variant of laser gonioplasty is possible, which, due to the onset of scarring of the iris, promotes gradual opening of the chamber angle and elimination of the miotic pupillary block.

The absence of an opening of the angle of the anterior chamber when pressure is applied to the eye with a gonioscope during a bio-micro-gonioscopic examination indicates an organic, i.e. synechial block of the angle.

Goniosynechiae, which usually occur after an acute attack of glaucoma, in glaucoma with "shortening of the angle" due to the fusion of the root of the iris with one of the identification zones of the angle of the anterior chamber, can be filiform, cone-shaped, trapezoidal and circular in nature.

The presence of high (trabecular or corneal) circular goniosynechia dictates the need to choose among microsurgical interventions the iridocycloretraction operation, aimed at eliminating the synechial block and opening the angle of the anterior chamber. In this case, angular dilation with the help of iridoretraction in combination with iridectomy is also indicated.

Pretrabecular retention glaucoma is characterized by the presence of tissue in front of the trabecula that interferes with the outflow

of intraocular fluid. This can most often be embryonic mesodermal tissue, which causes the development of congenital glaucoma.

In accordance with the new classification of primary glaucoma, exfoliative and pigmentary glaucoma are also included here.

The embryonic tissue has the appearance of felt or bushy branches, masking the trabeculae and Schlemm's canal. Filling the Schlemm's canal with blood from the anterior ciliary veins during the examination, which reveals it as a red stripe, should guide the ophthalmic surgeon to eliminate pretrabecular retention, which is performed using a goniotomy operation. The absence of blood in the Schlemm's canal when the anterior ciliary veins are compressed with a gonioscope or special pressure is applied to the jugular veins also reveals intrascleral retention, which is observed in the advanced (advanced) stage of congenital glaucoma, orienting the surgeon to perform goniopuncture (thermogoniopuncture), that is, a fistulizing operation that does not literally belong to pathogenetic operations.

Primary glaucoma with trabecular rete, according to the new classification, is classified by its form as open-angle or mixed glaucoma. It is characterized by the presence of sclerosis and thickening of the trabeculae of the anterior chamber filtration apparatus in biomicroscopic examination. In cases of sclerosis, the trabecular zone acquires a peculiar, somewhat shiny, tendinous appearance. The transparency of the trabecular network is reduced, as evidenced by the blurring and shading of the posterior edge of the optical section of the trabeculae. Behind the thickened trabeculae, Schlemm's iris is poorly discernible, except in cases where it is filled with blood. The presence of blood in the Schlemm's canal is a sure sign of good functional capacity of the intrascleral outflow tracts and confirms the presence of trabecular (possibly also pretrabecular) retention. The second biomicrogonioscopic sign of trabecular glaucoma is the detection of exogenous pigmentation on the surface of the trabecula facing the anterior chamber (Fig. 115). Degeneration of the corneoscleral trabeculae, narrowing and obliteration of the intertrabecular spaces, which is actually the reason for the retention of the outflowing fluid, does not allow pigment granules to penetrate into the trabecular web. They are deposited on the surface of the trabecula in the form of lumps and clumps, quite voluminous and clearly visible during examination.



Fig. 115. **Retention open-angle trabecular glaucoma**

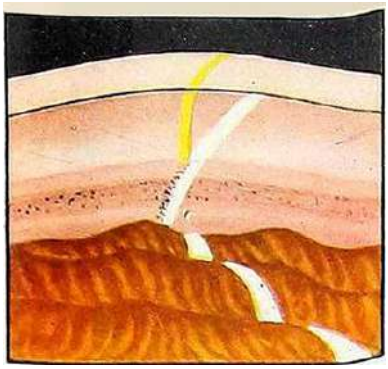

Fig. 116. **Retention open-angle and intrascleral glaucoma**

The diagnosis of trabecular glaucoma based on the above symptoms should serve as a basis for pathogenetically justified opening (or resection) of the inner wall of the Schlemm's canal by performing trabeculotomy, trabeculectomy, tunnel trabeculotomy, laser goniopuncture.

The intrascleral type of retention form of open-angle or mixed glaucoma is characterized in the process of biomicroscopic examination by the presence of normal identification zones of the angle, good condition of the trabecular weave, the possibility of obtaining an optical section of the trabecula, in the depth of which a finely dispersed dust-like pigment is differentiated, called endogenous pigment (Fig. 116).

Penetration of pigment into the deep sections of the intertrabecular spaces, right up to the inner wall of the Schlemm canal, is indirect evidence of good outflow of intraocular fluid into the Schlemm canal, which, to a certain extent, excludes trabecular retention and suggests the presence of retention in the intrascleral fluid outflow pathways.

A negative gonioscopy test by filling the Schlemm's canal with blood usually strengthens the assumption of intrascleral retention and justifies the opening of the outer wall of the Schlemm's canal (sinusotomy operation). Naturally, the listed pathogenetic forms of retention in an isolated "pure" form can be encountered only in the very initial stage of the glaucomatous process. Since surgical intervention for glaucoma has to be performed

more often in the pronounced phase of the disease.

An ophthalmic surgeon often encounters combined forms of retention (angular and trabecular retention, trabecular and intrascleral retention forms).

According to L.I.Kolesnikova, such combinations occur in 43% of cases. This is an indication for performing combined pathogenetically oriented operations (sinusotomy in combination with trabeculotomy or trabeculectomy, sinus-trabeculectomy operation). Since the complex of microsurgical manipulations in the production of pathogenetically oriented operations for primary glaucoma often includes an element of peripheral iridectomy (and sometimes iridectomy is the only factor in eliminating retention, as, for example, in angular glaucoma with a functional block of the angle), we considered it necessary to include the concept of the profile or level of the posterior chamber in the presentation of the materials of this topic.

In the process of performing peripheral iridectomy, surgeons sometimes encounter a fact that seems incomprehensible at first glance: after excision of the iris, no outflow of intraocular fluid from the posterior chamber to the anterior chamber is visible through the resulting opening. This indicates that the resulting iris coloboma has not connected both chambers of the eye in the form of a tunnel. This means that the task of the intervention has not been accomplished: a new path for the outflow of fluid from the posterior chamber to the anterior chamber has not been implemented. In these cases, the surgeon sees dark-brown tissue in the lumen of the iris coloboma, and when it is excised, significant bleeding occurs, and usually the more actively the doctor excises this tissue, the more anxiety he experiences. The described picture is observed, as a rule, in the presence of a high profile (or level) of the posterior chamber, when the processes of the ciliary body, and in particular the first main process, called the cornice of the ciliary body, is located on the posterior surface of the iris. In these conditions, the posterior chamber is located higher (more neutral) than the root of the iris and the angle of the anterior chamber (Fig. 117).

This anatomical variant of the location of the posterior chamber can be found out in advance, during biomicrogonoscopy. This is evidenced by the presence of an unusually wide, voluminous strip of the ciliary body, which is clearly visible in glaucoma with a wide or

medium-wide angle. In these cases, iridectomy should be performed not in the root part of the iris, but somewhat more neutrally, sometimes even near the zone of demarcation of its ciliary and pupillary belts.

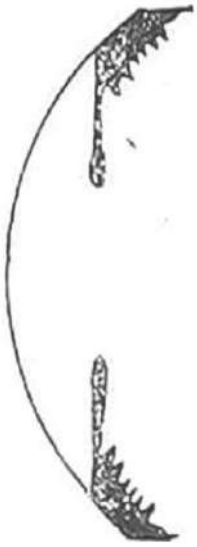

Fig. 117. **High profile (level) of the rear camera**

Then the goal of iridectomy will be achieved: the formed opening in the iris will correspond to the location of the posterior chamber (despite its high profile), and both chambers (anterior and posterior) will be connected.

The method of biomicrogonioscopy, as stated above, guides the ophthalmic surgeon not only in the correct choice of microsurgical intervention. However, in a number of cases, it is irreplaceable in its implementation.

Recent studies indicate that most operations for open-angle retention glaucoma (sinusotomy, sinusectomy, trabeculotomy, trabeculectomy, sinus-trabeculectomy) should be performed at the level of the Schlemm's canal.

This is the anatomical substrate of their pathogenetic nature, when the outer or inner walls of the Schlemm's capsule are dissected or excised, depending on the level of retention, and sometimes the entire Schlemm's canal (naturally, in a certain area limited by the area of the surgical intervention). Displacing the incisions of the outer capsule of the eye forward or backward in relation to the position of the Schlemm's canal already deprives the surgical intervention of elements of the pathogenetic approach and leads to worse results in terms of reducing intraocular pressure.

It is not easy to perform an operation precisely at the level of the Schlemm's canal since it is not visible after the conjunctival incision, separation of the conjunctival flap, and even after cutting out the scleral flap. It was said above that the Schlemm's canal can have a middle, anterior, or posterior location (and in glaucoma, due to some

stretching, under the influence of increased intraocular pressure, of the external capsule of the eye, it can generally have a somewhat atypical localization). Therefore, ophthalmic surgeons, when performing the microsurgical pathogenetic intervention, are forced to pay primary attention to searching for the Schlemm's canal in the tissues. To do this, it is necessary to make radial incisions in the sclera around the limbus, engage in stratification of the scleral tissue, and arrange "undermining" until drops of fluid appear in the surgical field flowing from the Schlemm's canal.

This fact is usually perceived by the surgeon with a sigh of relief (finally, Schlemm's canal has been found), which allows for further manipulations related to sinus- or trabeculotomy (ectomy). In the case of trabecular glaucoma, when Schlemm's canal on the operating table is "dry" (intraocular fluid practically cannot seep into it due to organic changes in the trabecular tissue and obliteration of the intertrabecular slits), the search for the venous sinus, i.e. Schlemm's canal, on the operating table is even more difficult. Meanwhile, the task can be significantly simplified if the biomicrogonioscopy method is used for the correct localization of the Schlemm's canal.

By placing the contact part of the pre-disinfected gonioscope on the cornea, in the reflecting mirror, which in this situation should be located below, it is possible to see the identification zones of the upper segment of the chamber angle, where the antiglaucoma intervention is performed. Among them, Schlemm's canal stands out with its more saturated color, especially in the presence of exogenous or endogenous pigmentation. By pressing with a thin probe, surgical or injection needle on the sclera at the base of the separated flap in the area of the upper limbus and moving the needle slightly more corneal or scleral, it is possible to accurately establish the projection of the Schlemm's canal on the sclera: the area of its depression is visible in the gonioscope mirror. The projection zone should be marked with a stroke of brilliant green solution. To search for the localization of Schlemm's canal, another method can be used, which is preferred by the All-Union Scientific Research Institute of Eye Diseases of the USSR. Taking a sharply curved surgical needle 4-5 mm long, pierce (not through!) the sclera in the area of the supposed localization of the Schlemm's canal: the body of the needle is clearly visible in the opposite mirror of the gonioscope

(Fig. 118). If the needle shines through not at the level of the Schlemm's canal, but somewhat higher or lower, then it is punctured and the puncture procedure is repeated in a more corneal or scleral displacement. Having established the projection area of the Schlemm's canal, the needle can pierce the layers of the sclera, leaving a thread of virgin silk (supramid, biosuture) in the canal after passing the needle, which is a good (indelible, unlike marking with a brilliant green solution) reference point for the localization of the Schlemm's canal.

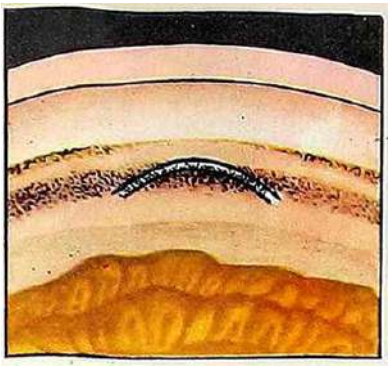

Fig. 118. **Localization of Schlemm's canal using a surgical needle**

The role of the biomicrogonioscopy method in the system of microsurgery of primary glaucoma is not exhausted by the above. Each surgeon is usually interested in the result of the operation he has performed, especially in cases where this result is not entirely satisfactory. After a month from the day of the operation, and sometimes earlier, especially if you use a gonioscope without a haptic (supporting) scleral ring pressing on the eyeball, you can perform biomicrogonioscopy in the area of the surgical intervention. A successfully performed operation of peripheral iridotomy in closed-angle glaucoma with a functional block of the angle is characterized by the presence of a through (without leaving the posterior pigment sheet) coloboma of the iris, in the lumen of which 2 - 3 processes of the ciliary body are usually differentiated. The processes lie behind the iris, without blocking the lumen of its coloboma (Fig. 119).

After a successful and sometimes functional block of the angle by the root of the iris, glaucoma from a closed-angle often changes to an open-angle form. The operation of iridocycloretraction, performed with an organic block of the angle, is characterized by the presence in the chamber bay, at a distance from each other, of two scleral strips-struts, between which a gaping cyclopalese gap is differentiated (Fig. 120).

The angle in this place, if the operation is successfully per-

formed, is wide open, and the fluid has the ability to flow out both through the natural-anterior pathway (intertrabecular fissures, Schlemm's canal and intrascleral collectors), and through the cyclodialysis gap, flowing into the perineal space, with further migration along the uveoscleral outflow tract. The success of the operation is assessed by the presence of a gaping, fringed-edged gap in the area of localization of the Schlemm's canal (Fig. 121).

After sinusotomies, significant changes in the area of the chamber angle are usually not detected. Only with close biomicrogonioscopic examination in the area of dissection (excision) of the outer wall of the Schlemm's canal through its inner wall containing delicate small granules of endogenous pigment, can a translucent dark strip (zone of scleral resection) be detected.

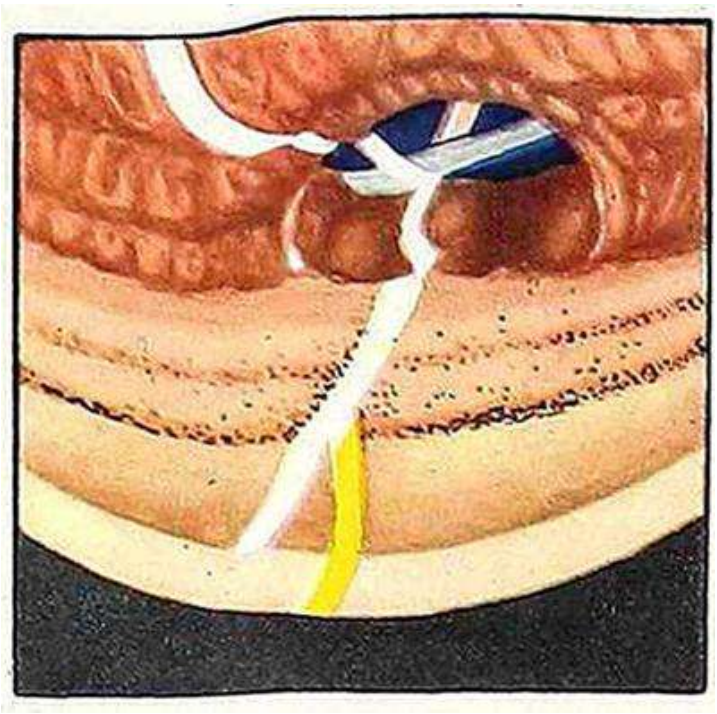

Fig. 119. **Anterior chamber angle after antiglaucoma iridectomy (angular retention eliminated)**

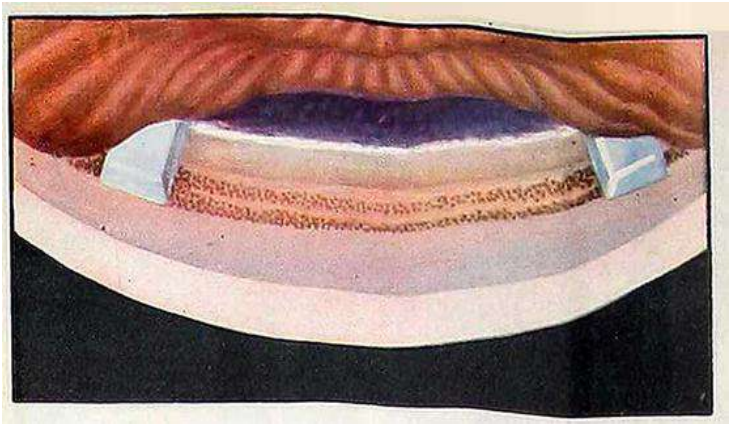

Fig. 120. **Anterior chamber angle following iridocycloretraction (synechial angle blockage corrected)**

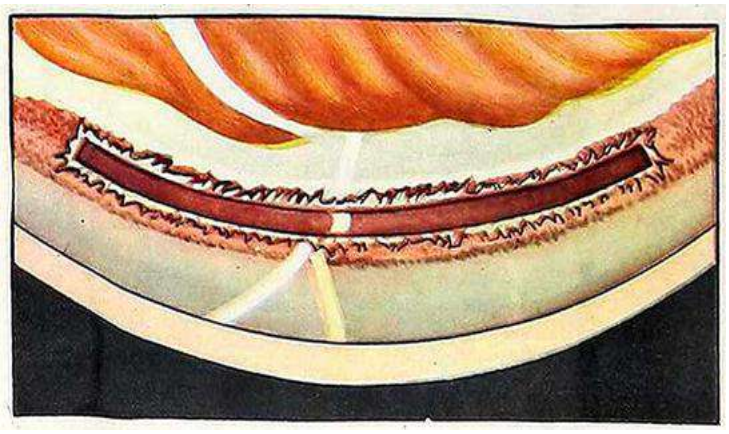

Fig. 121. **Anterior chamber angle after trabeculotomy**

The operation of sinus trabeculectomy (complete excision of the Schlemm's canal) is characterized by the presence of a gaping, smooth-edged, dark-colored slit in the area of localization of the Schlemm's canal. In this case, in recent cases, during biomicrogonioscopic examination, there may be a reflux of blood into the anterior chamber. Biomicrogonioscopic examination clearly establishes the reasons for the unsuccessful outcome of microsurgical intervention. This is, first of all, an error in the choice of the intervention area,

when incisions in the external capsule of the eye are made more corneal or scleral than the localization of the corneoscleral trabeculae and the Schlemm's canal; there is a fusion of the incisions and openings made, especially if they are in an incorrect position, with connective tissue, the formation of powerful goniosynechiae, blockade of the opening (as happens in cases of its displacement towards the sclera) by the processes of the ciliary body, the equator of the lens).

In case of unsuccessfully performed iridectomy with a functional block of the angle, which happens due to incomplete excision of the iris in the presence of a high profile of the posterior chamber, blockage of the opening by tissue of the ciliary body, the lens - opening of the chamber angle is not observed. In the lumen of the iris coloboma, either its posterior pigment sheet or processes of the ciliary body blocking the created opening are most often visible. The outcome of the iridocycloretraction operation cannot be assessed positively either in the absence of obvious withdrawal of strips of sclera into the chamber bay, which is accompanied by the absence of a visible cycloidal slit. The organic block of the angle in such cases is usually not eliminated. The identification of the described biomicroscopic symptoms in the postoperative period allows us to analyze the errors made in surgical technique in order to outline ways to eliminate them.

The presented materials allow us to strongly recommend the introduction of the biomicrogonioscopic method into the practice of all ophthalmologists-microsurgeons, especially in the selection, production and evaluation of pathogenetically substantiated antiglaucoma operations. The biomicrogonioscopic procedure is generally well tolerated by patients, is not accompanied by pain and does not cause, with proper mastery of the technique, undesirable consequences.

Chapter 5

MICROSURGERY OF PENETRATING WOUNDS AND CONTUSIONS OF THE EYEBALL

At present, microsurgery is widely used to treat penetrating wounds of the eyeball, as well as a number of clinical manifestations of a contusion nature. Its importance for ophthalmic traumatology is difficult to overestimate. The use of an operating micro-

scope, microsurgical instruments, microneedles and appropriate suture material has allowed not only to transfer the surgery of penetrating wounds of the eyeball to a qualitatively higher level but also to create new technical methods previously inaccessible in the conditions of traditional surgery.

First of all, microsurgical technology is used in providing emergency care to patients with damage to the visual organ. High demands are now placed on the quality of treatment of eyeball wounds. The meaning of surgical treatment is not only to seal the wound of the external capsule of the eye. It is necessary to give the treatment an anatomical and reconstructive character with a single-stage intervention on the iris, lens, and vitreous body. Such a targeted approach to the volume of microsurgical emergency care for eye trauma ultimately ensures the prevention of many complications, eliminates repeated operations in the post-traumatic period and generally ensures higher visual functions.

In the ophthalmological literature of our country and abroad over the last 5-7 years a significant number of works have appeared, testifying to the great interest in this problem, its successes and difficulties.

Over these years of work in the field of microsurgery, we have also accumulated a certain clinical experience, there are long-term observations of patients and histological studies of injured eyes. Therefore, setting out the issues of microsurgery for injuries of the eyeball, we will be guided not only by the guidelines of literary sources but will evaluate them from the point of view of our own experience, as well as the possibilities of applying recommendations in the practice of ordinary ophthalmological institutions at the level of departments of regional and city hospitals.

The issues of microsurgery of penetrating wounds of the eyeball are presented by us in the same section with contusions since there is no fundamental difference in the technical execution of microsurgical manipulations in them. It was stated above that in the treatment of contusions, the surgical component is mandatory if the contusion is accompanied by a rupture of the sclera. This is the first clinical situation that will be given attention in this section. The second is microsurgery of the iris, which is encountered quite often not only in cases of penetrating wounds but also in contusions of the eyeball.

The main task of surgical treatment of wounds of the eye-

ball is the maximum restoration of normal anatomical relationships of the structures and tissues of the eye in order to preserve its visual function.

Depending on the time of surgical treatment of wounds of the eyeball, which has passed since the injury, several of its variants can be distinguished. Focusing on the guidelines of general surgery, taking into account the morphology of the wound process, a distinction is made between primary urgent surgical treatment, carried out on the first day after the injury, primary delayed - it is carried out in the period from the second to the fourth day; treatment in the following days (up to a month) is called secondary. These details should be remembered when making a record of the operation: regarding an eye injury in the medical history.

It is known that the earlier the wound is treated, the less the risk of complications in the post-traumatic period. However, as the analysis of the work of eye hospitals shows, about 12% of patients with trauma (usually domestic) seek medical help late, not on the first day (E.N.Vilshansky, 1979). In these cases, delayed or secondary surgical treatment is performed.

Microsurgical treatment of wounds of the eyeball is preceded by a detailed clinical, electrophysiological, radiological examination, as well as taking the necessary material from the wound area and from the conjunctival cavity for sowing, as mentioned above.

Microsurgery should be carried out under conditions of neuroleptanalgesia and complete akinesia (see "Basic principles of microsurgical interventions").

At present, no one doubts the fact that penetrating wounds of the cornea and sclera are subject to closure with sutures.

Only small corneal wounds up to 2 mm in size with well-adapted edges, without pinching of the iris in the wound, with preservation of the normal depth of the anterior chamber do not require surgical treatment. In these cases, it is recommended to use a fluorescein test to control the tightness of the anterior chamber - leakage of moisture from the anterior chamber in the wound area, sometimes after slight compression of the eyeball, indicates the need for surgical treatment.

There are statements that any corneal wound should be sutured, but, probably, a differentiated approach to solving this issue is still needed. We are of the opinion that an uncomplicated small corneal wound under the conditions mentioned above should be left for

spontaneous scarring: suturing can only cause additional trauma. But if a small corneal wound is combined with traumatic damage to the lens, the hydration of which may lead to hypertension, or in the same situation there is an intraocular foreign body that needs to be removed, then a suture should be placed on the edges of such a wound. "Radically" minded surgeons suggest suturing even non-penetrating but deep corneal flap wounds to prevent astigmatism, which is possible as a result of scarring of a wound not secured with sutures.

The suture method of closing wounds of the eyeball has its own history. Corneal and scleral sutures were proposed by Baretti and Dieffenbach in the first half of the last century.

However, even during the Great Patriotic War, it was generally accepted to cover wounds with a conjunctival flap. There was no complete and correct closure of the edges of the wound, often epithelium grew into the eye cavity and powerful adhesions formed from the scar area, leading to wrinkling of the eyeball. Only a tight connection of the edges of the corneal and scleral wound with deep sutures could eliminate such complications (E.F.Levkoeva, 1951).

At present, the question of whether to close the wound of the eyeball with sutures is not raised. This has long been decided. The problem has been transferred to another plane with the clarification of a number of still debatable elements, in particular, what the depth of the sutures should be, the distance between the sutures, the timing of the removal of the threads, etc.

Treatment of wounds of the eyeball is carried out under a microscope with magnification of 8-12, maximum 20 times.

In conditions of microsurgery, sutures on a corneal wound should be applied as deeply as possible, to Descemet's membrane, i.e. to 3D - Vs the thickness of the cornea (Fig. 122 a). With a more superficial application of the suture, the posterior parts of the wound are torn (Fig. 122 b), due to which a mooring is formed that extends into the cavity of the eye.

There are different opinions regarding through sutures. Opponents of such sutures claim that it is quite difficult to pierce Descemet's membrane with a microneedle without additional trauma, and that endothelium can grow along the suture, especially a monofilament; the possibility of invagination of the

external parts of the wound cannot be ruled out (Fig. 122 c).

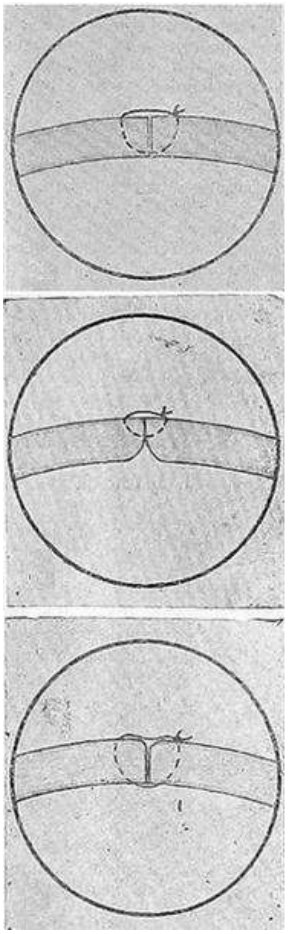

Fig. 122. **Scheme of suturing a corneal wound:**
(a) Deep suture (intrastromal placement); (b) Superficial suture (epithelial-anterior stromal); (c) Full-thickness suture (transcorneal)

Therefore, in principle, we do not exclude the option of penetrating corneal sutures. But this question, we repeat, is debatable, and, judging by the literature, most ophthalmic traumatologists are inclined to deep, but not penetrating corneal sutures.

The frequency of suturing a corneal wound depends on its nature: for linear wounds without edge displacement, sutures are applied every 1-1.5 mm; for large wounds, as well as curved wounds, the distance is reduced to 1 mm.

However, as our histological studies have shown, the main drawback of microsurgical technique (up to 30% of eyes removed in the first 6 months after injury) is the too superficial application of corneal sutures by surgeons—at ½ the thickness of the cornea.

This is probably due to the fact that in conditions of edema and infiltration of the edges of the corneal wound, it is difficult to assess the true thickness of the cornea. Poor adaptation of the internal parts of the brine is the cause of mooring (Fig. 123).

Wounds in the limbus area should not be closed with frequent sutures, since, by passing a suture through a thinned area of the sclera - in the area of Schlemm's canal, it is possible to cause tissue fraying and, accordingly, poor sealing of the cavity of the eyeball. The "step" of the suture – the distance between the needle puncture and the

edge of the wound – is also reduced in microsurgery conditions, compared to traditional options.



Fig. 123. **Formation of a suture from the posterior sections of the corneal wound channel with insufficient suture depth. Hematoxylin and eosin staining, x400**

In conditions of beveled wounds, the suture "step" on the side of the thinned flap increases to 2 mm or more, due to the need for deep needle insertion (Fig. 124).

In case of corneal wounds of irregular shape with the presence of angles, separate flaps, it is advisable to perform key sutures at the beginning, placing them in the places of bends of the wound channel. This will help to avoid displacement of the wound edges during subsequent suturing and, consequently, the appearance of astigmatism. It is also recommended to apply a key suture to the limbus in case of corneal wounds that extend to the sclera.

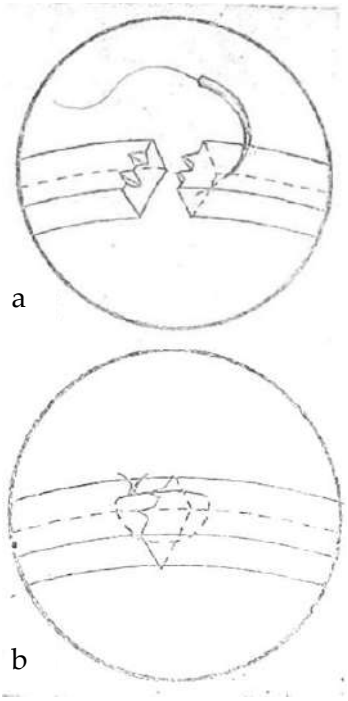

Fig. 124. **Scheme of suture application with different "step" sizes with a beveled corneal edge (a, b)**

After this first suture is placed, the corneal and then the scleral part of the wound is sutured (Fig. 125).

On star-shaped corneal wounds, as a rule, a through circu-

lar suture is applied first and equal to 1 mm or a purse-string suture, and then individual parts of the wound are sutured (Fig. 126).

When working with long and slightly curved needles, when passing them through ½-⅘ of the thickness of the cornea, it is necessary to make a large "step" of the suture, and this, in turn, can cause invagination of the outer edges of the wound.

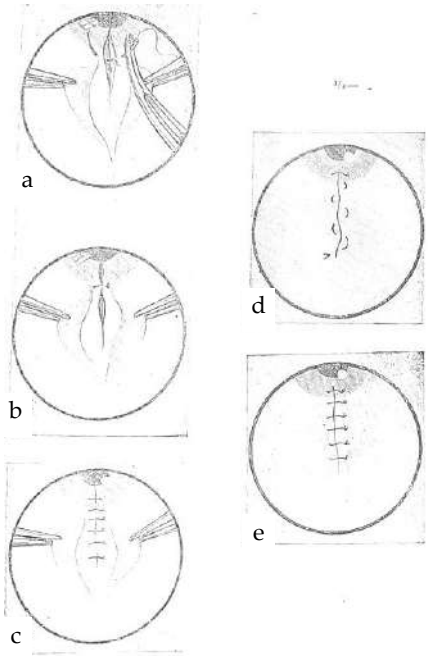

Fig. 125. **Stages of suturing a corneoscleral wound:**
(a, b) Key limbal suture placement; (c) Corneal and scleral wound suturing; (d, e) Conjunctival wound closure options: (d) Continuous running suture (e) Interrupted sutures

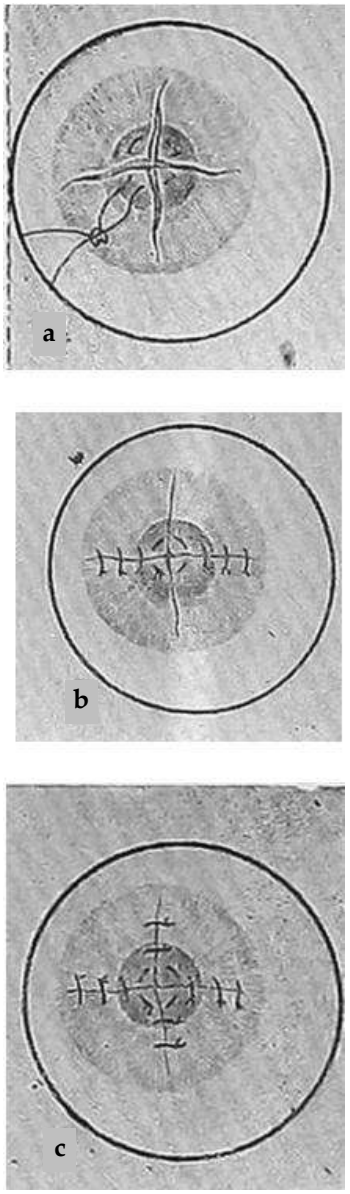

Fig. 126. **Technique for Repairing a Stellate Corneal Wound:**
a - Central purse-string suture;
b, c - Interrupted sutures placed on individual wound segments

There is no single guideline regarding the technique of passing the needle through both lips of the corneal wound. The optimal method is to pass the needle through one edge and, without leaving it, prick the other edge of the wound (Fig. 127), thereby eliminating the possibility of displacement of one wound edge relative to the other.

But this sometimes causes technical difficulties: the needle passes through the cornea with difficulty.

Separate passage of the needle in each lip of the wound is considered less traumatic. To fix the edges of the wound in microsurgery conditions, special corneal tweezers or Hoskin-type tweezers are recommended, which do not cause additional tissue damage when passing the needle through a very dense cornea. The question of which sutures are preferable to apply to the corneal wound - nodal or continuous - is also debatable.

It is known that interrupted sutures perform a dual function: they close the wound and correct the corneal deformation, while continuous sutures are only capable of sealing the eye cavity. Taking this into account, linear wounds with well-adapted (without displacement) edges can be closed with a continuous suture. It eliminates a large number of knots that cause a foreign body sensation and irritation of the eyelid tissue. However, for wounds of irregular shape, torn, with crushed edges, interrupted sutures are indicated. There are proposals to immerse the suture knot in brine, but from the point of view of scar formation, this procedure seems undesirable to us. It is possible to combine sutures - first apply nodal-adaptive sutures, and then continuous sutures. In case of extensive, irregularly shaped wounds, it is advisable to use guiding opposition sutures, which are removed after the end of surgical treatment. The choice of suture material is important in the microsurgery of penetrating wounds. Natural silk with a thread thickness of 25-50 microns is currently widely used.

This is confirmed by clinical observations and morphological studies, including our own. The reaction to synthetic threads from the tissues of the eye is minimal and is limited to only minor lymphocytic infiltration. Synthetic monofilament used to close corneal wounds is marked 8/0-10/0. A disadvantage of synthetic suture material is the irritating effect of the knot and the ends of the thread. To avoid this, after tying the knot, the

threads should be cut short and the knot should be melted with a thermal cautery.



Fig. 127. **Method of one-stage suturing of the edges of a corneal wound**

It is convenient for tying a knot, and the ends of the thread do not have an irritating effect. Virgin silk 8/0 is recognized by ophthalmic traumatologists; along with it, domestic Moldavian and Turkmen silks (15-60 microns) are increasingly used. Synthetic threads (supramid, nylon, ethyl) are also acceptable for corneal tissue.

The search for new suture materials for microsurgical operations has led to the creation of threads that have a number of advantages over existing ones. There are reports in the literature about absorbable suture material made of collagen with antimicrobial properties, which is especially valuable in cases of childhood trauma (P.I.Lebekhov, 1979). There is information about biologically inert domestic threads made of polyethylene.

When suturing a corneal wound and tying a knot, it is necessary to strictly calculate the degree of tension of the threads. In conditions of trauma against the background of edema and tissue infiltration, weak tension of the thread may subsequently lead to incomplete adaptation of the edges of the wound. However, as practice shows, too active tension of the sutures is more often observed. Subsequently, under these conditions, necrosis and sequestration of the corneal tissue occurs in the loop of the suture thread (A.A.Khorosanyan-Tade, L.K.Moshetova, 1977) (Fig. 128).

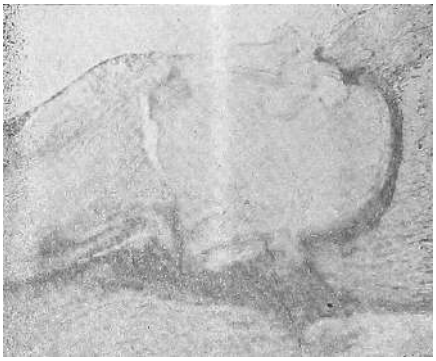

Fig. 128. **Corneal necrosis due to strong tension of suture threads. Hematoxylin and eosin staining**

The timing of removing corneal sutures is a subject of discussion and research by ophthalmic traumatologists, since this issue is complex, and its solution has several options. With traditional surgical treatment of corneal wounds with 4/0 silk, the sutures were removed after 2 weeks. Nowadays, micro-sutures last for 1-2 months and even half a year.

The absence of a pronounced clinical reaction to new suture materials allows them to be removed in conditions of a firmly formed corneal scar without fear of opening the anterior chamber. The technique for removing sutures is presented in the section "Basic principles of microsurgical interventions".

Special attention should be paid to the surgical treatment of corneal wounds with signs of infection. Modern broad-spectrum antibiotics have made it possible to reconsider the tactics for these types of damage in the conditions of microsurgery. We have become convinced that it is inappropriate to leave corneal wounds with signs of infection without surgical treatment.

The literature of recent years also recommends active measures: washing the wound and the anterior chamber with solutions of antibiotics of the semi-synthetic penicillin group, gentamicin, ceporin; their introduction into the vitreous body; early removal of the intraocular foreign body; suturing the corneal wound, but without fail, nodal, with an interval of 1.5-2 mm and moderate tension of the thread when tying the knot.

In addition to the suture method of adapting the edges of penetrating corneal wounds, in modern ophthalmology there is the possibility of closing them with glue - biological and cyanoacrylate.

The MK-6 glue, which is widely used in our country, has low toxicity and good adhesive and bactericidal properties. It is used to close small corneal wounds with good edge adaptation, located centrally. The adhesive method can be combined with wound closure with sutures. The glue is applied in the form of a thin film to the dried surface of the cornea and after 2-3 weeks (if there is no spontaneous rejection), it is removed.

One of the modern methods of closing penetrating corneal wounds is tectonic corneal transplantation. It is indicated in cases where there is a defect in the corneal tissue. Strengthening the transplant is possible with the help of microsutures or cyanoacrylate glues MK-6, SO-4, SO-6. In case of small puncture

wounds of the cornea, where a suture is impractical, it is also possible to use a soft contact lens.

Against the background of a large number of new and perfect methods of treating corneal wounds, the traditional version of conjunctival coating, presented in detail in the literature, has not lost its significance. As a rule, conjunctival coating is used in combination with corneal sutures in cases where a lacerated wound is localized in the limbus area. The application of sutures to the crushed tissues of the thinned area of Schlemm's canal does not provide adequate sealing, as has already been said. Therefore, here, as an addition, a conjunctival coating of a small area of the cornea is connected, promoting the formation of a strong scar (Fig. 129).

This method of wound closure should also be remembered from the standpoint that in the conditions of modern warfare, with combined injuries, the method of conjunctival covering can play a positive role (V.V.Volkov, 1979).

The task of surgical treatment for damage to the eyeball includes not only wound closure but also measures to prevent anterior synechiae. This is achieved to a certain extent by excision or reduction of the iris that has fallen into the wound.

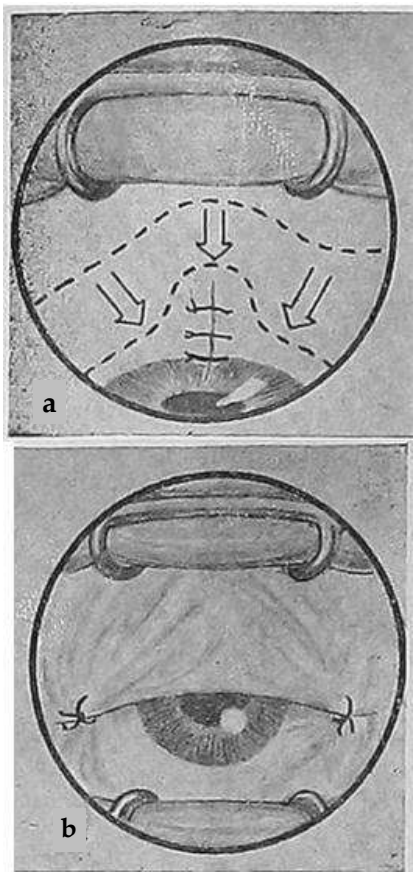

Fig. 129. **Stages of closure of a corneoscleral wound with sutures in combination with conjunctival covering:**
a - placement of interrupted sutures for corneoscleral wound closure following conjunctival flap elevation; b - securing of the conjunctival flap with multiple conjunctival sutures

The iris left in the wound, after 4-5 days, takes part in the formation of a rough corneal scar and the formation of anterior synechiae. Subsequently, the pupil takes on an

irregular shape, iridocyclitis and secondary glaucoma are possible.

For several decades, excision of the prolapsed iris was considered correct. Its reduction a day after the injury was considered unacceptable due to the risk of infection. However, in modern conditions of microsurgery, the use of broad-spectrum antibiotics and corticosteroids, as well as tactics regarding the iris have undergone changes.

Now they try to preserve the iris tissue as much as possible. The prolapsed iris is carefully separated from the edges of the corneal wound with a microspatula and, after irrigation with an antibiotic solution, immersed in the anterior chamber. Repositioning of the iris can also be done with a stream of saline solution from a blunt cannula. If the iris still has a tendency to pull itself toward the wound, corneal paracentesis is indicated, through which the iris is straightened.

As an exception, cyclodinalysis can be used for these purposes. In case of a rigid iris, a small iridotomy is performed, which facilitates better tissue repositioning. In cases of limbal wounds with prolapse of the iris into the wound, basal iridectomy is advisable.

In order for the repositioned iris to maintain its position and not be pulled toward the wound, sterile air or liquid should be introduced into the anterior chamber. It is quite clear that the introduction procedure itself is one of the methods for straightening the iris. Air and liquid also serve as a means of quality control in the surgical treatment of the corneal wound and determining the tightness of the anterior chamber. It is difficult to introduce air or liquid into the chamber through a sutured corneal wound, and it is unsafe with a transparent lens.

Therefore, it is best to perform this through an additional incision in the cornea, simultaneously straightening the iris with a staple needle and introducing fluid or air into the anterior chamber.

The question of what is more appropriate to fill the anterior chamber with is of some interest. A positive property of air is the high surface tension of the bubble, so it is indicated for extensive corneal wounds. At the same time, for wounds in the lower parts of the cornea, it is better to use liquid, since an air bubble with open eyes and a vertical position of the head, shifting upward, will, on the contrary, contribute to the formation of iridocorneal adhesions. The liquid in the anterior chamber, in addition, will allow a more accurate assess-

ment of its tightness: the brine after treatment should be impermeable not only to air but also to liquid.

Morphological studies of the cornea conducted by A.Apsitis (1979) also revealed the advantage of introducing liquid into the anterior chamber. The reaction of the corneal endothelium is least pronounced on medium - 199, it suffers somewhat more when a physiological solution is introduced into the anterior chamber.

A completely new direction in ophthalmic traumatology is the application of sutures to the damaged iris. This became possible only under the conditions of microsurgery. In the previous sections it was already mentioned that the tissue of the iris is capable of forming a scar.

The technique of applying sutures depends on the nature of the damage to the iris. In penetrating wounds, traumatic ruptures of the iris are preferably sutured through the corneal wound. But through small wounds such manipulation is difficult, therefore, if necessary, it is possible to increase access to the anterior chamber by additional extension of the corneal wound.

In contusions complicated by iridodialysis, tear of the pupillary edge, or traumatic mydriasis, surgical intervention on the iris must be prolonged in time, since early surgery can aggravate the course of the flap-contusion process. Technically, the approach to the damaged iris in these cases is carried out, as a rule, through a corneoscleral incision with a conjunctival flap, or through a corneal incision. It should be noted that now domestic and foreign authors offer original methods of iridoplasty without opening the anterior chamber.

For a rupture of the iris from the pupillary edge to the root, it is enough to apply 3-4 sutures; in iridoplasty of a peripheral rupture, the distance between the sutures is maintained at about 3 mm.

In the case of traumatic mydriasis, a purse-string suture can be used, which allows the formation of a round pupil of the required size (Fig. 130). In cases where the damage to the iris concerns one segment (tears of the pupillary edge, rupture of the pupillary sphincter in combination with several small tears), we use a double half-purse-string suture (Fig. 131). The thread is passed at the required distance, first in one direction, then in the opposite direction, after which a knot is tied. Unlike the half-purse-string with one thread, this option is simple in technical execution, the tension of the thread is easy to dose. Our clinical obser-

vations allow us to recommend it as one of the methods of suturing defects of the iris.

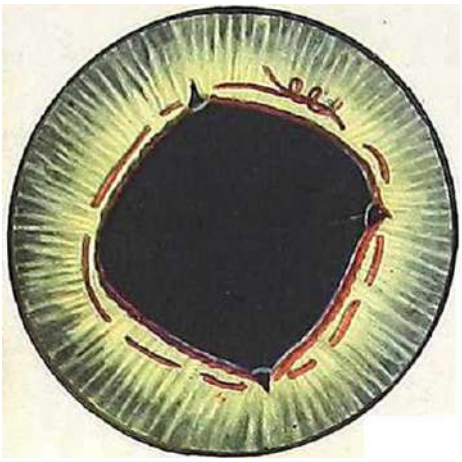

Fig. 130. **Scheme of application of a purse-string suture to the pupillary edge of the iris**

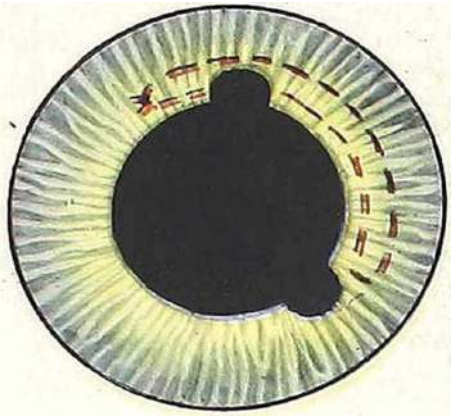

Fig. 131. **Double Purse-String Pupilloplasty Technique**

As a suture material for iridoplasty, the most suitable are synthetic threads (supramid, nylon) with a thickness of 25 microns (10/0). The clinical and morphological reaction of the iris tissue to monofilament, in comparison with biological and even silk threads, is minimal.

Small needles of 4-5 mm are used, preferably atraumatic ones. They should be fixed with a needle holder without a lock, with a small width of working jaws (about 0.75 mm).

However, we prefer flat-branched tweezers for these purposes. Of the micro-instruments, iris tweezers and micro-scissors for cutting the threads are also necessary, since a razor blade is of little use here.

The microscope magnification should be 8-12 times.

When applying the suture, one edge of the iris is fixed with the hummingbird tweezers, and the needle is carefully inserted into it "in the air". After this, the other edge is also stitched separately. When stitching both lips of the wound at the same time, the iris may be injured. The iris tissue should be maximally spared and used rationally - the suture step should be 0.3-0.5 mm. The suture knot can be tied on both the front and back surfaces of the iris, taking this into account, the first needle prick should be made either from

the surface of the iris inward, or vice versa - from the inside outward (Fig. 132).

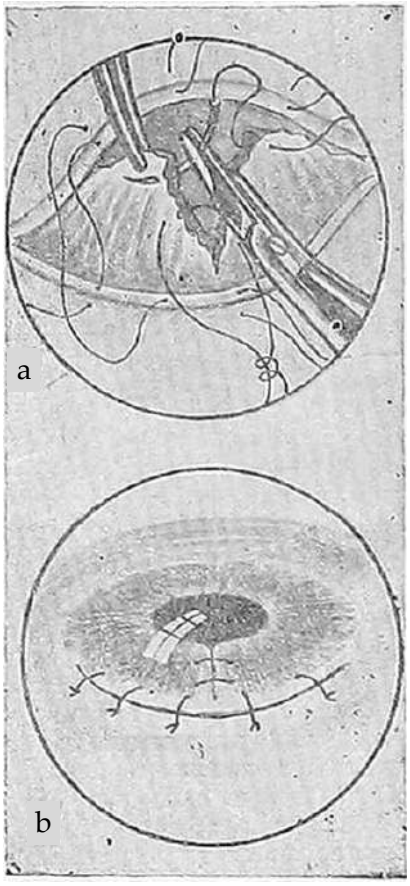

Fig. 132. **Options for suturing a wound in the iris**
a – suture knot on the anterior surface of the iris; b – suture knot on the posterior surface of the iris

The location of the suture knot on the back surface of the iris is suggested to prevent damage to the corneal endothelium, but at the same time, the knot does not exclude injury to the lens. Therefore, the issue should be resolved individually, taking into account the location of the knot (pupillary edge or root zone), the presence of a transparent lens, etc. In any case, the knot should be tightly tied with at least two double overlaps of the thread in opposite directions, and the ends of the thread are cut short, or even better, melted with a thermal cautery.

Such an active and at the same time gentle approach to damage to the iris, both in case of penetrating wounds and in case of contusion, allows at the level of microsurgery to obtain not only the restoration of correct anatomical relationships in the anterior part of the eyeball, but also to achieve a certain cosmetic effect and higher functional outcomes.

Penetrating wounds of the sclera, as well as rupture of the sclera in case of contusion, are subject to mandatory surgical treatment, since the tissue of the sclera, unlike the cornea, is not prone to edema, and in case of damage, the hole in the sclera, as a rule, gapes. The most common method of closing wounds of the sclera, which has proven itself everywhere, is the imposition of sutures. By analogy with surgical treatment of wounds of the cornea, the scleral wound

should also be treated under a microscope at a magnification of 8-12 times, using microinstruments. Needles for the sclera can be taken less curved than for the cornea ¼ - ⅜ of the circumference length and longer 5 - 7 mm, cutting. Both atraumatic and microneedles with a reusable eye are suitable here. Suture material: natural silk, including 8/0 virgin; monofilament, especially supramid 8-10/0; biological threads; however, in case of vitreous body prolapse, biosutures are ineffective due to weak knot tying.

Sutures on the scleral wound are always applied through its entire thickness (Fig. 133). The needle can be inserted simultaneously through both edges of the wound or sequentially - first through one, then through the other. For small wounds, the latter option is not very acceptable. When applying sutures, it is necessary to ensure that the needle does not pass through the underlying tissue of the vascular membrane. We observed similar technical errors during the morphological examination of the eyes.

In the clinic, this situation, if the sutures were placed at the level of the ciliary body, was manifested by severe pain syndrome and prolonged cyclitis.

The suture "step" when treating scleral wounds is 1 mm, the distance between the sutures is 1-2 mm. The sutures should not be too tight and placed too close together in order not to cause tissue necrosis, as mentioned above. Scleral sutures in microsurgery are usually not removed and remain under the conjunctiva; the element of cutting of synthetic threads is minimal.

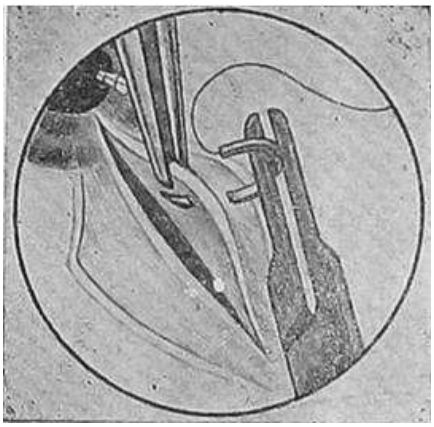

Fig. 133. **Application of through sutures on the scleral wound**

In case of extensive scleral wounds partially covered by the conjunctiva, the entire frame should not be exposed entirely, but treated sequentially, thereby preventing the loss of the inner membranes of the eye. Most often, such a clinical variant is encountered in severe contusions of the eyeball.

As in cases of corneal wounds, small scleral damage can be treated

with cyanoacrylate adhesives. In severe scleral wounds with a through tissue defect, tectonic plastic surgery is indicated, which can be performed with homosclera dried on silica gel or alloplastic materials (Fig. 134). To fix scleral or lavsan transplants, sutures are traditionally used, strengthening them in the episclera, using adhesives (cyanoacrylate adhesives MK-6, SO-4, SO-6), or both methods are combined.

The transplant flap strengthened in the area of the scleral defect not only plays a tectonic role but also promotes the formation of a stronger scar and prevents intraocular infection.

The vascular membrane that has fallen into the scleral wound, while maintaining tissue viability, should be irrigated with an antibiotic solution and carefully repositioned with a spatula.

Crushed membranes, as well as tissues with signs of infection, should be cut off. Z.M.Aliyeva (1979) proposes a more advanced method of excision of damaged tissues of the ciliary body with preliminary microcoagulation of the vessels, which is possible only at the modern microsurgical level.

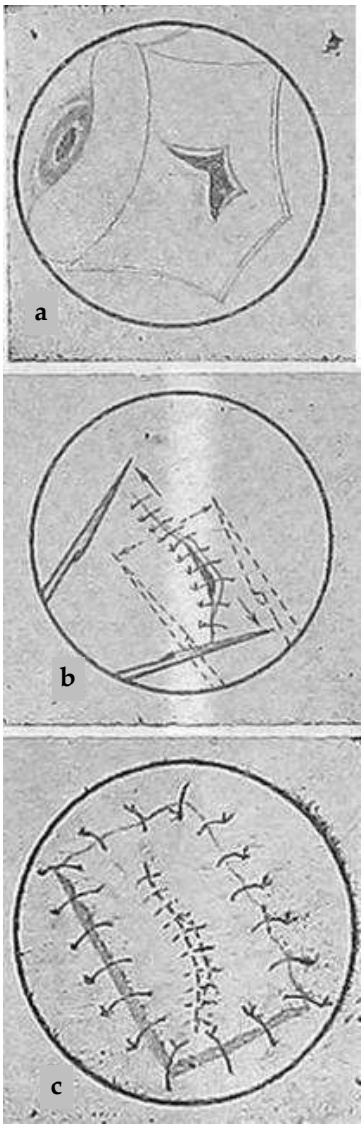

Fig. 134. **Scheme of tectonic plastic surgery of the scleral wound:**
a—scleral wound with tissue defect; b—guiding sutures on the scleral wound, determining the size of the transplant with a caliper; c—covering the wound with a scleral flap and strengthening it with sutures

If the vitreous falls into the scleral wound, it is excised, and in the case of deep hypotension, it is replaced with a physiological solution, cadaveric vitreous, balanced solutions, etc.

At the same time, it is advisable to introduce antibiotics and dexazone into the eye cavity, as was discussed in the section on conservative treatment of trauma.

One of the critical moments of surgical treatment of penetrating wounds of the eyeball, and sometimes contusion damage, is the elimination of harmful effects from the lens. The extent of intervention on the lens depends on the degree of its damage. In cases where the injury is accompanied by a breach of the integrity of the lens capsule and the prolapse of lens masses into the anterior chamber, their removal by washing or aspiration should be performed immediately during surgical treatment of the wound. This will eliminate an undesirable toxic-allergic reaction of the eye tissues to the lens substance in the future.

The damaged lens is also subject to removal during wound treatment if there is absolute certainty that its substance will swell in the near future, which will require repeated surgical intervention literally in 2-3 days.

Removal of the lens masses is performed either through the wound, if its size allows, or through a cataract-type incision in the corneoscleral zone.

Interventions on the lens should be avoided if its capsule appears intact or the opacity is small and local. Minor damage to the capsule should be covered with the iris, the pigment sheet of which creates a kind of biological patch and will prevent the penetration of moisture from the anterior chamber into the lens; for this, the instillation of miotics is necessary.

As has already been described in the previous sections, it is necessary to remove the lens that has been luxated into the anterior chamber due to contusion. This is not always easy, especially if the lens has not completely moved into the anterior chamber. In these cases, it is necessary to choose the optimal area for opening the anterior chamber and approaching the lens, taking into account its position in the horizontal position of the patient's head. If the lens located in the anterior chamber is being removed, it is necessary to achieve a maximum reduction in intraocular

pressure before the operation, and in conditions of miosis, the incision in the corneoscleral zone should be made very slowly.

In foreign literature there is information about the necessity of removing the lens at the time of surgical treatment in any case, if there is even a slight cataract, with simultaneous implantation of an intraocular lens. However, we believe that a differentiated approach has undoubted advantages, as it protects the eye from additional and not always justified trauma.

The entire history of ophthalmic traumatology shows that one of the most difficult issues is the problem of removing intraocular foreign bodies.

The variety of physical properties of fragments, their localization, and their relationships with eye tissues create certain difficulties in choosing methods for their removal. The key to success is perfect clinical diagnostics and precise localization of the foreign body using all modern research methods specified in the section on penetrating wounds of the eyeball.

We believe it is possible not to dwell on models of magnets for removing foreign bodies from the eye, the use of special amagnetic instruments, or some details of complex surgical techniques, but to pay primary attention to the issues of tactical approaches to intraocular foreign bodies, which are solved by ophthalmologists on the spot - in regional and city hospitals, often without having a second specialist nearby for advice and assistance. We want to warn doctors against unfounded, independent, without sufficient experience, attempts to remove "complex" foreign bodies and at the same time call for active tactics in those cases where it is absolutely indicated and can be performed.

It is known that early removal of an intraocular foreign body is a preventive measure for many complications of the post-traumatic period. It is considered indisputable that the removal of magnetic intraocular foreign bodies is mandatory during surgical treatment of the wound, with the exception of those that are located in a hard-to-reach location. In the latter case, it is advisable to refrain from attempting to remove the foreign body, since the degree of risk of loss of vision and the eye is high, and the probability of success is minimal. There

are methodological recommendations on this matter from the Moscow Helmholtz Research Institute of Eye Diseases. There is no need to rush to remove a magnetic fragment from the eye located in the membranes or even parietal at the posterior pole of the eye, especially, in the macular and paramacular zones. We consider attempts to remove these foreign bodies at night, during duty, sometimes without having a precise localization, simply unreasonable. In the conditions of a technically equipped hospital after a detailed examination, the guarantee of success is much higher.

The issue of magnetic foreign bodies in a transparent lens is resolved in the same way. There are clinical observations indicating that a foreign body in the lens may not cause clinical symptoms of siderosis for many years and not contribute to lens opacity.

Meanwhile, the removal of the fragment can lead to traumatic cataracts. Great care should also be taken with foreign bodies, even magnetic ones, in a single eye and with multiple foreign bodies - they should be removed by experienced surgeons in a technically equipped hospital.

All other magnetic foreign bodies should be attempted to be removed from the eye in the first hours after the injury. The number of successful outcomes of magnetic operations now exceeds 95%.

The issue with a magnetic fragment located in the vitreous body is technically simple - removal with a magnet is carried out through the area of the flat part of the ciliary body (Fig. 135 a).

Foreign bodies located parietal in the posterior part of the eyeball, in an accessible location, are removed by most surgeons at their location by the diascleral route (Fig. 135 a).

To remove foreign bodies of a magnetic nature located near the membranes of the posterior pole or wedged in the membranes, one can try to extract the fragment in two stages (first transferring it to the dentate line of the retina with a powerful magnet, and then extracting it by the diascleral route) (Fig. 135 b). There is also a transvitreal approach (Fig. 135 c). V.V.Volkov (1980) considers this last option to be the most gentle, although technically more complex, requiring special equipment.

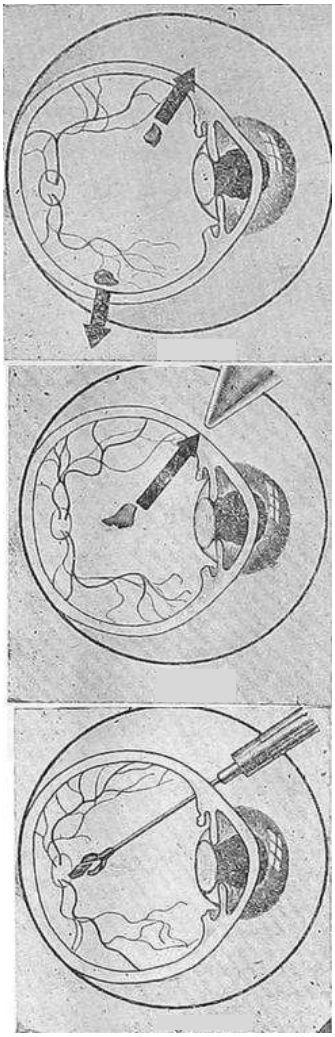

Fig. 135. **Scheme of removal of intraocular magnetic foreign bodies:**
a – from the vitreous body through the pars plana of the ciliary body (pars plana approach), located near the wall - via the transscleral route at the site of impaction;
b, c – for foreign bodies adjacent to the membranes at the posterior pole or embedded within them - removal through the pars plana of the ciliary body or via a transvitreal approach

If the surgical intervention was traumatic, the removal of the fragment was accompanied by prolapse of the vitreous body, hypotension, then as a preventive measure for retinal detachment, including in our clinical practice, scleral buckling is used. It can be carried out in several ways - in a pocket, i.e. intrasclerally, or by strengthening the buckle with U-shaped sutures episclerally (Fig. 136).

Homosclera or various silicone rubbers are used as a buckle. Scleral buckling is also indicated where retinal detachment was determined ophthalmoscopically or echographically before the removal of the foreign body from the eye.

Magnetic foreign bodies of the anterior chamber are relatively easy to remove. This is done directly through the corneal wound or by a special limbal approach simultaneously with surgical treatment of the wound (Fig. 137a). We remind you that we are talking about "fresh" cases, and not about foreign bodies that have been in the eye for a long time.

There are numerous publications on foreign bodies of the lens.

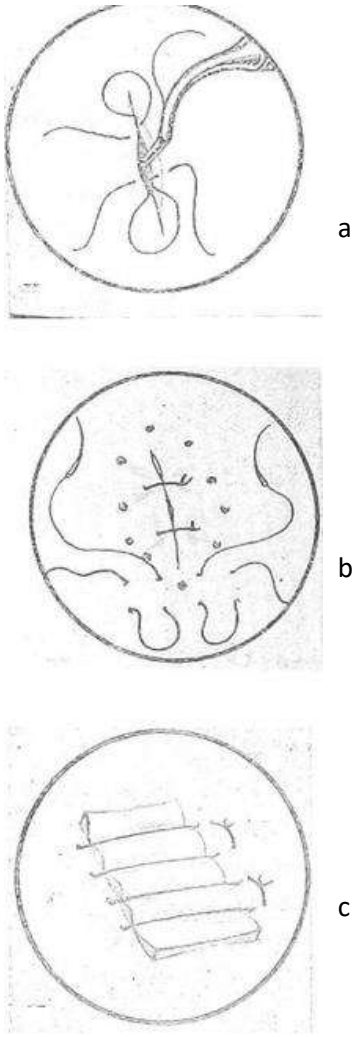

Fig. 136. **Scheme for preventing retinal detachment during diascleral removal of a foreign body:**
a – removal of the foreign body through a scleral incision with preliminary placement of scleral sutures; b – placement of U-shaped episcleral sutures to reinforce the buckle, along with scleral diathermy; c – placement of a buckling implant at the site of foreign body removal

They describe methods for removing magnetic foreign bodies: simultaneously with the cloudy lens, through the entrance opening of the capsule - the anterior route (Fig. 137b), by transferring the fragment into the anterior chamber with subsequent removal from it, as well as the posterior diascleral route.

In our practice, we often use the following method: the approach to the lens is similar to the cataract, the iris is pulled back with a retractor or tweezers, the magnet is brought to the intended exit site of the foreign body (often this is the entrance hole in the capsule).

After the foreign body has been removed, the anterior chamber is sealed with sutures, and miosis is created for 2-3 days. It is best to remove the foreign body from the lens at approximately x/3 of the distance from its equator to the anterior pole since it is here that the iris is tightly adjacent to the surface of the lens and can perform its tectonic function (Fig. 137 c).

Foreign bodies, even magnetic ones, localized in the posterior chamber are difficult to remove. We consider the most acceptable approach to the fragment to be through the iridotomy opening or the coloboma near the iris (Fig. 137 d).

After the foreign body has been removed, the iris can be sutured or stitched to the coriosclera zone (Fig. 138).

Amagnetic intraocular foreign bodies present the greatest clinical challenges, especially in terms of their removal. The guidelines we referred to above suggest a wait-and-see approach if nonmagnetic foreign bodies are in the transparent or translucent lens, in the vitreous body, and in the membranes of the posterior pole of the eye.

Since surgery for amagnetic foreign bodies is mainly performed by individual trauma centers, equipped with fiber optics, special tweezers for capturing foreign bodies of various shapes (vitreophages, phacoemulsifiers, etc.), we will allow ourselves to reduce the presentation of this issue to a minimum.

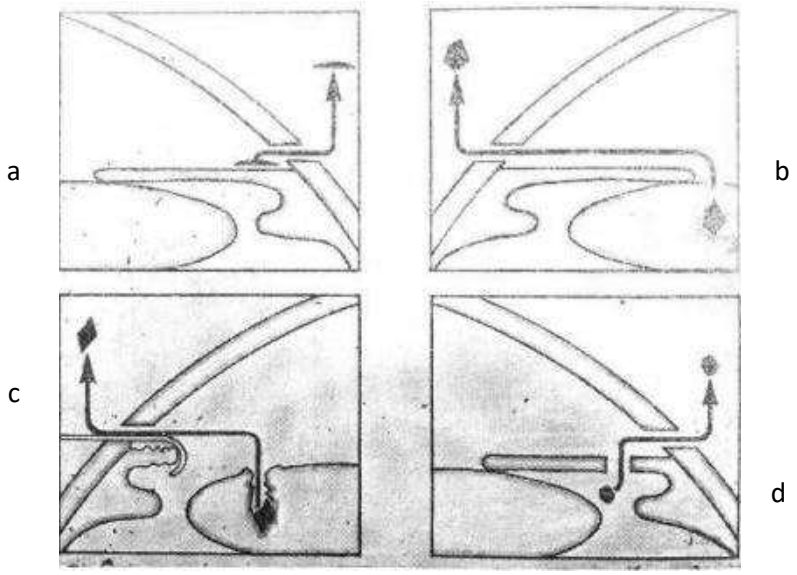

Fig. 137. **Scheme for removing a magnetic foreign body**
a – from the anterior chamber; b – from the lens through the entry hole in the capsule; c – from the lens through the pre-equatorial zone (with iris retraction); d – from the posterior chamber through a basal iris coloboma

Amagnetic foreign bodies are removed from the anterior chamber (its angle) for certain indications: chemical activity of the fragment, corneal dystrophy, recurrent iridocyclitis, or hyphema. Among the numerous methods, the simplest one seems to us to be the op-

tion of removing the foreign body through an incision in the outer part of the limbus, which is performed with preliminary separation of the conjunctival flap. In order to clearly define the peripheral border of the angle of the anterior chamber, transcorneal diaphanoscopic illumination is performed (Fig. 139) and the incision zone is marked with a blade.

The limbal incision is made carefully, under a 20x microscope magnification, gradually penetrating into the tissue. It is best to enter the anterior chamber near the foreign body, which often inserts itself into the incision. Rough manipulations, abrupt opening of the anterior chamber, and searching for a foreign body with tweezers are unacceptable. Of course, it is necessary to clearly determine the location of the foreign body in advance, perform gonioscopy, ultrasound echography, and outline a plan of action. The anterior chamber is sealed with 1-2 corneoscleral sutures.

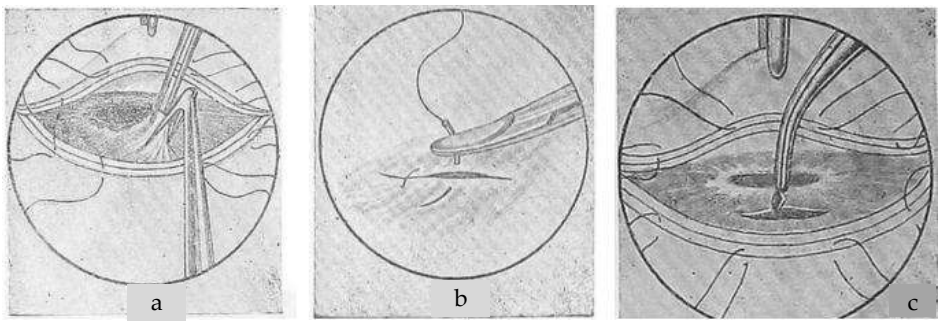

Fig. 138. **Scheme of removal of a foreign body through an iridotomy opening:**
a – iridotomy corresponding to the location of the foreign body;
b – removal of the foreign body with magnet **or forceps;**
c – sutures on the iris incision

Amagnetic foreign bodies in the lens are removed simultaneously with the removal of the cataract-altered lens.

Special instruments have been developed to fix foreign bodies located in the vitreous body or in the membranes at the posterior pole, and the removal of foreign bodies is carried out either through the flat part of the ciliary body or by an "open sky" operation - through the limbal approach and the pupil. The modern development of microsurgery has made it possible to achieve certain successes in one of

the difficult clinical situations of removing intraocular amagnetic foreign bodies. Amagnetic foreign bodies are now removed in more than 75% of cases.

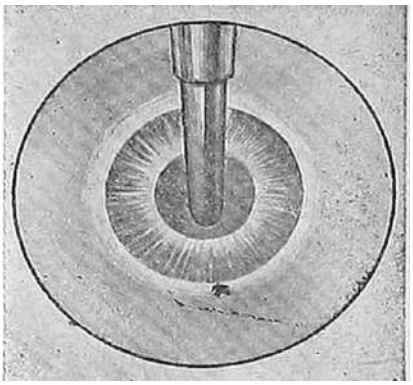

Fig. 139. **Diaphanoscopy to determine the projection of the anterior chamber angle and the localization of a foreign body**

Recently, guidelines for penetrating wounds of the eyeball have been revised. The entry wound in this type of injury is subject to surgical treatment according to the general rules for penetrating wounds of the eyeball. Discussions in the literature concern mainly the exit wound. If it is located in an accessible area, the sclera should be sutured through and the entire scope of microsurgical measures should be performed. When the outlet is located under the rectus muscle, wound treatment is usually performed by cutting off and then suturing the muscle.

The previous guidelines that the scleral exit opening at the posterior pole need not be treated due to major technical difficulties and, accordingly, additional trauma, are no longer recognized.

Almost any wound should be sutured, with the exception of distant microperforations, the issue of which should be decided individually in each clinical case. In the case of a particularly severe type of injury - crushing or destruction of the eyeball - surgical treatment is limited to primary enucleation. However, in order to decide on this important step, the ophthalmologist must be absolutely sure that he is dealing with the true destruction of the eyeball.

Enucleation should be performed only by an ophthalmologist, remembering that it is necessary to remove all tissue from the eyeball. The practice of evisceration in cases of uninfected destruction of the eyeball, which still exists in some institutions, is in no way permissible, as it is dangerous in terms of sympathetic inflammation.

In all other cases of severe penetrating wounds of the eyeball and severe contusions with rupture of the sclera, primary enucleation cannot be performed. It should be

avoided even when the eye appears to be absolutely hopeless in both visual and cosmetic terms. There are two reasons for this. Firstly, the patient is not convinced that everything has been done to save the eye, and has the right to later make claims to the surgeon, and secondly, anatomical reconstructive operations sometimes allow not only to save the eyeball but also to obtain normal vision.

Preventive enucleation according to well-known guidelines is carried out in the first two weeks after the injury.

In the conditions of modern microsurgery, which is reconstructive in nature, with the active use of corticosteroids and broad-spectrum antibiotics, the tactics of ophthalmologists regarding enucleation in the post-traumatic period should be somewhat revised. Based on the literature data, as well as our morphological studies, it seems necessary to propose more stringent and limited indications for early enucleation. The eye subject to removal is a blind, hypotonic eye with subatrophy and iridocyclitis with a penetrating wound, which does not have positive dynamics of the process from intensive desensitizing, anti-inflammatory and resorption therapy.

REFERENCES

Aliyeva Z.A. Acute viral conjunctivitis (a training manual for ophthalmologists). Baku: "Azerneshr", 1979.

Aliyeva Z.A. Differential diagnostics between viral conjunctivitis and conjunctivitis of professional ethnology. In the book: “Proceedings of the V All-Union Congress of Ophthalmologists”. Moscow, 1979, v. 4, p. 91.

Aliyeva Z.A. Herpetic eye disease (a training manual for ophthalmologists). Baku: "Azerneshr", 1979.

Aliyeva Z.A. Occupational diseases of the visual organ in chemical production conditions and measures for their prevention. In the book: “Materials of the VII Plenum of the Board of the All-Union Scientific Society of Ophthalmologists”. Baku, 1977, pp. 35-40.

Aliyeva Z.A. On the moral character of a doctor. “Vestnik oftalmologii” (“Herald of Ophthalmology”), 1980, No. 5, pp. 3-7.

Aliyeva Z.A. Prevention of eye damage in workers of the iodine industry. Methodological recommendations. Baku, 1976.

Aliyeva Z.A. Prevention of eye damage in workers of the rubber industry. Methodological recommendations. Baku, 1976.

Aliyeva Z.A., Shulpina N.B. Anatomical and physiological characteristics of the hydrodynamic system of the eye. Baku: "Azerneshr", 1980, 37 p.

Aliyeva Z.M. Comparative evaluation of microsurgical and conventional treatment and functional outcomes of penetrating wounds of the ciliary region. Abstract of PhD diss. Moscow, 1979.

Butyukova V.A. Peacetime eye socket injuries. Abstract of doctoral diss. Moscow, 1977.

Clinic, treatment and prevention of sympathetic ophthalmia. Methodical recommendations. M., 1975.

Diagnostic and therapeutic use of antiherpetic polyvaccine in patients with ophthalmic herpes. Methodical recommendations. M., 1980.

Diagnostics and surgical treatment of primary retinal detachments. Methodical recommendations. M., 1975.

Duke-Elder S. System of ophthalmology. V. 14, p. 1, London, 1972, 743 p.

Fedorov S.I. Implantation of an artificial lens. M.: “Medicine”, 1977, 207 p.

Gorban A.I., Dzhaliashvili O.L. Microsurgery of the eye. Manual for doctors "Medicine", Leningrad. department. 1982, 218 p.

Guidorova R.A., Petropavlovskaya G.A. Penetrating wounds and contusions of the eye. Moscow: "Medicine", 1975, 310 p.

Hailk G.D., Coles V.H., Fctridge E.D. Intraocular Injuries. Philadelphia, 1972, 133 p.

Herpetic disease (clinic, diagnostics, treatment). Methodical recommendations. M., 1975.

Khorosanyan-Tade A.A., Daoshetova L.K. Clinical and morphological studies of penetrating eye wounds. In the book: "Problems of Clinical Ophthalmology". Alma-Ata, 1977, pp. 83-85.

Khorosanyan-Tade A.A., Daoshstova L.K., Perlamutrova V.V., Neskreba E.F. Clinical and morphological analysis of penetrating wounds of the eyeball. In the book: "Proceedings of the V All-Union Congress of Ophthalmologists". M., 1979, v. 5, pp. 35–37.

King I.H., Wadsworth A.G. An Atlas of ophthalmic surgery. Philadelphia and Toronto, 1970, 631 p.

Krasnov M.L. Microsurgery of glaucoma. M.: "Medicine", 1980, 245 p.

Krasnov M.M. Laser goniopuncture in glaucoma. American Journal of Ophthalmology, 1974, Vol. 78, pp. 186-192.

Krasnov M.M. Laser Microsurgery of the eye. M.: "Medicine", 1979, 256 p.

Krasnov M.M. Microsurgery of the eye. M.: "Medicine", 1974, 328 p. (with ill.)

Lean I.D. Atlas of glaucoma. Saint Louis, 1967, 125 p.

Lebekhov P.I. Penetrating eye wounds. L.: "Medicine", 1975, 207 p.

Levkoeva E.F. Wound process in the eye. M.: "Medgiz", 1951, 152 p.

Malayev A.A. New methods in the system of complex diagnostics and surgical treatment of penetrating wounds of the eyeball with the introduction of foreign bodies. Abstract of doctor. diss., M., 1979.

Maychuk Yu.F. "Viral eye diseases". M.: "Medicine", 1981, 272 p.

Microsurgery of the eye (collected works). Edited by Academician of the USSR Academy of Medical Sciences, prof. M.L.Krasnov. Moscow, The First Moscow Order of Lenin and the Red Banner of Labor Medical Institute named after I.M.Sechenov, 1979, 151 p.

Microsurgery of the Eye: Collected research papers / Ed. by M.M.Krasnov. Moscow, 1976, 264 p.

Moshetova L.K. Some aspects of microsurgical treatment of penetrating wounds of the eyeball. In the book: "New in diagnostics and treatment of penetrating injuries of the organ of vision". Saratov, 1977, pp. 81-84.

New methods of diagnostics and treatment of penetrating wounds of the eyeball with the introduction of foreign bodies. Methodical recommendations. Moscow, 1978.

Order of the Ministry of Health of the USSR No. 145 of 11.02.1975 "On measures for the further development of surgical care for eye diseases."

Polyak B.L. Damage to the organ of vision. M.: "Medicine", 1972, 415 p.

Puckovskaya N.A., Guidorova R.A., Volkov V.V. Prevention of severe outcomes in injuries to the visual organ. In the book: "Proceedings of the V All-Union Congress of Ophthalmologists". Moscow, 1979, v. 5, pp. 3-12.

Reconstructive ophthalmic surgery (collected works). Edited by Academician M.L.Krasnov, M.: The First Moscow Order of Lenin and the Red Banner of Labor Medical Institute named after I.M.Sechenov, 1979, 176 p.

Shilyaev V.G. Work of mid-level medical personnel of eye departments of hospitals and clinics. L.: "Medicine", 1979, 206 p.

Shulpina I.B. "Viral eye diseases" (Training manual). M., Russian Medical Academy of Continuous Professional Education, 1968.

Shulpina N.B. Biomicroscopy of the eye. M.: "Medicine", 1974, 264 p.

Shulpina N.B., Gudova I.V., Neskreba E.F., Khorosanyan-Tade A.A. Experience in treating phacogenic glaucoma caused by maturation of senile cataract. In the book: "Proceedings of the 1st Congress of Ophthalmologists of the Transcaucasian Republics". Tbilisi, 1976, pp. 95–97.

Shulpina N.B., Khorosanyan-Tade A.A., Neskreba E.F., Gudova I.V. Clinical and morphological characteristics of phacogenic glaucoma caused by the peculiarities of maturation of senile cataract. "Vestnik oftalmologii" ("Herald of Ophthalmology"). 1979, V. 1, pp. 9-13.

Shulpina N.B., Neskreba E.F., Gudova I.V. Immediate and remote outcomes of cataract extraction in phacolytic glaucoma. "Vestnik oftalmologii" ("Herald of Ophthalmology"), 1978, No 5, pp. 18-20.

Shulpina N.B., Perlamutrova A.V., Verdoyan S.A. Accelerated method of preoperative treatment of the surgeon's hands in ophthalmology. "Vestnik oftalmologii" ("Herald of Ophthalmology"), 1977, No 4, pp. 69-70.

Shulpina N.B., Perlamutrova V.V., Shif L.V., Moshetova L.K. Traumatic injuries of the organ of vision and prevention of infection in the emergency care system of the Moscow Ophthalmological Clinical Hospital. In the

book: "New in diagnostics and treatment of penetrating injuries of the organ of vision". Saratov, 1977, pp. 109-111.

Troutman Richard C.A. Microsurgery of the anterior segment of the eye. Saint Louis, 1974, 324 p.

Vilshaisky E.P. Some issues of improving the organization of traumatological eye care for the population of the USSR. In the book: "Materials of the V All-Union Congress of Ophthalmologists". Moscow, 1979, v. 1, pp. 23-25.

Volkov V.V. Transvitreal approach in the extraction of foreign bodies. “Vestnik oftalmologii” (“Herald of Ophthalmology”), 1980, No. 4, pp. 52-57.

Volkov V.V., Shilyayev V.G. On the successes of Soviet military ophthalmology. “Vestnik oftalmologii” (“Herald of Ophthalmology”), 1979, No. 2, pp. 3-5.

Weinstein E.S. Fundamentals of X-ray diagnostics in ophthalmology - M.: Medicine, 1967, 224 p.

Contents

Ophthalmology on the scientific meridians of the world
Foreword 5
From the author 8
Section I
Moral education of the doctor, issues of deontology, medical ethics and morality (Prof. Z.A.Aliyeva) 10
Section II
Modern aspects of biomicroscopy of the eye (Prof. N.B.Shulpina) 16
Chapter 1. Equipment. Working skills. Types of lighting 17
Chapter 2. Methodology of biomicroscopy of the membranes and optical media of the eye 39
Chapter 3. Clinical significance of cataract biomicroscopy 60
Chapter 4. Elements of biomicrovitreoscopy and ophthalmoscopy 80
Section III
Fundamentals of ophthalmological virology (Prof. Z.A.Aliyeva, Prof. N.B.Shulpina) 99
Chapter 1. Acute viral conjunctivitis 100
Chapter 2. Herpetic eye disease 115
Section IV
Damage to the organ of vision (Assoc. Prof. L.K.Moshetova, Prof. Z.A.Aliyeva) 136
Chapter 1. Penetrating injuries of the eyeball (Assoc. Prof. L.K.Moshetova) 137
Chapter 2. Eye contusions (Assoc. Prof. L.K.Moshetova) 149
Chapter 3. Complications of the wound process and contusion of the eyeball (Assoc. Prof. L.K.Moshetova) 160
Chapter 4. Emergency care and treatment for mechanical injuries of the eyeball (Assoc. Prof. L.K.Moshetova) 179
Chapter 5. Toxic-chemical damage to the organ of vision in tire production (Prof. Z.A.Aliyeva) 190
Chapter 6. Toxic-chemical damage to the organ of vision in iodine production (Prof. Z.A.Aliyeva) 215

Section V

Propaedeutics of eye microsurgery
(Prof. Z.A.Aliyeva, Prof. N.B.Shulpina, Assoc. Prof. L.K.Moshetova) 244
Chapter 1. Modern installations for equipment and exploitation of a microsurgical operating unit (Prof. N.B.Shulpina) 249
Chapter 2. Basic principles of microsurgical interventions (Prof. N.B.Shulpina) 281
Chapter 3. Morphological basis of microsurgical interventions on hydrodynamic structures of the eye (Prof. N.B.Shulpina, Prof. Z.A.Aliyeva) 315
Chapter 4. Biomicrogonioscopy in the choice, implementation and evaluation of pathogenetically oriented microsurgical operations in primary glaucomas (Prof. N.B.Shulpina) 341
Chapter 5. Microsurgery of penetrating wounds and contusions of the eyeball (Assoc. Prof. L.K.Moshetova) 365
REFERENCES 391

Translated from the book «Актуальные проблемы офтальмологии. — Б.: «Азернешр», 1983, 343 с.»

Technical Staff:
Assoc. Prof. Hijran Namazova
Minakhanim Aliyeva
Assoc. Prof. Afig Mammadov
PhD Aytan Aghayeva



Publisher: *PhD Sabuhi Gahramanov*
Computer design: *Ravana Ilmangizi*
Artistic design: *Shalale Mammad*

Paper size 70x100 1/16
Volume 25
Circulation

"Elm" Publishing House
(28 Istiglaliyyat Str., AZ 1001, Baku, Azerbaijan)